

USMLE STEP 2

RECALL

SECOND EDITION

Michael W. Ryan



Wolters Kluwer
Health

Lippincott
Williams & Wilkins

USMLE STEP 2 RECALL

Second Edition

RECALL SERIES EDITOR

Lorne H. Blackbourne, MD

Trauma, Burn, and Critical Care Surgeon
San Antonio, Texas

USMLE STEP 2 RECALL

Second Edition

EDITOR

Michael W. Ryan, MD, MS

Charlotte Gastroenterology and
Hepatology Charlotte, North Carolina



Wolters Kluwer | Lippincott Williams & Wilkins
Health

Philadelphia • Baltimore • New York • London
Buenos Aires • Hong Kong • Sydney • Tokyo

Acquisitions Editor: Susan Rhyner
Product Manager: Sirkka E. Howes
Marketing Manager: Brian Moody
Vendor Manager: Bridgett Dougherty
Manufacturing Manager: Margie Orzech
Design Coordinator: Holly Reid McLaughlin
Compositor: Aptara, Inc.

Second Edition

Copyright © 2011, 2007 Lippincott Williams & Wilkins, a Wolters Kluwer business.

351 West Camden Street
Baltimore, MD 21201

Two Commerce Square, 2001 Market Street
Philadelphia, PA 19103

Printed in China

All rights reserved. This book is protected by copyright. No part of this book may be reproduced or transmitted in any form or by any means, including as photocopies or scanned-in or other electronic copies, or utilized by any information storage and retrieval system without written permission from the copyright owner, except for brief quotations embodied in critical articles and reviews. Materials appearing in this book prepared by individuals as part of their official duties as U.S. government employees are not covered by the above-mentioned copyright. To request permission, please contact Lippincott Williams & Wilkins at Two Commerce Square, 2001 Market Street, Philadelphia, PA 19103, via email at permissions@lww.com, or via website at lww.com (products and services).

9 8 7 6 5 4 3 2 1

Library of Congress Cataloging-in-Publication Data

USMLE step 2 recall / editor, Michael W. Ryan. — 2nd ed.

p. ; cm. — (Recall series)

Other title: USMLE step two recall

Includes index.

Rev. ed. of: USMLE step 2 recall / Michael W. Ryan. c2007.

ISBN 978-1-60547-907-1

1. Clinical medicine—Case studies. 2. Physicians—Licenses—United States—Examinations—Study guides. I. Ryan, Michael W. II. Ryan, Michael W. USMLE step 2 recall. III. Title: USMLE step two recall. IV. Series: Recall series.

[DNLN: 1. Medicine—Case Reports. 2. Medicine—Examination Questions. 3. Diagnosis, Differential—Case Reports. 4. Diagnosis, Differential—Examination Questions. W 18.2 U84 2011]

RC66.R93 2011

610.76—dc22

201000207

DISCLAIMER

Care has been taken to confirm the accuracy of the information present and to describe generally accepted practices. However, the authors, editors, and publisher are not responsible for errors or omissions or for any consequences from application of the information in this book and make no warranty, expressed or implied, with respect to the currency, completeness, or accuracy of the contents of the publication. Application of this information in a particular situation remains the professional responsibility of the practitioner; the clinical treatments described and recommended may not be considered absolute and universal recommendations.

The authors, editors, and publisher have exerted every effort to ensure that drug selection and dosage set forth in this text are in accordance with the current recommendations and practice at the time of publication. However, in view of ongoing research, changes in government regulations, and the constant flow of information relating to drug therapy and drug reactions, the reader is urged to check the package insert for each drug for any change in indications and dosage and for added warnings and precautions. This is particularly important when the recommended agent is a new or infrequently employed drug.

Some drugs and medical devices presented in this publication have Food and Drug Administration (FDA) clearance for limited use in restricted research settings. It is the responsibility of the health care provider to ascertain the FDA status of each drug or device planned for use in their clinical practice.

To purchase additional copies of this book, call our customer service department at (800) 638-3030 or fax orders to (301) 223-2320. International customers should call (301) 223-2300.

Visit Lippincott Williams & Wilkins on the Internet: <http://www.lww.com>. Lippincott Williams & Wilkins customer service representatives are available from 8:30 am to 6:00 pm, EST.

Dedication

This book is dedicated to Mary Donna Ryan.

Preface

Purchase this book if you are looking for a case-based book that reinforces important content stressed within the USMLE Step 2 exam through a question and answer format.

The case-based approach was chosen to simulate real questions on the exam. The active-learning question-and-answer format following the patient presentation was chosen to ensure rapid comprehension of essential material needed to do well on the Step 2 exam. Your confidence and mastery of the material will increase dramatically with each interactive case-based review session.

The content was chosen after comparing the official USMLE Step 2 study outline to the key points stressed in review questions and by students with high scores on the exam. Only the essential information is covered here.

Congratulations on purchasing an essential active-learning review tool for the USMLE Step 2 exam!

The Test

The USMLE Step 2 exam is now composed of the clinical knowledge (CK) and the clinical skills (CS) parts. The CS part is a 1-day live exam on 12 standardized patients. The CK exam is a 1-day multiple-choice computer-based examination. The information learned from this book will be useful for each part of the exam. It teaches pattern recognition for diseases tested in multiple-choice and live patient presentations. For further information regarding the CS exam, please visit www.usmle.org.

The CK exam is a computer-based test taken at Prometric Test Centers using FROG software. It is a 9-hour exam with 368 multiple-choice questions broken up into eight 60-minute blocks with 45 minutes of break time in between. An additional 15 minutes can be used during the 9-hour block to go through the FROG software tutorial. By visiting www.usmle.org you can become familiar with the FROG software prior to the test date. This will allow you to bypass the tutorial and an additional 15 minutes will be added to your break time. Once a question block is started, it must be completed within the time provided. Breaks may only be taken between question blocks. If you complete a question block early, this will be added to your break time.

Multiple-choice single-best-answer formats comprise over 80% of the exam questions. Single-best-answer matching sets comprise the remaining exam questions. This format typically has two questions related to a common topic with 4 to 26 possible answers to choose from. You may practice the exam question formats by visiting www.usmle.org.

To register for the exam, visit www.nbme.org and print out an application or apply on-line. You will need to specify a 3-month block of time during which you plan to take the examination. Once your application has been approved, you will be mailed an orange permit with your ID number on it. Do not lose this permit. The ID number is required to schedule an exam date with a Prometric Test Center and the orange permit must be provided on the day of the exam along with a photo ID to take the exam. For additional information and to schedule your exam date, please visit www.prometric.com.

Rest assured that the case-based, rapid-fire question-and-answer format in USMLE Step 2 Recall will provide you with the necessary fund of knowledge needed to excel on this examination.

Contents

Preface	vi
The Test	vii
Common Abbreviations	xi
1. Cardiology	1
Hypertension	1
Congestive Heart Failure	9
Chest Pain	17
Arrhythmias and Conduction Disorders	28
Shock	34
Miscellaneous Disorders	43
2. Pulmonary Disorders	45
Infectious Diseases	45
Obstructive and Restrictive Diseases	49
Miscellaneous Disorders	59
3. Gastroenterology	78
Upper GI Bleeding	78
Lower GI Bleeding	88
Diarrhea	95
Hepatic Inflammation	97
Cholestatic Disease	106
Pancreas	114
Miscellaneous Disorders	118
4. Nephrology	120
Renal Failure	120
Fluid and Electrolytes	125
Glomerular Diseases	134
Flank Pain	140
Miscellaneous Disorders	143
5. Endocrine Disorders	148
Diabetes Mellitus	148
Diseases of the Thyroid and Parathyroid Gland	154
Miscellaneous Disorders	160
6. Hematology and Oncology	170
Malignant Neoplasms	170
Anemias	181

7. Neurology	196
Infectious Diseases of the Central Nervous System	196
Degenerative and Hereditary Diseases of the Central Nervous System	202
Neoplasms	205
Demyelinating Disease	206
Diseases of Neuromuscular Junction and Muscle	209
Vascular Diseases of the Central Nervous System	214
Episodic Disorders	223
8. Rheumatology	226
General Musculoskeletal Problems	226
Disorders of the Back, Spine, and Bone	234
The Seronegative Spondyloarthropathies	237
Osteoarthritis and Arthropathies	241
9. Dermatology	248
Skin Eruptions	248
10. Obstetrics and Gynecology	266
Uterus	266
Ovary	269
Cervix	270
Menstrual Disorders	271
Breast	272
Complicated Pregnancy	273
Miscellaneous Conditions	278
11. Pediatrics	280
Gastroenterology	280
Head and Neck Infections	286
Infectious Diseases	291
Nephrology	306
Miscellaneous Disorders	308
Miscellaneous Cases	311
12. Psychiatry	313
Psychosis	313
Disorders Originating in Childhood	315
Anxiety	316
Mood Disorders	320
Somatoform Disorders	327
Eating Disorders	331
Cognitive Disorders	333
Personality Disorders	337
13. Ethics, Statistics, and Epidemiology	340
Medical Ethics	340
Statistics and Epidemiology	340

APPENDIX

Table A–1. Immunizations	344
Table A–2. Growth and Development Chart	345
Index	351

Common Abbreviations

AAA	Abdominal aortic aneurysm, “triple A”
ABG	Arterial blood gas
ABI	Ankle to brachial index
ACE	Angiotensin-converting enzyme
Ach	Acetylcholine
ACTH	Adrenocorticotrophic hormone
AF	Atrial fibrillation
a.k.a.	Also known as
AMI	Acute myocardial infarction
AML	Acute myelogenous leukemia
ALL	Acute lymphoblastic leukemia
ALT	Alanine aminotransference
AR	Aortic regurgitation
ARDS	Acute respiratory distress syndrome
AS	Aortic stenosis
ASA	Aspirin
AST	Aspartate transaminase
AVM	Arteriovenous malformation
AXR	Abdominal x-ray
BCC	Basal cell carcinoma
BE	Barium enema
BPH	Benign prostatic hypertrophy
BRBPR	Bright red blood per rectum
BS	Bowel sounds, breath sounds, blood sugar
CA	Cancer
CABG	Coronary artery bypass graft (“CABBAGE”)
CAD	Coronary artery disease

xii Common Abbreviations

CAP	Community-acquired pneumonia
CBC	Complete blood cell count
CBD	Common bile duct
CHF	Congestive heart failure
CML	Chronic myelogenous leukemia
COPD	Chronic obstructive pulmonary disease
CRC	Colorectal cancer
CTA	Clear to auscultation
CVA	Cerebral vascular accident, costovertebral angle
CVP	Central venous pressure
CXR	Chest x-ray
DDx	Differential diagnosis
DI	Diabetes insipidus
DJD	Degenerative joint disease
DOE	Dyspnea on exertion
DVT	Deep venous thrombosis
ECT	Electroconvulsive therapy
EKG	Electrocardiogram
ERCP	Endoscopic retrograde cholangiopancreatography
EtOH	Alcohol
FAST	Focused abdominal sonogram for trauma
FEN	Fluids, electrolytes, nutrition
FNA	Fine needle aspiration
GBS	Guillain-Barré syndrome
GERD	Gastroesophageal reflux disease
GU	Genitourinary
HCM	Hypertrophic cardiomyopathy
HCT	Hematocrit
HG	Hemorrhagic gastritis
HTN	Hypertension
IABP	Intra-aortic balloon pump

IBD	Inflammatory bowel disease
ICU	Intensive care unit
IDU	Injection drug user
IE	Infective endocarditis
ILD	Interstitial lung disease
IPF	Idiopathic pulmonary fibrosis
IVC	Inferior vena cava
IVF	Intravenous fluids
IVP	Intravenous pyelography
IVPB	Intravenous piggyback
JVD	Jugular venous distention
LAP CHOLE	Laparoscopic cholecystectomy
LDH	Lactate dehydrogenase
LE	Lower extremity
LES	Lower esophageal sphincter
LLQ	Left lower quadrant
LR	Lactated Ringer's
LVH	Left ventricular hypertrophy
MEN	Multiple endocrine neoplasia
MI	Myocardial infarction
MIBG	¹³¹ I-metaiodobenzylguanidine
NGT	Nasogastric tube
NPO	Nothing per os
NS	Normal saline
PCa	Prostate cancer
PE	Pulmonary embolism, physical examination
PEEP	Positive end-expiratory pressure
PFT	Pulmonary function tests
PID	Pelvic inflammatory disease
PMI	Posterior myocardial infarction
PML	Progressive multifocal leukoencephalopathy

xiv Common Abbreviations

PO	Per os (by mouth)
PPD	Purified protein derivative
PT	prothrombin time
PTH	Parathyroid hormone
PR	Per rectum
PRN	As needed: literally “pro re nata”
PTCA	Percutaneous transluminal coronary angioplasty
PTSD	Posttraumatic stress disorder
PTU	Propylthiouracil
PTX	Pneumothorax
PUD	Peptic ulcer disease
PVE	Prosthetic valve endocarditis
q	Every
QD	Every day
QOD	Every other day
RLQ	Right lower quadrant
RUQ	Right upper quadrant
Rx	Prescription
SBO	Small bowel obstruction
SCC	Squamous cell carcinoma
SIADH	Syndrome of inappropriate antidiuretic hormone
SLE	Systemic lupus erythematosus
STSG	Split thickness skin graft
SVC	Superior vena cava
T & C	Type and cross
T & S	Type and screen
TB	Tuberculosis
TCA	Tricyclic antidepressant
TEE	Transesophageal echocardiography
TSH	Thyroid-stimulating hormone
UE	Upper extremity

UGI	Upper gastrointestinal
UO	Urine output
URTI	Upper respiratory tract infection
US	Ultrasound
UTI	Urinary tract infection
VSD	Ventricular septal defect
–	No, negative
+	Yes, positive
↑	Increase, more
↓	Decrease, less
<	Less than
>	Greater than

Chapter 1

Cardiology

HYPERTENSION

CASE 1

An 11-year-old boy presents to you after being found to have elevated blood pressure (BP) at a community health fair. You confirm elevated BP in his arm and are impressed with asymmetric pulses in the arms, weak leg pulses, and a harsh systolic murmur between the scapulae.

What should you do next on your physical exam?

Take the BP in the legs

Why? What do you suspect?

Coarctation of the aorta

What childhood disease is associated with this?

Turner's syndrome

BP in legs is normal. What's your probable diagnosis?

Coarctation of the aorta

What causes it?

A localized narrowing of the aortic arch just distal to the origin of the left subclavian artery

How does it present?

Usually with asymptomatic HTN

What signs are found on physical exam?

Asymmetric pulses in the upper extremities with absent or weak pulses in the lower extremities; harsh systolic murmur between the scapulae

What additional tests should you order to support your diagnosis?

EKG, CXR

What findings do you expect on EKG?

Left ventricular hypertrophy

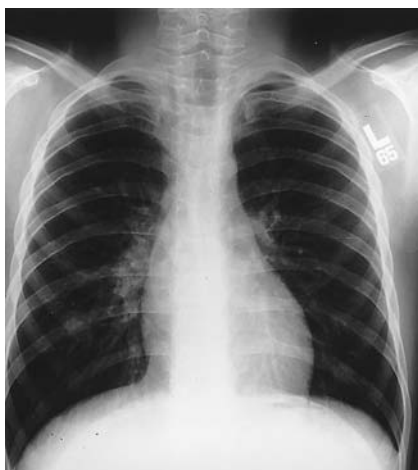

Figure 1–1.

(From LifeART image© [2010], Lippincott Williams & Wilkins. All rights reserved.)

What classic sign of coarctation of the aorta CXR finding is depicted in Figure 1–1?

Rib notching on CXR

Describe the CXR in Figure 1–1.

Normal pulmonary vasculature with an indented aortic knob with rib notching, a well-rounded left cardiac border, and laterally displaced cardiac apex

What test will confirm the diagnosis?

Arteriogram or Doppler echo

What is the treatment?

Surgery

CASE 2

A 44-year-old female with history of gout, chronic hepatitis C, and diverticulosis presents with weakness, fatigue, easy bruising, puffy cheeks, and new onset acne and HTN.

What's most likely causing her HTN?

Cushing's syndrome

What causes it?	Adrenal overproduction (due to adrenal tumors or from ectopic ACTH stimulation from an oat-cell lung cancer) and exogenously administered steroid (most common)
When does Cushing's syndrome become Cushing's disease?	When excess cortisol is produced by abnormally increased secretion of ACTH secreted by the pituitary (pituitary adenoma)
What are the symptoms?	Weakness, fatigue, moodiness, and easy bruising
What are the signs?	HTN and cushingoid appearance (truncal obesity, abdominal striae, impaired glucose tolerance, hirsutism, acne, and osteoporosis)
What lab values suggest the diagnosis?	Increased serum, urinary cortisol, and cortisol metabolites; hypokalemia and mild hyperglycemia (effects of cortisol)
What diagnostic test should you order?	1 mg overnight dexamethasone suppression test and 24-hour urinary-free cortisol
What is the treatment for pituitary tumors?	Transphenoid microadenectomy
What is the treatment for adrenal tumors and oat-cell lung cancer?	Surgical resection, if possible

CASE 3

A 49-year-old overweight diabetic male presents to your clinic after an extensive evaluation in another state for new onset of HTN. His prior physician ruled out secondary causes of HTN including hyperaldosteronism, pheochromocytoma, renal parenchymal HTN, renovascular disease, coarctation of the aorta, and Cushing syndrome. Currently, his BP is 144/83 mm Hg, pulse 76/min, and creatinine 1.0 mg/dl on hydrochlorothiazide.

4 USMLE Step 2 Recall

What type of HTN does he have?	Essential HTN
How was the diagnosis made?	BP \geq 125/75 mm Hg on 2 occasions after secondary causes ruled out
What is essential HTN?	The most common (\sim 95% of cases) form of HTN after secondary causes ruled out
What are his risk factors?	Age, diabetes, and overweight
Name other known risk factors	Kidney disease, physical inactivity, consumption of excessive amounts of alcohol
What physical findings on exam would support chronic uncontrolled HTN?	Hypertensive retinopathy, laterally displaced PMI, and/or S ₄ gallop
Is his BP currently under control?	No
What's his goal BP?	<125/75 mm Hg
What's your treatment strategy?	Lifestyle modifications and antihypertensives
Describe the lifestyle modifications	Aerobic exercise, weight loss if overweight, dietary sodium restriction, alcohol <2 drinks per day
What is a commonly used first-line antihypertensive?	Hydrochlorothiazide (patient already on)
What antihypertensive class should be considered in the following patients?	
Diabetics (this patient) and patients with controlled heart failure	ACE inhibitors
Underlying coronary artery disease (CAD) or history of myocardial infarction (MI)	β -blockers

What other anti-hypertensives are available?	Angiotensin receptor antagonists, α -blockers, calcium antagonists, sympatholytic and direct vasodilator drugs
How many drugs are often needed to control BP?	Three or more, to attain goal BP levels
Why is it important to control BP?	To decrease risk of kidney insufficiency or failure, left ventricular hypertrophy, heart failure, myocardial infarction, and/or peripheral arterial disease

CASE 4

A 35-year-old male with uncontrolled HTN on 4 medications presents to your office for follow-up after addition of the fourth medication. His BP remains elevated at 155/90 mm Hg. His serum chemistry panel has routinely shown mildly low potassium, which has not corrected with potassium supplementation.

What should you suspect?	Hyperaldosteronism
What were the clues?	Uncontrolled HTN on multiple agents with hypokalemia
Who is at risk?	Typically persons between the ages of 30 and 50 years, with women affected more often than men
What causes primary hyperaldosteronism?	Autonomous secretion of aldosterone from the adrenal gland as a consequence of either a solitary adenoma (most common) or less commonly hyperplasia of both adrenal glands
What screening test should you order to workup hyperaldosteronism?	Morning plasma aldosterone:renin ratio
What is a positive screening test?	Ratio >25 with an elevated plasma aldosterone level

How is the diagnosis confirmed?

Inability of intravenous or oral salt-loading to suppress 24-hour urinary excretion of aldosterone to $<14 \mu\text{g}$, or inability of plasma aldosterone:renin ratio to suppress to <30 after 50 mg oral captopril

What imaging tests should be ordered?

CT or MRI scanning is preferred for localization and determining type of adrenal pathology, although adrenal vein sampling and adrenal NP-59 scans can help localize site of autonomous production.

How is primary hyperaldosteronism treated?

Medical or surgical (unilateral adrenalectomy) therapies

What are the indications for surgical therapy?

Unilateral adenoma in a good surgical candidate

What are the indications for medical therapy?

Unilateral adenoma in a poor surgical candidate and bilateral adrenal hyperplasia

What medical therapies are useful?

Thiazide and potassium-sparing diuretics—spironolactone, potassium supplements, and calcium antagonists are especially useful along with other antihypertensive agents and dietary sodium restriction.

CASE 5

A 38-year-old male presents to your clinic with history of labile HTN unresponsive to 4 commonly prescribed antihypertensives. He is adamant that he has been taking all his medications as prescribed and has new complaints of episodic sweating, headache, and rapid heart rate. At first, he thought he might have the flu, but now he's not sure.

What do you suspect?

Pheochromocytoma

Why?

Episodic headache, sweating, and tachycardia is the classic triad of symptoms for pheochromocytoma.

What relatively common conditions might pheochromocytoma be confused with?

Labile HTN with hyperdynamic circulation, thyrotoxicosis, ingestion of sympathomimetic drugs, and abrupt discontinuation of sympatholytic drugs causing rebound HTN

What other diseases is pheochromocytoma associated with?

Von Hippel–Lindau’s and neurofibromatosis, MEN type 2A and 2B

What causes it?

A paraganglioma tumor arising from chromaffin cells in the adrenal medulla that secretes catecholamines—norepinephrine, epinephrine, dopamine—either continuously or episodically

What screening tests should you order?

Plasma metanephrines:creatinine ratio, plasma catecholamines, timed urine collections for metanephrines, metanephrines:creatinine urine catecholamines, and 3-methoxy-4-hydroxymandelic acid (VMA)

Are there differences among the screening tests?

Twenty-four-hour urinary metanephrine:creatinine ratio is more specific than urinary metanephrines (fewer false positives) and plasma metanephrine:creatinine ratio is more sensitive than plasma catecholamines.

What’s the next step after a positive screening test?

Image by MRI or CT to locate the pheochromocytoma

Which imaging modality is more sensitive for extra-adrenal pheochromocytomas?

MRI

What other tests are useful in localizing pheochromocytoma?

^{123}I - or ^{131}I -metaiodobenzylguanidine (MIBG) scintigraphy

What’s the treatment?

Preoperative, α -adrenergic blockade phenoxylbenzamine (dibenzylamine) followed by surgical resection

CASE 6

A 55-year-old diabetic female with history of 30 pack years smoking and refractory HTN follows up in your clinic after addition of an ACE inhibitor to her antihypertensive regimen. You review the chemistry panel taken 2 weeks after starting the ACE inhibitor and are surprised to find the serum creatinine has risen from 0.8 to 1.5.

What other diagnosis should be considered?

Renal parenchymal HTN

What is it?

The most common form of secondary or surgically curable HTN occurring as a consequence of critical stenosis of one or both renal arteries

What are the most common causes of renovascular HTN?

Atherosclerosis in late middle-aged and older persons and fibromuscular dysplasia in younger women

What was the clinical clue that renovascular HTN may be present in this patient?

Precipitous rise in creatinine after initiation of ACE inhibitors

How can it present?

Refractory HTN, HTN with renal insufficiency, or renal insufficiency without HTN (ischemic nephropathy)

What risk factors does she have?

Smoker, diabetes mellitus, older, long-standing essential HTN

What other risk factor might she have?

Atherosclerotic disease

What physical exam finding suggests the diagnosis?

Abdominal upper quadrant bruit

What is the workup for renovascular HTN?

Two major screening tests are renal artery duplex scan and captopril renogram.

What are the major diagnostic tests?

Renal angiography is the gold standard and, except in the most high-probability cases, is most useful after obtaining an abnormal functional screening test.

What other renal artery imaging tests are useful in defining renal artery anatomy?

Magnetic resonance angiography, carbon dioxide angiography, and helical CT

What is the treatment for renovascular HTN?

Medical therapy with lifestyle changes and drugs, renal angioplasty with stent placement or surgical revascularization

CONGESTIVE HEART FAILURE

CASE 7

A 45-year-old female with history of urinary tract infections (UTIs), pyelonephritis, and tertiary syphilis presents to the clinic with insidious onset of dyspnea and heart palpitations. On physical examination, you are impressed by the rapid upstroke and downstroke of the pulse and appreciate a diastolic decrescendo murmur at the second intercostal space and a late diastolic rumble at the apex.

What's your differential diagnosis?

Aortic regurgitation, patent ductus arteriosus, pulmonary regurgitation

What is most likely causing this murmur?

Aortic regurgitation

What is aortic regurgitation (AR)?

Regurgitation of the blood flow back into the left ventricle (LV) because of a structural abnormality of the aortic valve, the ascending aorta, or both

What risk factor does she have?

History of tertiary syphilis

What is the most common cause in

Adults?

Bicuspid aortic valve

Children?

Congenital ventricular septal defect with aortic valve prolapse

What other causes are there?

IE, myxomatous degeneration, aortic dissection, fenfluramine, dexfenfluramine, Takayasu's arteritis, and granulomatous arteritis

Is her presentation consistent with AR?

Yes. Dyspnea, palpitations, and orthopnea may all occur, but some patients are asymptomatic.

Describe the murmur heard in AR on PE

High-pitched diastolic decrescendo murmur at the left sternal border. There may be an apical diastolic rumble and/or an enlarged and displaced apical pulse.

Describe these PE exam findings:

Quincke's pulse

Visible pulsations in the capillaries with gentle compression of the nail bed

Pulse pressure

Widened pulse pressure (systolic BP elevated and diastolic BP < 60 mm Hg)

Corrigan's pulse

Visualizing a "water-hammer pulse"—a rapid rise and sudden collapse of the pulse

Traube's sign

"Pistol-shot" sound heard over the femoral artery

Austin Flint murmur

Soft, low-pitched, rumbling mid-diastolic bruit caused by the displacement of the anterior leaflet of the mitral valve by the AR stream

What tests should you order?

Echocardiogram, CXR, and EKG

Describe the result you expect on the EKG

Usually normal, but may have findings of LVH

CXR

Increased cardiothoracic ratio in chronic AR

Echocardiogram?

High-frequency diastolic fluttering of the anterior leaflet of the mitral valve from diastolic regurgitation from the aorta. Aortic valve findings differ based on etiology.

How is it diagnosed?	Physical examination and echocardiogram described above
What is the treatment for AR?	Avoid strenuous activity, antibiotic prophylaxis against endocarditis is advised, and vasodilator therapy
What's the first choice for vasodilator therapy?	ACE inhibitors
What about second-line therapy?	Hydralazine or nifedipine
When is aortic valve replacement indicated?	Heart failure despite medical therapy

CASE 8

A 65-year-old male with history of BPH, HTN, and hyperlipidemia presents to the clinic after having 2 near-syncope events while climbing stairs at home and at a football stadium. During each episode he became severely dyspneic, resolving with rest. On physical exam you appreciate a dampened carotid upstroke, and late-peaking crescendo-decrescendo systolic ejection murmur at the left sternal boarder radiating to the carotid arteries.

What's your differential diagnosis?	Atypical angina, aortic stenosis, HCM, mitral regurgitation (MR), ventricular septal defect, and aortic sclerosis
What is most likely?	Aortic stenosis (AS)
What is the classic presentation?	Exertional dyspnea most common, followed by angina, syncope, and congestive heart failure (CHF)
What causes these symptoms?	Narrowing of the aortic valve orifice with progressive obstruction of left ventricular outflow leading to increased afterload leads to hypertrophy and wall stress resulting in decreased systemic and coronary blood flow

12 USMLE Step 2 Recall

What are the causes of AS?	Senile degenerative (most common, older patients, valve calcified and sclerosed), unicuspid or bicuspid valve (younger patients), rheumatic heart disease
What are the findings of the physical examination?	Dampened carotid upstroke, sustained left ventricular impulse, absent A2, and a late-peaking crescendo-decrescendo systolic ejection murmur at the left sternal border radiating to the carotid arteries
What tests should you order?	EKG, CXR, and echocardiogram
What results do you expect on the EKG?	LVH with T-wave inversion
CXR?	Calcifications seen in the area of the aortic valve and often dilatation of the ascending aorta
Echo?	Left ventricular wall thickening with a narrowed aortic valve orifice, elevated aortic valve gradient
How is it diagnosed?	Characteristic physical examination with confirmation by echocardiography
What is the treatment for mild AS?	Avoid dehydration and vasodilatation (e.g., diuretics and nitrates). Antibiotic prophylaxis against endocarditis is required for dental procedures or surgery.
Define severe AS	Pressure gradient >50 mm Hg and valve area <1 cm ²
What is the treatment of severe AS?	Surgical valve replacement
When is aortic valve replacement surgery indicated?	Severe AS with symptoms (dyspnea, congestive heart failure, syncope, or angina)

CASE 9

A 28-year-old male returns to your clinic after complaining of worsening shortness of breath while playing soccer and a few episodes of passing out after getting out of a chair at his home. A brief physical exam reveals a sustained left ventricular apical impulse, S3, and a systolic ejection murmur.

What diagnosis should you consider?	HCM
What is HCM?	Left and/or right ventricular hypertrophy, usually asymmetric, involving the intraventricular septum
What are the causes?	Often unknown, but an autosomal dominant hereditary form has been described
Which symptoms suggest HCM?	Triad of DOE, presyncope, and angina
What is the range of presentations possible with HCM?	Asymptomatic, any combination of classic triad above to sudden cardiac death
What may be appreciated on physical examination by Palpation?	Sustained left ventricular apex
Auscultation?	Harsh systolic ejection murmur with radiation to the base and apex (but not the neck) that increases with Valsalva maneuver or squat-to-stand maneuver and decreases with squatting and leg raising. S3 and S4 are both common.
What EKG findings do you expect?	LVH with deep, broad Q waves that simulate a myocardial infarction
What are the associated CXR findings?	Usually normal
How is HCM diagnosed?	Echocardiogram
What is the treatment?	Avoid competitive sports and strenuous activity and β -blockers. Consider implantable defibrillator (AICD) in patients at high risk for sudden death.

CASE 10

A 38-year-old female with history of appendectomy, depression, and mitral valve prolapse presents to your clinic complaining of progressive fatigue and weakness over the last few months. She denies symptoms of depression and has been sleeping well despite waking up infrequently short of breath (SOB). On physical exam, you appreciate a holosystolic murmur with a diminished S1 and splitting of S2.

What's most likely causing her symptoms?

Chronic MR

What is MR?

Reverse (regurgitant) blood flow across the mitral valve from the LV into the left atrium

What was her primary risk factor?

Mitral valve prolapse

Name some other risk factors.

Rheumatic heart disease (1/3 of cases), mitral annular calcification (age-related), endocarditis, congenital, papillary muscle dysfunction (ischemia/myocardial infarction), and any disease that enlarges the LV (cardiomyopathies)

How does chronic MR classically present?

Asymptomatic until late in the disease progression, then with fatigue and weakness followed by dyspnea, orthopnea, and paroxysmal nocturnal dyspnea

How would acute MR commonly present?

Dyspnea and pulmonary congestion, secondary to sudden increase in the left ventricular end-diastolic pressure and left atrial pressure in a normal left atrium and LV

What may be found on EKG?

Left atrial enlargement or an LVH pattern. Atrial fibrillation may be present as the atrium enlarges.

CXR?

Straightening of the left heart border, an atrial double density, or elevation of the left main-stem bronchus. Mitral valve calcifications may be seen.

What diagnostic test should you order?

Echocardiogram

What is the medical treatment of MR?**Acute MR**

Intravenous vasodilators (nitroprusside), intravenous inotropes, and possibly intra-aortic balloon counterpulsation followed by mitral valve replacement

Chronic MR

Treat underlying cause (e.g., ischemia). Afterload reducing with ACE inhibitors is the initial treatment, considered for mitral valve replacement surgery.

CASE 11

A 62-year-old male with history of CAD s/p MI resulting in abnormal LV systolic function and CHF presents to the hospital after running out of his heart medications 3 days ago with gradual onset of dyspnea. It's so bad that he can barely walk across the room and is unable to lie down without getting short-winded. He does not have any chest pain like he did before his last heart attack. A CXR upon arrival is shown in Figure 1–2.

Describe the CXR findings.

Streaky white lines representing a reticular pattern of interstitial edema radiating from the hilar region, consistent with Kerley B lines frequently found in patients with heart failure

What is the most likely cause of his dyspnea?

Pulmonary edema from CHF secondary and noncompliance with medications

What other causes should be considered?

Left ventricular failure, myocardial infarction, valvular heart disease, arrhythmias, and hypertensive crisis

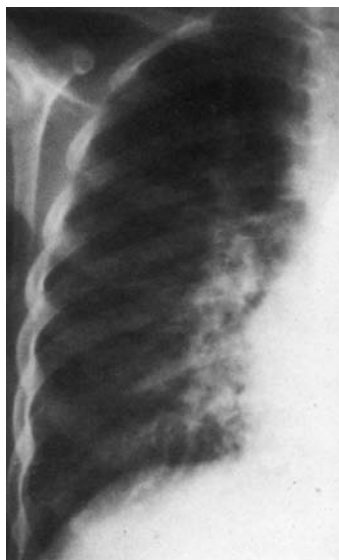

Figure 1-2.

(From Swischuk LE. Emergency Radiology of the Acutely Ill or Injured Child. 2nd Ed. Philadelphia: Lippincott Williams & Wilkins, 1986:85.)

Why are patients with pulmonary edema SOB?

Congested lung tissue with fluid in the interstitial spaces and alveoli increases the diffusion gradient, resulting in less oxygen transported to red blood cells.

What symptoms are common with pulmonary edema?

Dyspnea, tachypnea, anxiety, restlessness

What physical exam findings of pulmonary edema should you look for?

Rales, rhonchi, wheezing, use of accessory respiratory muscles. Pink frothy expectorate common in cardiogenic edema

What labs and tests should be included in the workup?

Chem 8, CXR, CBC, CK-MB, troponin, EKG, ABG

What are the CXR findings?

Diffuse bilateral interstitial and perihilar vascular engorgement, alveolar infiltrates

What other CXR findings are more likely in cardiogenic edema?

Kerley B lines, pleural effusions, possible enlarged heart

Do the findings on CXR always correlate well with the clinical findings?

No, it can take hours for CXR findings to appear once symptoms develop, and it may take days for the CXR to return to normal once therapy is initiated.

How can cardiogenic and noncardiogenic edema be differentiated?

Clinical history most often

What is the treatment?

Correct underlying cause, oxygen; diuretics (furosemide) in cardiogenic edema

What lab value indicates adequate treatment?

An arterial oxygen tension >60 mm Hg

What additional pharmacologic agents may be used if above therapy is inadequate?

Morphine sulfate, nitroglycerin, nitroprusside, and inotropic agents (e.g., dobutamine or phosphodiesterase inhibitors) can be helpful in cardiogenic edema.

When is mechanical ventilation indicated?

Coexisting hypercapnia or inadequate oxygenation ($\text{PaO}_2 < 60$ mm Hg on FIO_2 100% by mask)

CHEST PAIN

CASE 12

A 34-year-old male heroin abuser returns to the emergency department (ED) again complaining of pain in triage thought to be fictitious in an effort to receive narcotics and is found to have a fever of 39°C , p95, BP 120/75 mm Hg, and r26. He describes sharp chest pain that worsens with deep breathing. It is not associated with exertion. He also complains of chills, dyspnea, and generalized weakness. Physical exam reveals a thin male with numerous skin popping sites on both forearms and legs, 3/6 systolic ejection murmur, normal breath sounds bilaterally, and splinter-like hemorrhages within the nail beds.

What infectious process can explain all this? IE

What is it?

IE occurs when organisms colonize vegetations (nonbacterial thrombotic endocarditis) composed of fibrin and platelets which form in response to trauma to the endothelium or in areas of turbulent blood flow.

What is the pathogenesis of IE?

Transient bacteremia which occurs secondary to another infection or as a result of invasive procedures involving mucosal surfaces that are normally colonized with bacteria

What behavior in this patient most likely caused his bacteremia?

IVDA (unsterile needle and/or skin contamination)

What are the risk factors for persistent bacteremia and IE?

A previous episode of IE, mitral valve prolapse, which is associated with mitral regurgitation, degenerative, calcific valvular disease, congenital cardiac disease (including patent ductus arteriosus, ventricular septal defect, aortic coarct, bicuspid aortic valve), rheumatic valvular disease, and prosthetic valves

How does IE present?

Patients may have an acute or subacute presentation. Common symptoms include fever, chills, weakness, dyspnea, sweats, anorexia, weight loss, malaise, myalgia/arthralgia, headache, and stroke syndromes.

What signs and symptoms are suggestive of right-sided IE in injection (IDUs)?

IDUs present with similar systemic symptoms. In addition, they may have pleuritic chest pain due to septic pulmonary emboli to the lungs from right-sided (tricuspid valve) IE.

What physical findings support the diagnosis of IE?

Fever, heart murmur, splenomegaly, cutaneous lesions (petechiae, Osler's nodes, Janeway's lesions, splinter hemorrhages), retinal lesions (Roth's spots), clubbing, and focal neurologic findings if central nervous system embolic events have occurred

How is the diagnosis of IE confirmed?**Lab**

Blood cultures demonstrating persistent bacteremia

Imaging

Echocardiography

What test should be ordered if a transthoracic echocardiogram (TTE) is negative for vegetations?

Transesophageal echocardiogram (more sensitive)

Which ECHO test is most sensitive?

Transesophageal echocardiogram

Does a negative echocardiogram by itself rule out IE?

No

What blood culture results do you suspect in native valve IE in individuals who are not IDUs?**Most common**

Streptococci (mainly viridans streptococci), staphylococci, and enterococci

Less common

Gram-negative organisms (including the members of the “HACEK” group—*Hemophilus*, *Actinobacillus*, *Cardiobacterium*, *Eikenella*, and *Kingella*) and fungi

What is the most common cause of IE in IDUs?

Staphylococcus aureus

What is the most common cause of early (occurring within 60 days of surgery) prosthetic valve endocarditis?

Staphylococcus epidermidis. Late PVE has a similar microbiology to native valve IE.

How is IE treated?

Antibiotics are given based on the identification and susceptibilities of the infecting organisms.

When is valve replacement warranted?

Severe congestive heart failure, paravalvular abscess, one or more major arterial embolic events, inability to sterilize the blood cultures, or relapse after appropriate therapy

When is antibiotic prophylaxis recommended?

Patients with known risk factor for IE who undergo procedures that are associated with a risk of transient bacteremia

CASE 13

A 55-year-old previously healthy male presents to your office after recovering from a flu-like illness last week now complaining of persistent substernal nonradiating chest pain that worsens with inspiration and decreases when seated upright. It is not associated with exercise and the only thing that seemed to lessen the pain was over-the-counter ibuprofen. An EKG up on arrival is shown in Figure 1–3.

What diagnosis do you suspect?

Acute pericarditis

Why?

Classic symptoms and EKG findings (diffuse ST segment elevations)

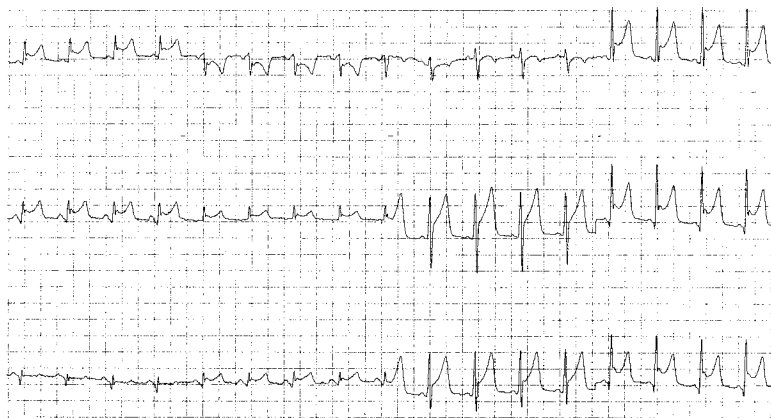


Figure 1–3. Electrocardiogram of a 55-year-old man. Note the diffuse, concave-upward ST-segment elevation. (From Harwood-Nuss A, Wolfson AB, Linden C, et al. *The Clinical Practice of Emergency Medicine*. 3rd Ed. Philadelphia: Lippincott Williams & Wilkins, 2001.)

What are the symptoms of acute pericarditis?

The only symptom is chest pain—usually substernal, constant, nonradiating; may worsen with inspiration, may lessen with sitting up.

What are the most common pathogens in acute viral pericarditis?

Echovirus and Coxsackie B5, B6

What drugs can cause pericarditis?

Procainamide and hydralazine

What are the physical signs of acute pericarditis?

The only sign is the pericardial friction rub which may be present, absent, intermittent, or changing over time.

What blood tests are specific for diagnosing acute viral pericarditis?

None. Erythrocyte sedimentation rate will be increased and there may be a mild leukocytosis.

What's the treatment of acute viral pericarditis?

Aspirin or a nonsteroidal anti-inflammatory drug

CASE 14

A 63-year-old male with history of uncontrolled HTN secondary to noncompliance with medications presents after lifting heavy boxes in his basement with severe, sharp “tearing” sensation in the posterior chest and back followed by near syncope. EMS reported that his carotid pulsations were unequal and the BP in his arms differed by >20 mm Hg.

What diagnosis do you suspect?

Acute aortic dissection

What else is in the differential?

Pericarditis, pulmonary embolus, musculoskeletal pain, pleuritis, cholecystitis, peptic ulcer disease or perforating ulcer, acute pancreatitis

Why do you suspect aortic dissection?

Severe, sharp, or “tearing” posterior chest or back pain or anterior chest pain with or without radiation is characteristic.

What additional features may be present?	Syncope, a cerebrovascular accident, MI, or heart failure
What's the pathophysiology behind aortic dissection?	Blood separates the intima from the surrounding media and/or adventitia, creating a false lumen that produces pain
What was his risk factor for a medial tear?	Uncontrolled HTN (most common)
What other risk factors exist?	Marfan's and Ehlers-Danlos syndromes, blunt chest trauma, bicuspid aortic valve, coarctation of the aorta, arteritis (especially giant cell), pregnancy (third trimester to several months postpartum), Noonan's and Turner's syndromes
What may be found on physical exam?	Weak or absent carotid, brachial, or femoral pulse resulting from the intimal flap or compression by hematoma
What basic radiographic finding shown in Figure 1-4 helps support the diagnosis?	CXR revealing mediastinal and/or aortic widening

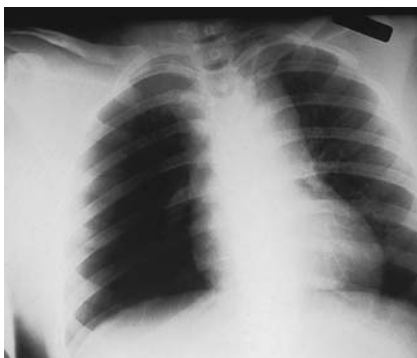

Figure 1-4. The chest radiograph shows a widened mediastinum from traumatic rupture of the aorta. (From Fleisher GR, Ludwig S, Baskin MN. *Atlas of Pediatric Emergency Medicine*. Philadelphia: Lippincott Williams & Wilkins, 2004.)

What 3 things, if present, strongly support the diagnosis of aortic dissection?

Acute onset of tearing and/or ripping chest pain, CXR revealing mediastinal and/or aortic widening, and unequal pulse pressure and/or BP (>20 mm Hg difference between the right and left arms)

Rank in descending order of sensitivity and specificity the imaging modalities for diagnosing aortic dissection.

MRI, CT scan, contrast aortography, transesophageal echocardiography

What is the medical treatment for acute aortic dissection?

Antihypertensives (β -blocker, calcium channel blocker—verapamil or diltiazem)

What additional BP medication should be considered if BP is unable to be controlled by one of the above medications?

Infusion of vasodilator such as IV nitroprusside

What are the indications for surgical management of aortic dissection?

Acute proximal dissection; acute distal dissection complicated by progression with vital organ compromise, rupture or impending rupture (saccular aneurysm formation), or retrograde extension into the ascending arch; any patient with Marfan's syndrome

CASE 15

A 35-year-old male beginner snowboarder presents to your office after returning from a ski trip out west where he complained of chest pain with movement. His father died of a heart attack and he is concerned he may be having an MI. The substernal chest pain does not occur with exertion like climbing stairs and he denies a history of diabetes, hyperlipidemia, or smoking. On physical exam, palpation over the sternum reproduces his pain.

What's the diagnosis?

Costochondral pain

What symptoms are typical?

Sharp localized pain in the anterior chest that is reproducible with palpation

Where does the pain come from?	Rib bones or rib cartilage
What is the main risk factor?	Recent chest trauma (e.g., falls, motor vehicle accident, etc.)
How is it diagnosed?	History, presentation with pain on palpation
What is the treatment?	NSAIDs

CASE 16

A 55-year-old male with history of HTN, diabetes, hyperlipidemia, smoking, peripheral vascular disease s/p vascular bypass presents to your clinic complaining of fatigue and substernal chest discomfort for the last few weeks. He describes the chest pain as a band-like squeezing sensation that gradually comes on with exertion and is relieved with rest. On occasions the discomfort radiates down his left arm with crushing chest discomfort. The chest pain does not change with position or respiration. He came in today because the pain has not gone away for hours.

What do you suspect?	Acute myocardial infarction (AMI)
What's the mechanism responsible for the vast majority of myocardial infarctions?	Disruption of atherosclerotic plaque, leading to platelet aggregation, thrombus formation, and occlusion of an epicardial coronary artery
How does AMI commonly present?	Severe substernal pressure or pain with radiation to the left arm, back, or jaw
What are his risk factors for AMI?	Cigarette smoking, diabetes mellitus, HTN, hypercholesterolemia
Is family history important?	Yes, history of CAD in a primary relative (parent, sibling, or offspring) is a risk factor as well
What other potentially catastrophic conditions should be considered when considering AMI?	Pulmonary embolus, dissecting thoracic aortic aneurysm

What physical exam findings may be present in AMI?	Pale, diaphoresis, cyanosis, weak pulse, distant heart sounds, S ₄
What finding on PE would suggest papillary muscle necrosis?	Blowing systolic murmur
What diagnostic labs and tests should be ordered?	CK-MB, troponin, EKG
How is AMI diagnosed?	Chest discomfort characteristic of ischemia with typical EKG changes and elevations in serum markers of myocardial injury (CK-MB and troponin)
Describe his ECG findings shown in Figure 1-5.	Q wave and S-T segment elevation in II, III, and aVF with reciprocal changes in anterior leads consistent with an acute inferior myocardial infarction
What are the minimum ST elevation criteria for diagnosing an AMI?	ST elevation in 2 contiguous leads: 0.1 mV in the limb leads; 0.2 mV in the precordial leads; 0.05 mV in leads RV ₃ and RV ₄

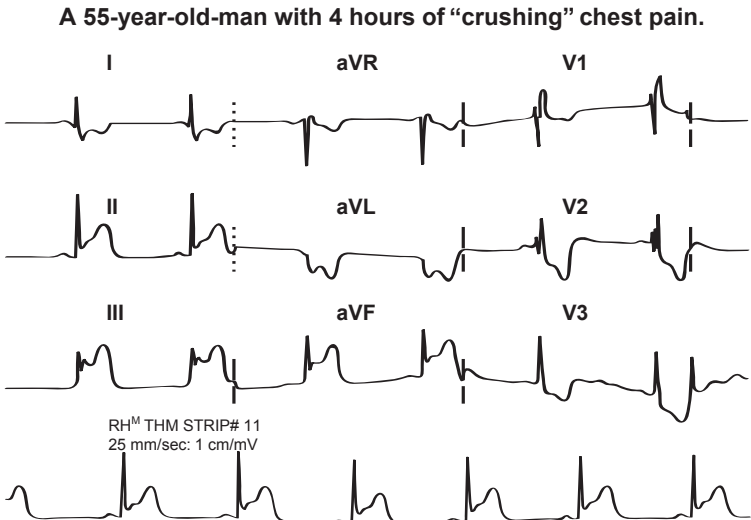


Figure 1-5. ECG shows Q wave and S-T segment elevation in II, III, and aVF and reciprocal changes in anterior leads. Signs of acute inferior myocardial infarction.

What single drug has been proven effective in both primary and secondary prevention of myocardial infarction?	Aspirin
What types of medication have been shown to improve long-term prognosis after an AMI?	Aspirin, β -blockers, statins, and, in patients with reduced left ventricular ejection fraction, ACE inhibitors
What is the treatment for acute ST segment elevation myocardial infarction?	In the absence of contraindications, IV administration of a thrombolytic (also known as fibrinolytic) agent. In hospitals, with a cardiac catheterization laboratory and cardiac surgery, primary percutaneous transluminal coronary angioplasty is an alternative treatment if it can be performed in a timely fashion.
What is the most devastating complication of administering a thrombolytic agent?	Both major and minor bleeding complications can occur. In 0.1% of cases, an intracranial bleed occurs, resulting in a hemorrhagic stroke.

CASE 17

A 45-year-old male presents to your office after being discharged from the hospital 1 week ago for pneumonia. He complains of worsening SOB and cough with a sharp stabbing left-sided chest pain that worsens with inspiration. He says that he was unable to complete his course of antibiotics because he could not afford the co-pay.

What's most likely causing his pain?	Pleurisy
How does it commonly present?	Dyspnea with a sharp, stabbing, unilateral, pleuritic chest pain
What is it?	Inflammation of parietal pleura of the lungs
What can cause it?	Connective tissue disease, lung/chest wall abscess, and pneumonia

What other common causes exist?	Malignancy (bronchial carcinoma), pulmonary infarction, and pneumothorax
What may be appreciated on physical exam?	Restricted breathing on affected side and friction rub on auscultation
What may the CXR reveal?	Pleural effusion
How is it diagnosed?	History and presentation
What is the treatment?	Correct underlying cause (complete course of antibiotics), NSAIDs, and aspirin

CASE 18

A 66-year-old male with history of HTN, CAD s/p MI, and 2 vessel CABGs 2 years ago presents to the ED after an motor vehicle accident (MVC) complaining of deep boring pain in the back that was not relieved by his PRN sublingual nitroglycerin or Tylenol ES. The pain is not like his prior angina pain

What's your differential?	MI, pancreatitis, vertebral fracture, AAA
Physical exam reveals a pulsating mass in the abdomen. What diagnosis is number one in your differential now?	AAA
Why?	Patient has identifiable risk factors for AAA and findings on physical exam are consistent with the diagnosis.
What are the risk factors?	Atherosclerosis (most common), HTN, smoking, family history of AAA, trauma, vasculitis, and Marfan's syndrome
Is this patient's presentation typical?	No. Patients often present as asymptomatic, but may present with a deep boring pain in the low back or flank as in this patient.
What's your best screening test?	Ultrasound (to locate and determine size of AAA)
diagnostic test?	CT with IV contrast

CT confirms localized dilatation of the abdominal aorta. What determines your therapy?

Centimeters of dilatation

What's the therapy of an AAA at

<5 cm?

Outpatient management with periodic ultrasounds to assess growth and current size

>5 cm?

Elective surgical resection of aneurysm and synthetic graft replacement

Why perform surgery at >5 cm?

Statistically significant risk of rupture

How does a ruptured AAA present?

Severe abdominal pain with hypotension, shock, or myocardial ischemia

What's the treatment for a ruptured AAA?

IV fluids, transfusion with packed RBCs as needed, and urgent surgery

ARRHYTHMIAS AND CONDUCTION DISORDERS

CASE 19

A 63-year-old male with history of HTN presents to your clinic with complaints of palpitations on and off for the last 2 weeks. Physical exam reveals an irregular heart rhythm. EKG is shown (Figure 1–6).

What's the diagnosis?

Atrial fibrillation (AF)

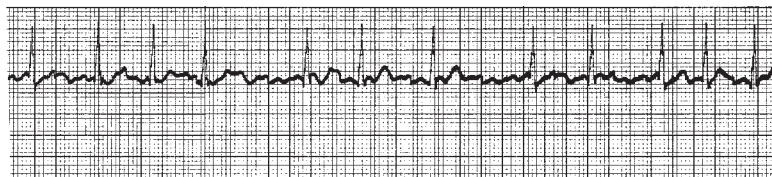

Figure 1–6.

(From Smeltzer SC, Bare BG. Textbook of Medical-Surgical Nursing. 9th Ed. Philadelphia: Lippincott Williams & Wilkins, 2000.)

Describe the diagnostic EKG findings.	EKG showing irregular fluctuating baseline without any visible P waves with an irregular ventricular response
Were his symptoms consistent with the diagnosis?	Yes, palpitations is a common complaint.
What other symptoms may patients present with?	“Skipped” beats, lightheadedness, breathlessness, angina, and syncope
What was his risk factor?	HTN
What other risk factors should be considered?	Drugs (cocaine, ethanol, theophylline, and caffeine), hyperthyroidism, pericarditis, ischemia, and MI
What is the initial treatment in the setting of hemodynamic compromise (myocardial ischemia, MI, hypotension, or CHF)?	Prompt electric cardioversion
What is the initial treatment goal in mild well-tolerated cases?	Control ventricular rate with calcium channel blockers, β -blockers, or digoxin and correct underlying cause.
When is digoxin use preferred?	In patients with coexisting CHF or severe LV dysfunction
What is the next therapy if AF has been present for greater than 48 hours at presentation?	Anticoagulation for 3 weeks before and after cardioversion
What purpose does anticoagulation serve?	Decrease risk of thromboembolic event
When is cardioversion without anticoagulation acceptable?	If AF has been present for less than 48 hours at presentation
What cardioversion therapy should be used first?	Chemical cardioversion with quinidine or procainamide

What alternative cardioversion therapy is available if pharmacotherapy fails?

Electric cardioversion

CASE 20

A 72-year-old female presents with lightheadedness and pulse rate around 150 with the EKG shown (Figure 1–7).

What's the diagnosis?

Atrial flutter

How is it diagnosed?

EKG showing regular undulation (sawtooth pattern) in the baseline with an atrial rate of 280–350/min

What underlying causes should be looked for?

HTN, drugs (cocaine, ethanol, theophylline, and caffeine), hyperthyroidism, pericarditis, ischemia, and MI

What's the typical presentation?

Usually asymptomatic, but may experience palpitations, syncope, and lightheadedness with higher heart rates

What is the treatment?

Correct underlying cause and consider low-voltage synchronized electric cardioversion if patient becomes unstable (e.g., hypotension, ischemic pain, or severe CHF)

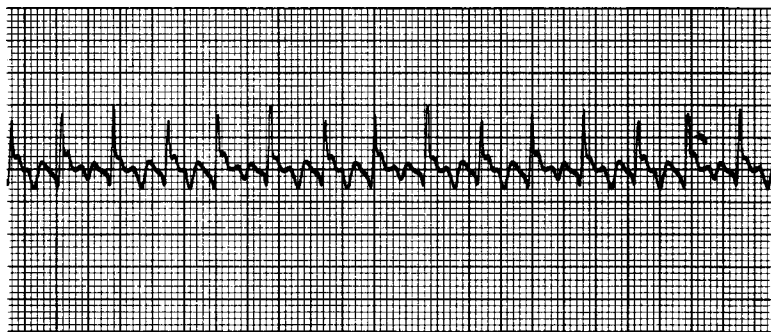


Figure 1–7.

(From Nettina SM. The Lippincott Manual of Nursing Practice. 7th Ed. Philadelphia: Lippincott Williams & Wilkins, 2001.)

CASE 21

A 44-year-old female presents complaining of infrequent heart palpitations and occasional lightheadness. On examination, you appreciate a pulse rate of 180/min. The EKG is shown (Figure 1–8).

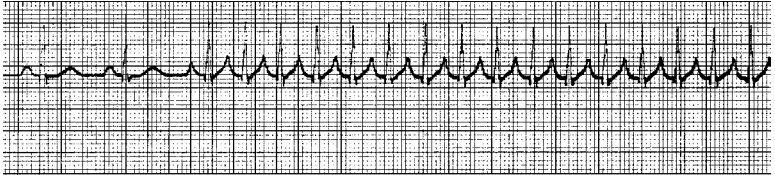


Figure 1–8.

(From Smeltzer SC, Bare BG. Textbook of Medical-Surgical Nursing. 9th Ed. Philadelphia: Lippincott Williams & Wilkins, 2000.)

What's the diagnosis?	AV nodal re-entrant tachycardia
What is it?	The most common paroxysmal supraventricular tachycardia that originates above the ventricles in the AV junction
What EKG findings are diagnostic?	Tachycardia and a characteristic pattern of P waves hidden in the T waves
Was this presentation common?	Yes, patients often present with sudden transient episodes of increased heart rate (150–250 bpm) with or without symptoms (palpitations, lightheadness, angina, and syncope).
What can cause it?	Stress, increased catecholamines, or MI
What is the initial therapy?	Vagal maneuvers (carotid sinus massage and Valsalva maneuver)
What is the next step if vagal maneuvers fail?	Adenosine, verapamil, or diltiazem to slow or block the AV node

CASE 22

Your medical resident calls you to 5 North to witness a cardiac arrest. As you enter the room he hands you the EKG shown (Figure 1–9).

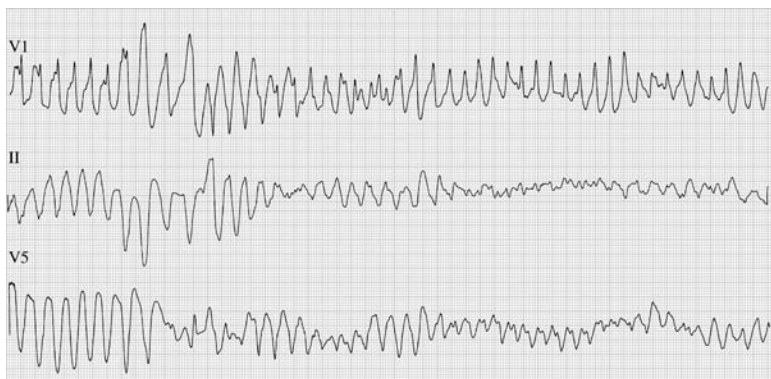

Figure 1–9.

(From Wagner GS. Marriott's Practical Electrocardiography. 10th Ed. Philadelphia: Lippincott Williams & Wilkins, 2001.)

What's your diagnosis?	Torsades de pointes (TdP)
What is the diagnostic EKG pattern?	A polymorphic ventricular tachycardia with QRS complexes that progressively change direction
What is the main risk factor?	A prolonged QT interval
What can prolong the QT interval?	Hypocalcemia, quinidine, and procainamide
What is the treatment?	IV bolus of magnesium sulfate and discontinue offending agents
What is an alternative therapy to magnesium sulfate?	Increase heart rate to 90–120 bpm using either isoproterenol or temporary pacing (both treatments shorten the QT interval)
When should electric cardioversion be considered?	In cases of sustained TdP despite above measures

CASE 23

A 35-year-old male diagnosed with metastatic colon cancer undergoes aggressive experimental chemotherapy and is found unresponsive at home after his second course of therapy. He arrives by EMS with the EKG shown (Figure 1–10).

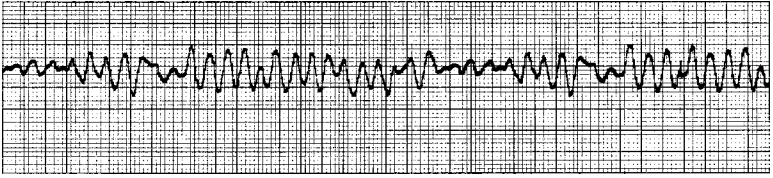


Figure 1-10.

(From Smeltzer SC, Bare BG. Textbook of Medical-Surgical Nursing. 9th Ed. Philadelphia: Lippincott Williams & Wilkins, 2000.)

What's the diagnosis?	Ventricular fibrillation
Define it.	A cardiac arrhythmia characterized by uncoordinated ventricular depolarizations and contractions that can result in absence of cardiac output and rapid death
Describe the diagnostic EKG findings.	Undulating baseline with no identifiable P waves or QRS complexes
What main risk factor should be considered?	Recent severe acute MI
What is the treatment?	Immediate unsynchronized electric cardioversion while giving epinephrine and then lidocaine
What is the next step once patient is cardioverted?	Continue lidocaine until any reversible causes can be corrected

CASE 24

A 52-year-old male complains of palpitations after watching his son's football team lose their opening game then passes out. Medical staff rushes to his side with an AED and the rhythm in Figure 1-11 shows up on the screen.

What's the diagnosis?	Ventricular tachycardia
Describe the diagnostic EKG findings.	EKG showing a series of 3 or more successive ventricular contractions (PVCs) with a wide QRS (usually >120 ms) at a rate of 100–250 bpm

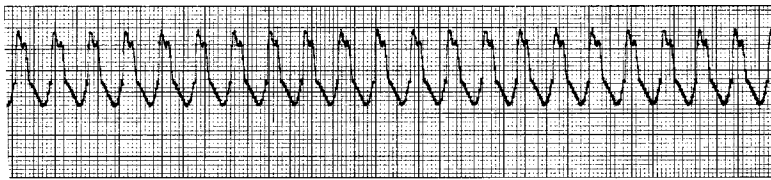


Figure 1-11.

(From Smeltzer SC, Bare BG. Textbook of Medical-Surgical Nursing. 9th Ed. Philadelphia: Lippincott Williams & Wilkins, 2000.)

What possible underlying causes are there?

Ischemia (coronary artery disease), MI, electrolyte imbalance, drugs, and cardiomyopathy

What is the treatment if patient is

Clinically stable?

Pharmacologic cardioversion with IV lidocaine (or procainamide) and correct underlying cause

Hemodynamically unstable?

Synchronized electric cardioversion

SHOCK

CASE 25

A 23-year-old male previously healthy presents to the ED by ambulance after being found in a parking lot with one anterior chest stab wound. Upon EMS arrival, the patient was alert and orientated, mildly tachycardic, and tachypnic with normal BP. Physical exam revealed a 2-cm linear laceration just left of the sternum. En route to the ED EMS reports that his BP is falling and jugular venous distention (JVD) is now evident on physical exam.

What's your differential diagnosis for hypotension and JVD?

Tension pneumothorax, cardiac tamponade, air embolism, and myocardial dysfunction

Which 2 are more likely in this patient?

Tension pneumothorax and cardiac tamponade

On exam, his lung sounds are normal, but decreased heart sounds are appreciated. Which do you suspect now?

Cardiac tamponade

What is the most common cause of cardiac tamponade?

Penetrating trauma to the anterior chest

What are the causes of cardiac tamponade in the nontrauma patient?

Metastatic malignancy (lung and breast most commonly), uremia, bacterial, or tubercular pericarditis, anticoagulant hemorrhage, systemic lupus erythematosus, postradiation

What is the mechanism behind cardiac tamponade?

Accumulation of intrapericardial fluid causes an increase in intrapericardial pressure. When this pressure exceeds the right atrial (RA) filling pressure, there is a decrease in the amount of blood delivered to the ventricles. The resultant decreased stroke volume may lead to hemodynamic compromise.

What are the clinical features of cardiac tamponade?

Classically, pulsus paradoxus >15 mm Hg, hypotension, JVD, and diminished heart sounds. Hypotension, JVD, and diminished heart sounds are known as Beck's triad.

What is pulsus paradoxus?

An abnormal drop in BP during inspiration because of the increase in afterload caused by negative intrapleural pressure

What labs should you order?

Comprehensive metabolic panel, complete blood count, PT, PTT, INR

What other tests should you order?

EKG, CXR, and TTE

What results do you expect to find on EKG?

It may show low QRS voltage and T-wave flattening, and may demonstrate electrical alternans (beat-to-beat variation in P- and R-wave amplitude).

CXR?

It may demonstrate a normal or enlarged cardiac silhouette, with clear lung fields.

TTE?

It may demonstrate as little as 15 mL of intrapericardial fluid. It may also demonstrate RA compression and RV diastolic collapse.

How is the diagnosis of cardiac tamponade made?

Based on clinical findings

What is the treatment of cardiac tamponade?

Fluid resuscitation via 2 large bore peripheral IV lines, followed by pericardiocentesis and thoracotomy. Pericardiocentesis is both diagnostic and therapeutic, but thoracotomy is the definitive therapy.

CASE 26

A 17-year-old female recently diagnosed with exudative pharyngitis presents to the ED with acute onset generalized rash, flushing, angioedema, headache, and near syncope after taking her first dose of her antibiotic. EMS reports her BP is 90/50 mm Hg with a pulse of 125/min.

What do you suspect?

Anaphylactic shock (AS) second to allergic reaction to penicillin

Name other causes of shock.

Cardiogenic, hemorrhagic, hypovolemic, septic

What is anaphylaxis?

An acute systemic reaction involving multiple organ systems to an IgE-mediated release of chemical mediators from mast cells and basophils, occurring in previously sensitized individuals and resulting in circulatory and respiratory collapse

What most likely triggered her attack?

PCN

Name other causes of anaphylaxis.

Bee stings, consumption of nuts or shellfish

Name the major spontaneously generated vasoactive mediator that results in anaphylaxis.	Arachidonic acid, leading to formation of leukotrienes, prostaglandins, thromboxane, prostacyclins
Will any lab or imaging tests aid in making the diagnosis?	No
How is the diagnosis of AS made?	Clinical history and physical exam
What is the initial management of AS?	Airway, breathing, circulation (ABC)
What is the management after the initial ABC?	Two large bore IV lines, fluid resuscitation, monitor, EPI, other pharmacological aids
What pharmacological aids are used to counteract AS?	Isotonic IV fluids, EPI, diphenhydramine, albuterol, Solu-Medrol, aminophiline, glucagon, dopamine, cimetidine

CASE 27

A 62-year-old female with known CAD s/p stent to right coronary artery 1 year ago presents to ED with 10/10 substernal pressure with radiation to neck and down right arm relieved partially by taking sublingual nitroglycerin at home. EMS reports that the patient has become more anxious and her skin has become cool and clammy while her heart rate increased.

What is her initial symptom complex consistent with?	AMI
What complication do you suspect after hearing the EMS report?	Cardiogenic shock (CS) second to AMI
What are the clinical S/Sx of CS?	Cool, clammy skin; oliguria; anxiety; confusion, tachycardia, increased vascular resistance

What is CS?	Hypoperfusion of tissues with failure to meet metabolic demand, and systolic blood pressure (SBP) <90 mm Hg, caused by inadequate myocardial contractility or by mechanical impairment of the heart
What is the incidence of CS after an AMI?	5–7%
What are some of the independent predictors of risk for developing CS post-AMI?	Advanced age, female, large or anterior wall MI, previous MI, history of CHF, multivessel coronary artery disease, proximal occlusion of the left anterior descending artery, and diabetes mellitus
What is the predominant cause of CS?	LV infarction
What mechanical impairments can lead to CS?	Pericardial tamponade, massive PE, acute mitral valve insufficiency, aortic dissection, ventricular septal wall rupture
In addition to an AMI, what other etiologies of decreased myocardial contractility can lead to CS?	Myocardial contusion, toxins or drugs, cardiomyopathy, dysrhythmias, heart block
What BP parameters are more sensitive measures of shock than SBP?	Mean arterial pressure (MAP): decrease >30 mm Hg; pulse pressure: <20 mm Hg
What lab studies are ordered to assess CS?	Arterial blood gas, serum bicarbonate or lactate, CK, CK-MB, and troponin
What additional tests should you order?	CXR, EKG, and transthoracic echo
What are the initial steps for stabilization of CS?	Oxygen, IV access, cardiac monitor, continuous pulse oximetry
What is the first drug given in the setting of an AMI?	Aspirin, 325 mg orally

What is the first-line treatment for RV infarction with hypotension?	Rapid IV infusion of 1 L 0.9 normal saline (NS), followed by dobutamine if no response
What drug increases myocardial contractility and augments coronary blood flow but does not induce reflex tachycardia?	Dobutamine
What drug is used in the setting of profound hypotension?	Dopamine
If shock persists after using drugs, what do you use?	Intra-aortic balloon pump

CASE 28

A 62-year-old white male with history of smoking, HTN, and psoriasis develops progressive abdominal pain and lightheadedness prior to the arrival of EMS. EMS finds tachycardia, tachypnea, cool clammy skin with poor capillary refill, pulsatile abdominal mass, and a systolic BP of 72 mm Hg. His friend said that before this happened he felt his heart beating in his abdomen.

The SBP of 72 mm Hg is consistent with what diagnosis?	Shock
What types of shock are there?	Cardiogenic, hemorrhagic, hypovolemic, septic, and anaphylactic
What type do you suspect here?	Hemorrhagic
What is hemorrhagic shock?	Tissue hypoxemia and hypoperfusion caused by rapid blood loss of sufficient quantity to overcome the body's compensatory mechanisms
What are the classic signs of acute hemorrhage?	Tachycardia, tachypnea, narrow pulse pressure, cool and clammy skin, oliguria, low CVP, altered mental status, hypotension

What are the 4 major etiological sources of acute hemorrhage?

Trauma, gastrointestinal tract, reproductive tract, vascular

Do his complaints of abdominal pain with a pulsating sensation help you determine a possible cause?

Yes, abdominal and/or back pain with a pulsating character is consistent with AAA.

What are his risk factors for AAA?

HTN, white, male, smoking, age

What other risk factors exist?

Atherosclerosis and family history

What is the initial management of hemorrhagic shock?

Airway, breathing, circulation (ABC)

What is the management after the initial ABC?

Two large bore IV lines; fluid resuscitation; monitor

In restoring circulation, why is the preferred route of venous access 2 large bore (16-gauge preferred) peripheral IV lines?

Peripheral IVs instill fluids faster secondary to their short length and larger diameter.

List the basic methods of hemodynamic monitoring for shock.

Electrocardiogram; pulse oximeter; CVP; end-tidal carbon dioxide; arterial BP, pulse, pulse pressure, respiratory rate

Name the resuscitation fluid of choice for the initial management of hemorrhagic shock.

0.9 NS or Ringer's lactate

When giving a fluid challenge, what is the optimal body position?

Supine, with legs elevated

What STAT labs should you order?

CBC, CMP, coags, type and cross for 6 PRBC

What imaging test will confirm your diagnosis?	Abdominal ultrasound
What STAT consult should you order?	Vascular surgery
What physiological indices can you use to gauge your resuscitation efforts?	Heart rate, BP, capillary refill, urine output, CVP
After 0.9 NS, what natural colloid should be used next for fluid resuscitation?	Packed red blood cells
What is the survival rate of patients who experience a ruptured abdominal aortic aneurysm?	Less than 50%

CASE 29

An 88-year-old nursing home patient with history of scleroderma and severe reflux disease with recurrent aspiration, urinary incontinence second to prostate cancer surgery years ago, and prior UTIs is transferred to the ED from his nursing home after becoming disorientated and hypotensive. Upon arrival, he is alert, but disorientated. Temperature is 38.5°C, pulse 110/min, BP 85/60 mm Hg with a respiratory rate of 25 breaths per minute.

What diagnosis is likely based on his vital signs?	Shock
What is the differential for shock?	Cardiogenic, hemorrhagic, hypovolemic, septic, and anaphylactic
Which is more likely here?	Septic shock
What vital sign tipped you off?	Temp >38°C
What are the 3 major organ sources of sepsis?	Abdomen, lungs, urinary tract
What other organ systems should be focused on?	CNS, skin, and soft tissue

Which organ sources are most likely in this patient?	Lung and urinary tract
What risk factors does this patient have for lung and urinary infection?	Dysphagia with aspiration risk (pneumonia risk) and urinary incontinence with prior UTIs
What's required to diagnose sepsis?	At least 2 of the following: (i) temperature $>38^{\circ}\text{C}$ or $<36^{\circ}\text{C}$; (ii) heart rate >90 bpm; (iii) respiratory rate >20 breaths per minute or $\text{PaCO}_2 <32$ mm Hg; (iv) white blood count $>12,000$ cells/ μL , <4000 cells/ μL , or $>10\%$ bands
Are the criteria met?	Yes
What is the first priority in the management of septic shock?	ABC
What is the management after the initial ABC?	Two large bore IV lines, fluid resuscitation, monitor heart rate and BP for response
What stat labs should you order?	CBC with differential, CMP, PT/INR, UA, UCX, blood cultures x2, sputum Gram-stain culture and sensitivity, CK-MB, troponin
What imaging should you order?	CXR
What cardiac test should you order?	EKG
What type of medication is critical in septic shock?	Antibiotics
What guides your choice of antibiotic therapy?	Empiric coverage for gram-negative and gram-positive bacteria. Coverage should be adjusted later once organism is identified and drug sensitivities are known.

MISCELLANEOUS DISORDERS

CASE 30

A 58-year-old female with history of CVA, diabetes, and HTN presents with infrequent calf pain after walking roughly 2 blocks that abates after slowing down or stopping.

What diagnosis do you suspect?	Claudication
Why?	Because it often presents with intermittent pain in an extremity with exercise or exertion and is relieved with rest.
What causes it?	Peripheral arterial vascular insufficiency in the extremities
What risk factors does this patient have for it?	Atherosclerosis and an atherosclerotic event (e.g., stroke, MI), diabetes
What other risk factors may other patients have?	Thrombosis, embolism, or trauma
What “classic” physical exam findings will you look for?	5 Ps: pain, pallor, pulselessness, paresthesia, and paralysis (end stage)
What additional finding may be found on physical exam?	Cool skin, hair loss, ulceration, and muscle atrophy in the affected area
What basic bedside test can support the diagnosis of claudication?	ABI to assess vascular insufficiency
How do you calculate the ABI?	Ratio of systolic blood pressure (SBP) in the ankle to the SBP in the arm
What do the following results suggest?	
ABI <1	Mild PVD
ABI <0.5	Severe PVD

44 USMLE Step 2 Recall

ABI is 0.8. What additional tests will confirm your diagnosis?

Ultrasound of affected area (assess vascular patency) and angiography (confirm ultrasound findings)

Imaging confirms mild disease. What's the treatment?

Diet, daily walking (increases collateral circulation), stop smoking, and reassess diabetic therapy if diabetes is present

What if the severe disease (ABI <0.5) with rest pain was present?

Surgical revascularization with autologous or synthetic grafting

Chapter 2

Pulmonary Disorders

INFECTIOUS DISEASES

CASE 1

A 54-year-old male with history of diabetes, COPD, PUD, HTN, and DJD presents to your clinic complaining of sudden onset of fever, productive cough with brown-colored sputum, dyspnea on exertion, and right lateral chest pain. His temperature is 103°F, pulse rate is 88/min, and respiratory rate is 26/min.

What diagnosis are you considering?

CAP

What were the clues?

Sudden onset of fever, cough productive of purulent sputum, shortness of breath with or without pleuritic chest pain

Is this patient's presentation characteristic of typical or atypical pneumonia?

Typical

How might atypical pneumonia present?

Gradual onset of dry cough, fevers, prominent extrapulmonary symptoms such as headaches, myalgias, sore throat, nausea, vomiting, and diarrhea

What are the most common organisms that cause "typical" CAP?

Streptococcus pneumoniae and *Hemophilus influenzae*

What are the most common organisms that cause "atypical" CAP?

Mycoplasma pneumoniae, *Chlamydia* species, *Legionella pneumophila*, influenza viruses

What risk factor does he have for pneumonia?

COPD

What organisms are common in patients with pneumonia and COPD?

H. influenzae, S. pneumoniae, Legionella

Of these 3 organisms, which do you suspect this patient has?

S. pneumoniae because he described his sputum as brown, which can be implied to mean rust colored

What organism would you have suspected if he had HIV?

Pneumocystis carinii

Recent seizures?

Aspiration pneumonia with mouth flora (*Peptostreptococcus, Fusobacterium, Bacteroides melaninogenicus*, aerobic streptococci)

Alcoholism?

Klebsiella, S. pneumoniae, H. influenzae

What finding on your lung exam would support pneumonia?

Localized rales or evidence of consolidation

What's your basic diagnostic workup?

Chem 8 (important to assess renal function if planning on giving antibiotics); CBC with differential (looking for evidence of infection); sputum Gram stain and culture (attempt to identify organism); CXR; ABG, if severely dyspneic; blood cultures, if hospitalized

What CBC results do you expect in this patient with suspected CAP?

Leukocytosis with a left shift (increased neutrophils)

Describe the patient's CXR finding shown in Figure 2-1 and how it explains his pain.

Right lower lobe (RLL) infiltrate (patient complained of right-sided pleuritic pain)

Now that the CXR reveals RLL infiltrate consistent with pneumonia, CBC positive for leukocytosis of 15,000 with left shift. What's your treatment plan?

Empiric therapy with a macrolide (e.g., erythromycin, azithromycin) or a fluoroquinolone (e.g., levofloxacin)

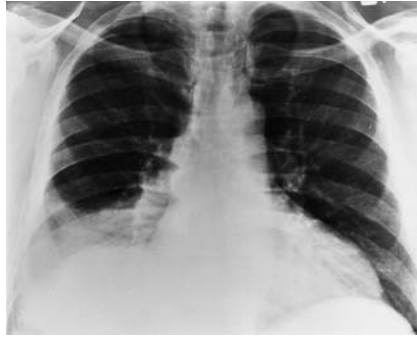

Figure 2–1.

(From Daffner RH. Clinical Radiology: The Essentials. 3rd Ed. Philadelphia: Lippincott Williams & Wilkins, 2007.)

CASE 2

A 66-year-old male with history of autoimmune hepatitis (recently prescribed azathioprine in addition to prednisone), hyperlipidemia, diabetes, and end-stage renal disease on hemodialysis is observed to be coughing blood-streaked phlegm while being hooked up to the dialysis equipment. The dialysis nurse further informs you that the patient is febrile at 103°F.

What differential are you considering?

Neoplasm (primary or metastatic), pneumonia, bronchiectasis, TB, vasculitis, anticoagulant drugs

Which are you most concerned about?

TB

Why?

Productive cough (often with blood streaking) associated with fevers/night sweats, malaise, anorexia, and weight loss are consistent with TB patients on presentation.

What risk factors does he have for TB?

Immunosuppressed with prednisone and immunan, >65 years old, diabetic, dialysis patient

Which social groups are at high risk for TB?

Immigrants from countries with high infection rates, residents of long-term care facilities, medically underserved

What causes TB and how is it transmitted?	<i>Mycobacterium tuberculosis</i> . Transmitted through respiratory droplets
What's your first order to the nurse?	Isolate the patient in a negative pressure room; patient and staff must wear masks.
What tests should be performed?	Sputum sample for acid-fast bacilli (AFB) stain and mycobacterial culture, PPD placement, labs, and CXR
What labs and imaging should you order in the meantime?	Chemistry panel, CBC with differential, liver chemistry tests, prothrombin time (PT) and international normalized ratio (INR), CXR
CXR reveals apical and posterior segment infiltrates with cavitation. What does this suggest?	Reactivation TB
What is often found in primary TB?	Mid- to lower-lung zones infiltrate with or without cavitation
Two days later you read the amount of induration on the PPD test and it is 12 mm. What does this indicate?	TB infection
How much induration is needed for a positive PPD in the following groups?	
High risk (HIV, close contact)	≥ 5 mm
Moderate risk (high-risk medical condition, immigrants, health-care workers)	≥ 10 mm Hg
Low risk (all others)	≥ 15 mm
What additional test can be performed if the diagnosis is not clear?	Bronchoscopy with bronchoalveolar lavage and biopsy if sputum negative but high degree of suspicion

What is the classic pathologic feature of TB?	Caseating granuloma
Which groups always need prophylactic therapy for a positive PPD?	Close contacts, HIV, recent infection, high-risk medical groups, health-care workers
Which groups need prophylaxis if <35 years?	Immigrants from high-risk areas, medically underserved, residents of long-term care facilities
Which antibiotic is usually used for prophylaxis?	Isoniazid
What are the 2 major treatment principles for TB?	Never treat with fewer than 2 drugs. Prolonged therapy is standard.
What are the 2 standard treatment regimens for TB?	Isoniazid, rifampin, and pyrazinamide for 2 months followed by isoniazid and rifampin for 4 months or isoniazid and rifampin for 9 months
What is the standard regimen for drug-resistant TB?	Initially add 12 additional antibiotics to the above 3 drugs (usually ethambutol or streptomycin). Drug regimen tailored after susceptibility testing available.
What are common side effects of isoniazid?	Hepatitis and peripheral neuropathy
What drug can be given to prevent the peripheral neuropathy?	Pyridoxine

OBSTRUCTIVE AND RESTRICTIVE DISEASES

CASE 3

A 16-year-old previously healthy female presents to your office complaining of a few instances of difficulty breathing, dry cough, and wheezing that lasts less than an hour. She also notes some chest tightness. The symptoms occur more frequently when unloading boxes in the basement in their new home or picking fruit on the family farm.

What's your differential for a young child wheezing?	Asthma, foreign body aspiration, cystic fibrosis, and viral bronchiolitis
What diagnosis do you suspect in this child?	Asthma
Why?	Intermittent episodes of shortness of breath, cough, and chest tightness are characteristic of asthma.
What do you suspect is causing her asthma?	Allergens at the farm (pollen) and basement (dust)
What other asthma triggers might be presented to you?	Irritants (fumes, smoke), chronic sinusitis, viral infection, exercise, cold weather, GERD, and possibly aspirin (especially in patients with nasal polyps)
What's the basic mechanism behind asthma?	A reversible airways disease characterized by hyperresponsiveness and bronchoconstriction of the airways to specific and nonspecific stimuli
What physical exam signs are present in mild attacks?	Tachypnea, wheezing, and a prolonged expiratory phase
What additional signs present in more severe attacks?	Inability to speak more than a few words, accessory muscle use, pulsus paradoxus, and distant breath sounds
In most cases, how is the diagnosis made?	By history and response to bronchodilator during an attack because most patients are asymptomatic in the clinic
What diagnostic test can you order to confirm obstructive lung disease when disease is active?	PFT
What ratio and value signifies obstruction?	FEV ₁ /FVC ratio <70%

What test can be performed if obstruction is not present on PFTs?	Methacholine challenge test. A positive test result supports the diagnosis of asthma while a negative test result rules it out.
What determines treatment?	Frequency of symptoms
Define the following and specify appropriate treatment:	
Mild intermittent	Fewer than 2 times a week; short-acting inhaled β -agonist as needed
Mild persistent	More than 2 times a week, less than daily; daily low-dose inhaled corticosteroids and short-acting β -agonist as needed
Moderate persistent	Daily symptoms or daily use of short-acting inhaled β -agonist; moderate-dose inhaled corticosteroids and long-acting β -agonist with short-acting β -agonist as needed
Severe persistent	Frequent symptoms with limited physical activity; high-dose inhaled corticosteroids, long-acting β -agonist, short-acting β -agonist, consider oral steroid
What other measures are important in asthma treatment?	Patient education, pollen/dust control, avoidance of triggers. Treat associated conditions, especially sinusitis and GERD.

CASE 4

A 45-year-old male construction worker with a history of HTN, alcoholism, and chronic pancreatitis has been complaining of feeling short-winded over the last year and a half with wheezing and nonproductive hacking cough. It does not occur at any specific place or time and is not associated with substernal chest pain. A friend at the job site has been letting him use some inhaler, which has helped during working hours, but symptoms return by the next morning.

What disease do you suspect?	COPD
What major risk factor for COPD does he have?	Tobacco smoking (90% of cases) and male gender
What other risk factors are there?	α_1 -Antitrypsin (AAT) deficiency, family history, Caucasian ethnicity, and lower socioeconomic status
When should you suspect AAT deficiency?	When COPD occurs in a nonsmoker
Which 2 types of COPD are there?	Chronic bronchitis and emphysema
Which does he most likely have?	Emphysema, due to lack of productive cough
Define chronic bronchitis	Chronic productive cough for 3 months in each of 2 consecutive years after other causes of chronic cough have been excluded (a clinical diagnosis)
Define emphysema	Abnormal permanent enlargement of the airspaces distal to the terminal bronchioles, accompanied by destruction of their walls and without fibrosis (a pathologic diagnosis)
What are common PE findings in	
Mild disease?	Barrel chest, hyperresonant lungs, decreased breath sounds, prolonged expiration, distant heart sounds, wheezes
Severe disease?	Cachexia, pursed lip breathing, accessory muscle use, cyanosis, accentuated P2 heart sound, and peripheral edema
What basic tests should be included in the initial workup?	CXR and PFT

What are the associated CXR findings in COPD?

Low and flat diaphragms, bullae, increased retrosternal lucency, narrow heart shadow, and attenuation of lung markings; prominence of hilae and right ventricle in pulmonary HTN

What are the associated PFT findings?

Reduced FEV₁/FVC, elevated total lung and functional residual capacities, increased residual volume, reduced diffusion capacity. Bronchodilator responsiveness is seen in 30%.

When would you consider ordering a CT scan?

Concern for underlying lung cancer secondary to strong smoking history or trying to characterize type of emphysema

Which type of emphysema on CT is more common in smokers?

Centrilobular emphysema, which begins in the respiratory bronchioles, spreads peripherally, and involves upper lobes

Which type of emphysema on CT is more common with AAT deficiency?

Panacinar emphysema, which involves the entire alveolus, and predominates in lower lobes

What's the treatment?

Smoking cessation counseling, ipratropium (an anticholinergic agent), and sympathomimetic β -2 agonists (e.g., albuterol, salmeterol)

What preventive measures are important in COPD?

Pneumococcal vaccine and yearly influenza vaccinations

When is supplemental oxygen therapy warranted?

Hypoxemic patients (improves dyspnea and survival)

What additional treatment options exist if deficient in AAT?

AAT supplementation

CASE 5

A 47-year-old male is referred to your clinic after being worked up by his primary care physician for slowly progressive dyspnea over the last year with a nonproductive cough. He has been ruled out for common disorders such as asthma, COPD, heart failure, and psychiatric disease as possible causes. The referring doctor also completed an extensive workup for causes of ILD such as sarcoidosis, occupational exposure, infection, radiation, drugs, and collagen vascular diseases and came up negative. The primary doctor suspects he may have IPF.

What is ILD?	A heterogenous group of lung diseases characterized by inflammation and fibrosis of the interalveolar septum
Why does the doctor suspect IPF?	A middle-aged patient with insidious onset of dyspnea on exertion with a persistent nonproductive cough is characteristic of IPF.
What's your first step in the workup?	Confirm by history, physical exam, and review of the medical record that sarcoidosis, occupational exposure, infection, radiation, drugs, and collagen vascular diseases are unlikely causes of his presumed ILD.
What signs on physical exam support the diagnosis of ILD?	Bibasilar end-inspiratory (velcro-like) crackles and clubbing of the digits
What tests should be ordered in the workup of IPF?	ABG, PFT, CXR followed by CT of chest
What are the associated findings on ABG?	Mild respiratory alkalosis with a normal or reduced PO_2
PFT?	Restrictive pattern, reduced lung compliance, and decreased DLCO

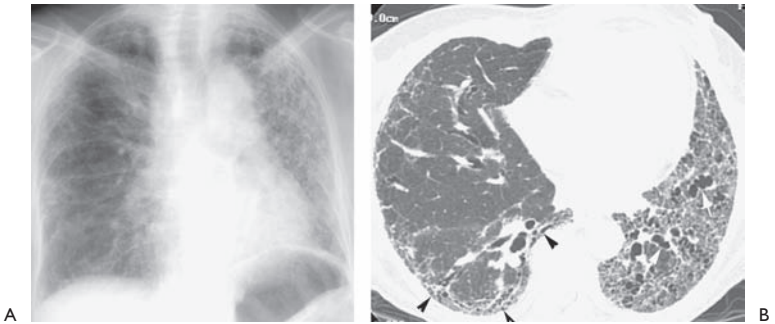


Figure 2-2.

(From Crapo JD, Glassroth J, Karlinsky JB, et al. *Baum's Textbook of Pulmonary Diseases*. 7th Ed. Philadelphia: Lippincott Williams & Wilkins, 2004.)

Describe the classic CXR and thoracic CT scan findings for IPF shown in Figure 2-2?

Diffuse bilateral reticular infiltrates, predominantly at bases with honeycombing on CT scan suggestive of end-stage disease

What procedure should confirm the diagnosis?

Bronchoscopy with transbronchial biopsy to rule out more common disorders (i.e., sarcoidosis); open-lung biopsy for definitive diagnosis

What are the treatment options for IPF?

Corticosteroids, cytotoxic therapy (cyclophosphamide or azathioprine) followed by lung transplant if medical therapy fails

CASE 6

A 55-year-old recently retired male with history of arthritis secondary to being overworked at the maintenance department at an old steel factory comes to your office for the first time after his insurance was changed. His medical charts from his prior MD were faxed and included recent comprehensive blood work, screening colonoscopy, prostate-specific antigen (PSA), and stress test. The patient said the stress test, which was normal, was done for a workup of gradual onset of shortness of breath and a nonproductive cough over the last few years. His last doctor did not suspect lung disease as he has been a nonsmoker.

What do you suspect?	ILD
What are the causes?	Idiopathic (a diagnosis of exclusion), sarcoidosis, occupational exposure, infection, radiation, drugs, collagen vascular diseases
Which do you suspect in this patient?	Occupational exposure to inorganic dusts at work
Why?	Insidious onset of dyspnea and nonproductive cough, usually >20–25 years after occupational exposure, is consistent with the diagnosis.
What inorganic dusts could he have been exposed to?	Asbestos (steel workers), silica (sandblasting)
What other inorganic dust exposure is less likely in his case?	Coal dust (coal miners)
What findings on physical exam would support the diagnosis of ILD?	Bibasilar end-inspiratory (velcro-like) crackles and clubbing of the digits
Are routine lab tests helpful in making a diagnosis?	No, they are often nonspecific and unhelpful
What basic lung function test is helpful?	PFT
What findings do you expect?	Restrictive pattern with reduced lung compliance, and decreased DLCO
Is a CXR helpful?	Yes. It may reveal a radiographic pattern consistent with either asbestosis or silicosis.
What radiographic findings of asbestosis are depicted in Figure 2–3?	
CXR	Bilateral pleural thickening, with blunting of both costophrenic sulci, and lobulated thickening along both lateral chest walls owing to pleural plaques

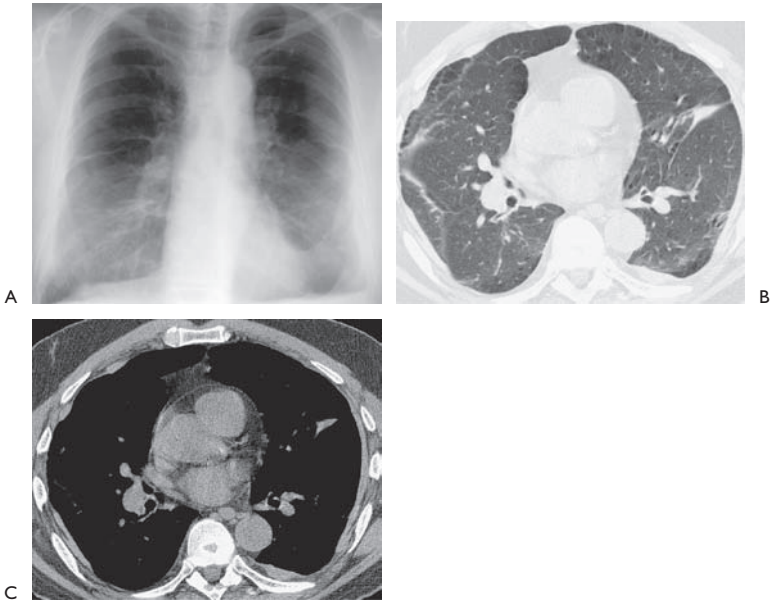


Figure 2-3.

(From Crapo JD, Glassroth J, Karlinsky JB, et al. *Baum's Textbook of Pulmonary Diseases*. 7th Ed. Philadelphia: Lippincott Williams & Wilkins, 2004.)

CT SCAN

Coarse parenchymal bandlike scarring;
asbestos-related pleural thickening

What radiographic findings of silicosis are depicted in Figure 2-4?

Multiple small nodules (usually upper lobe predominance) and calcification of the hilar lymph nodes

How is the diagnosis often made in ILD secondary to asbestosis or silicosis?

History of exposure, radiographic findings, and exclusion of other causes

What additional invasive procedure may be useful in diagnosing asbestosis?

Bronchoscopic identification of asbestos fibers or bodies in BAL fluid or in biopsy tissue specimens with histologic evidence of fibrosis

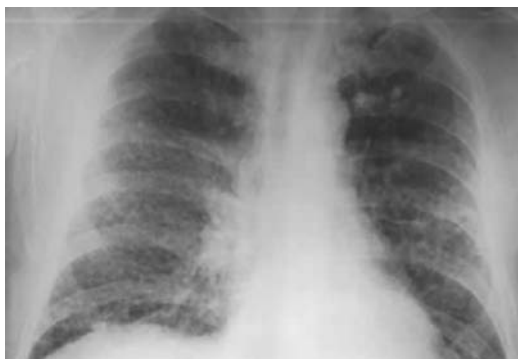

Figure 2–4. The chest radiograph shows a widened mediastinum from traumatic rupture of the aorta. (From Fleisher GR, Ludwig S, Baskin MN. Atlas of Pediatric Emergency Medicine. Philadelphia: Lippincott Williams & Wilkins, 2004.)

Is it required to make the diagnosis? No

What is the treatment of inorganic dust ILD secondary to asbestosis and silicosis? Prevention of infections (influenza, pneumococcal vaccines), smoking cessation, oxygen when needed

What infection is associated with silicosis? TB

CASE 7

A 66-year-old previously healthy male recently retired from the military with a normal annual physical examination, screening lab test, and procedures appropriate for his age prior to his discharge. Since retiring, he has been helping his brother at his newly purchased farm. But recently he has been unable to help because by midday, after arriving early in the morning, he feels febrile, gets short of breath, and has a persistent cough. Each day for the last week his symptoms recur, but clear by the time he wakes up at his home the next morning.

What is his presentation consistent with? A form of organic dust exposure causing a form of ILD (a.k.a., hypersensitivity pneumonitis)

What are 2 common occupations associated with organic dusts that cause ILD?

Farming (thermophilic actinomyces, fungal species) and bird breeding (avian proteins)

How does organic dust ILD (or hypersensitivity pneumonitis) present?

Acute onset of fever, cough, dyspnea 3–6 hours after inhaling dust with improvement in 24 hours if no repeated exposure. Can progress to chronic dyspnea and fatigue with repeated dust exposure.

What CXR findings are associated with hypersensitivity pneumonitis?

Interstitial and alveolar infiltrates, predominantly lower lobes, often fleeting. Fibrosis and honeycombing in chronic disease.

How is the diagnosis made?

Careful occupational or hobby history in a patient with ILD. Symptom-free periods outside of job/hobby suggest hypersensitivity pneumonitis.

What is the treatment of hypersensitivity pneumonitis?

Avoid exposures to the offending dust; use of steroids in chronic disease

MISCELLANEOUS DISORDERS

CASE 8

A 45-year-old male with unknown medical history presents to the emergency department (ED) by ambulance after being found with labored breathing on the street. EMS informs you that his airway is patent, respirations have decreased to 25 after being administered supplemental oxygen, remaining vital signs are normal, and EKG is normal. The cardiology fellow has already evaluated the patient and informs you that it's not his heart.

After examining the patient, what 2 lab tests will be helpful in determining the cause?

ABG (assess for hypoxic or hypercapnic state) and CXR

What's the diagnosis if PaO_2 is <55 mm Hg?

Hypoxemic respiratory failure

What if PaCO_2 is >45 mm Hg?	Hypercapnic respiratory failure
What's your differential for hypoxemic respiratory failure?	Pneumonia, ARDS, congestive heart failure
What's your differential for hypercapnic failure?	Drug overdose (particularly narcotics, benzodiazepines), stroke, asthma, COPD exacerbations, amyotrophic lateral sclerosis, myasthenia gravis, disorders of the muscles (muscular dystrophy)
What is the treatment?	Establish and maintain patent airway, administer supplemental oxygen, maintain adequate alveolar ventilation, and treat underlying cause

CASE 9

A 68-year-old male with history of HTN, hyperlipidemia, and CAD admitted with a non-ST elevation MI 4 days ago, status post urgent CABG after heart catheterization revealed significant 2-vessel CAD, develops profound respiratory distress with oxygen desaturation requiring intubation after enteral tube feed was started to maintain his caloric requirements.

What's your differential diagnosis?	Pulmonary edema secondary to transient myocardial ischemia or cardiomyopathy, mitral valve rupture, alveolar hemorrhage, and ARDS
What STAT labs and tests would be useful?	Chem 8, CBC, ABG, CXR, EKG, and echocardiogram
Results are as follows: ABG, acute respiratory alkalosis with low oxygen and carbon dioxide; CXR, diffuse bilateral alveolar infiltrates; EKG and echo, no change from prior studies. What's the most likely diagnosis?	ARDS
What are common causes of ARDS?	Sepsis, aspiration of gastric content, pneumonia, and trauma with burns or shock requiring multiple transfusions

What is the mechanism of ARDS?

Vascular injury and cytokine release

What is the treatment of ARDS?

Supportive care (mechanical ventilation with PEEP to maintain adequate oxygenation, nutritional support, avoidance of nosocomial infection, antibiotics when indicated, low IVF to decrease risk of pulmonary edema)

CASE 10

A 44-year-old male presents to your office with complaints of coughing up a few cups of blood over the last week. On exam, you are impressed by his cachectic appearance, alcohol on his breath, and pack of cigarettes rolled up in his sleeve. Otherwise, his vital signs and heart and lung exams appear normal.

What is this patient's problem?

Hemoptysis

Is it massive?

No, that would be 600 mL of blood in 24 hours or unstable vital signs.

What are the most common causes of hemoptysis?

Bronchitis, bronchiectasis, lung cancer, pneumonia, TB, aspergilloma, lung abscesses, septic emboli

What do you suspect this patient has?

Lung cancer

Why?

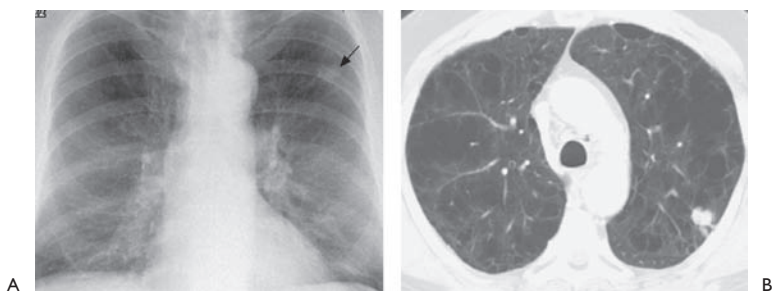
Cachectic appearance is consistent with malignancy, and patient is a smoker, which is the number one risk factor for lung cancer.

What laboratory tests can be performed?

CBC with platelet count and cell differential, renal and liver function tests (LFTs), PT/PTT, sputum for culture, cytology

Which diagnostic procedures should be performed first?

CXR, possibly with a CT scan

**Figure 2-5.**

(From Crapo JD, Glassroth J, Karlinsky JB, et al. *Baum's Textbook of Pulmonary Diseases*. 7th Ed. Philadelphia: Lippincott Williams & Wilkins, 2004.)

Does the CXR and CT scan in Figure 2-5 support your suspicion of lung cancer?

Yes, the CXR and CT scan reveal a solitary LUL nodule and the CT shows extension to the pleura.

What other diagnostic tests may be helpful?

Bronchoscopy

How is mild hemoptysis treated?

Control of cough. Reverse coagulopathy if present. Treat underlying disease.

Which invasive procedures can be performed to treat hemoptysis?

Bronchoscopy with topical epinephrine, balloon tamponade, cautery; bronchial arteriographic embolization; surgical resection

CASE 11

A 62-year-old male presents to your clinic complaining of chest discomfort and shortness of breath. On physical examination, you find decreased tactile fremitus, dullness to percussion, and decreased breath sounds at the left lung base. You obtain an EKG, CXR, and basic labs. Results are unremarkable except for dullness of the right costophrenic angle.

What are these findings consistent with?

Pleural effusion

How much fluid must accumulate before it can be noticed?

At least 10–20 mL of fluid in the pleural space

What imaging test will you order next?

Lateral and decubitus x-ray to determine if it is free flowing

Are the CXR findings in Figure 2–6 consistent with a pleural effusion?

Yes, blunted costophrenic angle on left and free layering fluid on the decubitus film

What serum biochemistries should be ordered?

Total protein, LDH, glucose, triglycerides, and amylase

What diagnostic procedure should be done?

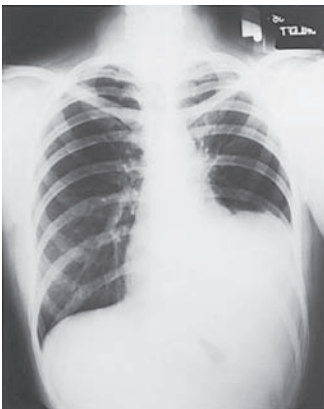Diagnostic thoracentesis to obtain pleural fluid for analysis

Why?

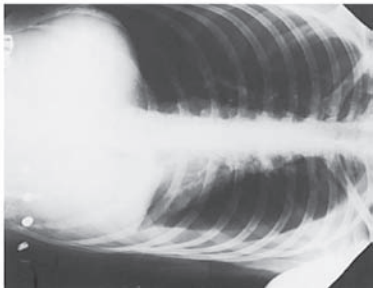
Results will narrow the differential of potential causes to transudates and exudates.

What tests should be performed on aspirated pleural fluid?

pH, LDH, protein, glucose, triglycerides, amylase, Gram stain, culture. AFB stain and mycobacterium culture if TB suspected. Cytology if malignancy suspected.



A



B

Figure 2–6.

(From Crapo JD, Glassroth J, Karlinsky JB, et al. *Baum's Textbook of Pulmonary Diseases*. 7th Ed. Philadelphia: Lippincott Williams & Wilkins, 2004.)

How are transudative and exudative effusions differentiated?

A pleural effusion is exudative if one of the following is present: pleural/serum protein >0.5 , pleural/serum LDH >0.6 , pleural LDH $>2/3$ upper limits of normal serum LDH.

What are the causes of transudate?

Congestive cardiac failure from any cause, hepatic cirrhosis, nephrotic syndrome, hypoalbuminemia, overhydration

What are the causes of exudative pleural effusion?

Infection, malignancy, pancreatitis, collagen vascular diseases, chylothorax, trauma, pulmonary embolism, drugs, chemical and irradiation injury

What other lab tests should be performed if exudative effusion is suspected?

White blood cell count, blood culture, erythrocyte sedimentation rate (ESR), serum antinuclear antibody level, PPD skin test

What is the treatment for pleural effusions?

Treat underlying cause, consider chest tube if effusion continues to expand or fluid is infected.

CASE 12

A 65-year-old male with history of HTN and aortic stenosis presents to your clinic after complaints of becoming short of breath while breathing fast after climbing a flight of stairs at a college football game. On exam you note basilar rales and faint wheezing without use of accessory respiratory muscles.

What do the symptoms and signs suggest?

Pulmonary edema

What is his risk factor for pulmonary edema?

Aortic stenosis

What else can cause it?

Left ventricular failure, MI, other valvular heart disease, arrhythmias, hypertensive crisis, volume overload, and ARDS

What should be included in the workup?

Chem 8, cardiac enzymes (rule out MI), CXR, ABG, EKG, and echocardiogram

How is it diagnosed?	CXR revealing diffuse bilateral interstitial and perihilar vascular engorgement, Kerley B lines (interlobar fluid and fibrosis), and possible pleural effusions
What is the treatment?	Correct underlying cause, diuretics (furosemide) and oxygen

CASE 13

A 30-year-old African-American female returns to your clinic for follow-up of fatigue, malaise, mild dyspnea, and a dry cough that gradually developed over the last few months. Her symptoms have not significantly improved and her physical exam is still significant for tender red nodules on the tibia. The CXR from last week reveals bilateral hilar adenopathy.

What are you concerned about?	Sarcoidosis
What were the clues?	African American (increased prevalence), tender red nodules on shin (consistent with erythema nodosum), and bilateral hilar adenopathy
What other systemic clues could be presented to you?	
Eye and nervous system	Uveitis, optic nerve dysfunction, Bell's (7th nerve) palsy
Cardiac	Cardiomyopathy, ventricular arrhythmias (including sudden death)
What other organs can be involved?	Joints (migratory arthralgias and arthritis)
What labs should be ordered?	CMP, CBC, ACE level, ESR
What lab abnormalities may be present?	Mild lymphocytopenia, increased ACE and ESR, increased total protein (due to hypergammaglobulinemia)

What PFT findings support the diagnosis?

A restrictive pattern (decreased FEV₁, FVC, TLC, and DLCO) is the most frequent. Can also show an obstructive pattern with a decreased FEV₁/FVC ratio.

How is the diagnosis made?

Biopsy confirmation of noncaseating granulomas in affected organs (usually lung or skin). Other infectious or malignant causes must be ruled out.

What's the treatment?

Supportive at first because most cases spontaneously improve

What if symptoms persist for 2–3 months?

Prednisone taper

CASE 14

A 47-year-old male with history of chronic bronchitis secondary to 20 pack years smoking and ESRD secondary to HTN and diabetes presents to your clinic after a 3.5-cm solitary lung nodule shown in Figure 2–7 was found during routine tests for his kidney transplant evaluation.

What is the basic differential for causes of solitary pulmonary nodule?

Lung cancer (primary or metastatic), infectious and inflammatory

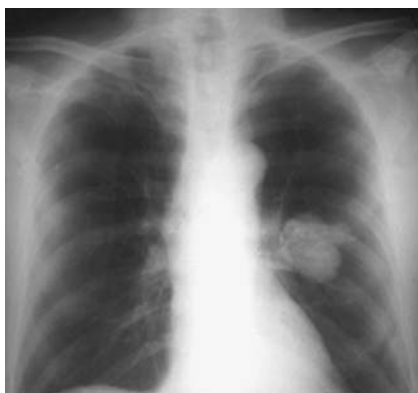

Figure 2–7. Solitary lung nodule.

What cause do you suspect in this patient?	Primary lung cancer
What clinical factors presented suggest a malignant solitary pulmonary nodule?	Older age, smoking history, size over 3 cm
What radiographic features suggest	
Benign etiology?	Diffuse, central, laminated, or “popcorn” calcifications and stability of the size of the lesion over a period of at least 2 years
Malignancy?	Irregular contour
What is the first step in the evaluation?	Review old CXR to determine if this is a new lesion or old and stable process.
What diagnostic procedures are available?	CT-guided needle biopsy, fiberoptic bronchoscopy (washings and brushings for cytology and transbronchial biopsy)
What is the treatment?	
Benign	Follow with serial CXR to document stable lesion (not growing)
Malignant	Oncology and surgical consults to assess surgical, chemotherapeutic, and radiation-based therapies

CASE 15

A 38-year-old postpartum female with history of obesity, asthma, smoking, HTN, hyperlipidemia, and DJD develops rapid onset of shortness of breath following a cross-country airline flight to visit her aging parents with her new baby. While pulling bags down from the overhead compartment she became breathless with rapid heart rate and breathing rate.

What differential are you considering?	MI, pneumothorax, PE, CHF, anxiety disorder with hyperventilation, asthma
---	---

Which is most likely and why?	PE, due to the acute symptoms onset and multiple risk factors present
What causes a PE?	Blockage of a branch of the pulmonary artery by an embolus, often from a large vein, causing increased pulmonary artery pressure and right ventricular strain
What symptoms and signs are suggestive of PE?	In descending order of frequency: dyspnea, tachypnea, tachycardia, chest pain, cough, syncope, hemoptysis
What risk factors for PE does she have?	Postpartum and probable oral contraceptive use (most postpartum women are put on birth control by their ob-gyns), immobilized (plane ride), obesity, smoker
What additional risk factors exist?	Advanced age, pregnancy, recent surgery, trauma, indwelling central venous catheter, cancer, coagulopathies
What are the most common coagulopathies known to predispose to deep venous thrombosis?	Activated protein C resistance (factor V Leiden), protein C deficiency, protein S deficiency, antithrombin III deficiency, plasminogen deficiency
Where do pulmonary emboli commonly come from?	Pelvic veins or deep veins of the legs
What's the first step in managing this patient?	Stabilize patient's vital signs by following basic ABCs (airway, breathing, and circulation) of cardiopulmonary resuscitation
What initial tests should you order?	Basic labs (chem 8, CBC, PT/PTT/INR), EKG, cardiac enzymes (Ck-MB and troponin), and ABG
What one lab test can be ordered to help exclude PE from the differential diagnosis (high negative predictive value)?	Negative plasma D-dimer by ELISA (it is positive in roughly 90% of patients with PE)

Would this be helpful in this patient?

Probably not; she recently delivered a baby and likely has endogenous fibrinolysis occurring from that.

So, when is the D-dimer test most helpful?

In ruling out PE when your pretest probability is low

What may be found on ABC in PE?

Increased alveolar–arterial oxygen gradient (measures difference in oxygen concentration between alveoli and arterial blood) and hypoxia (low PaO_2)

What findings on the EKG suggest PE?

New EKG changes of right ventricular strain with large S waves in leads I and aVL, QS waves in leads III and aVF, T wave inversions in leads III and aVF or V_1 through V_4

What findings on CXR may be found days later suggesting prior PE?

A peripheral wedge-shaped density (Hampton's hump) secondary to pulmonary infarction from a pulmonary embolus

What ultrasound test can support the diagnosis of PE?

Lower extremity Doppler US revealing a LE DVT

What radiographic tests are commonly used to diagnose PE?

V/Q scan (ventilation/perfusion scan) and spiral CT

What does the V/Q scan do?

Shows areas that are ventilated but not perfused

What is the gold standard diagnostic test?

Pulmonary angiography

What's the treatment for PE?

Supportive care and anticoagulation (IV heparin or LMWH followed by coumadin to keep INR between 2 and 3 for at least 3 months)

What additional treatment may be required in massive PE?

Thrombolysis or pulmonary embolectomy

CASE 16

A 17-year-old tall, thin male presents to the ER from school with splinting to his left side complaining of acute onset of dyspnea following smoking a cigarette after lunch. He says his right chest is killing him and wants some pain medication.

What's your differential diagnosis?	Pneumothorax, pleurisy, PE, MI, pericarditis, asthma, pneumonia
Which is most likely?	Pneumothorax based on his presentation and risk factors
What is a pneumothorax?	Accumulation of air in the pleural space with secondary lung collapse
What is characteristic of pneumothorax?	
Symptoms	Acute onset of dyspnea and chest pain (acute, localized to one side, usually pleuritic)
Signs	Tachycardia, tachypnea
What physical exam findings would support your diagnosis?	Absent tactile fremitus, hyperresonance, and decreased breath sounds on affected side (his left side)
What are his risk factors for primary spontaneous pneumothorax?	Male sex, tobacco use, tall and thin body habitus
What are some secondary causes of pneumothorax (not suspected in this patient)?	COPD, cystic fibrosis, HIV/AIDS, trauma, invasive procedures (central line placement, thoracentesis), mechanical ventilation
What tests should you order?	CXR and ABG
What results do you suspect on ABG?	Hypoxemia and hypocapnia (secondary to hyperventilation)

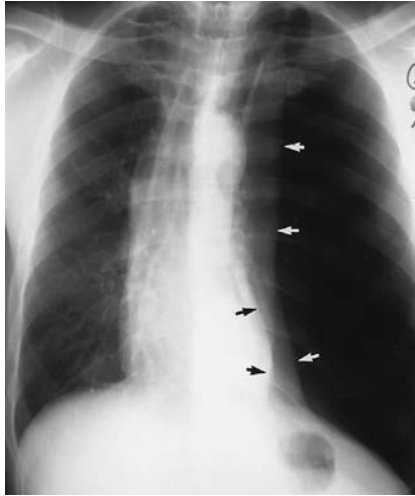


Figure 2–8.

(From Sgarbossa EB, Wagner GS. Electrocardiography. In: Topol EJ, ed. Textbook of Cardiovascular Medicine. 3rd Ed. Philadelphia: Lippincott Williams & Wilkins, 2006.)

Does your CXR in Figure 2–8 support pneumothorax

Yes

Describe the findings

A pleural line with absence of vessel markings peripheral to this line on the affected side (left)

What test would you order if basic CXR was negative and you still suspected acute pneumothorax?

CT of chest

Describe the CT findings shown in Figure 2–9.

Large collection of free air on the left with shifted mediastinum to left and collapsed lung (*arrows*)

What is the usual treatment of pneumothorax?

Aspiration of air using small IV catheter in second intercostal space in the midclavicular line connected to a large syringe; 100% oxygen. Follow with serial CXR to document resolution.

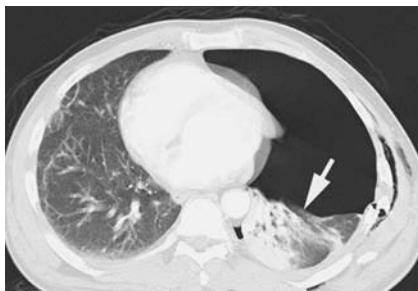

Figure 2–9. Tension pneumothorax as demonstrated on CT. (From Daffner RH. Clinical Radiology The Essentials, 3rd Edition. Philadelphia: Lippincott Williams & Wilkins, 2007.)

When can a pneumothorax be observed?	Asymptomatic patients with small pneumothorax (<15%) with evidence that the leak has sealed
When is pleurodesis indicated?	Recurrent primary spontaneous pneumothorax. Consider use in patients with COPD and HIV.
When is surgery indicated?	Persistent air leak, incomplete expansion of lung
What complication would you suspect if the patient developed labored breathing, diaphoresis, cyanosis, distended neck veins, tracheal deviations, subcutaneous emphysema?	Tension pneumothorax
What's the physics behind a tension pneumothorax?	Pleural pressure exceeds atmospheric pressure throughout expiration leading to compression of the mediastinum (heart and great vessels)
When is a tension pneumothorax most likely to occur?	After trauma or during mechanical ventilation

Why is a tension pneumothorax feared?

Because it is associated with severe respiratory distress and hypotension

What is the treatment?

Prompt aspiration of air with a large-bore needle

CASE 17

A 30-year-old male presents to the ER after falling off his horse onto a tree stump. He becomes acutely short of breath and is splinting to his right side in excruciating pain. During inspiration, there is paradoxical inward movement of the flail segment, with outward movement of the segment during expiration.

What diagnosis is associated with this paradoxical chest wall motion?

Flail chest

What risk factor is associated with it?

Blunt trauma to the chest (like falling off a horse onto a tree stump)

Why does the paradoxical motion occur?

A segmental fracture (fractures in 2 or more locations on the same rib) of 3 or more adjacent ribs resulting in an unstable portion of the chest wall. Most often occurs anteriorly or laterally.

Other than paradoxical motion, what other physical exam findings do you expect?

Bony crepitus and tenderness

What basic imaging test should you order to support your diagnosis?

CXR

What is the appearance of the chest radiograph in a patient with flail chest?

The fractured rib segments should be apparent, and there may be associated hemothorax or pneumothorax. Pulmonary contusion may be evident 6 hours after injury and appears as opacification of areas of the lung.

How is it diagnosed?

Physical exam

What is the initial treatment of flail chest?	Supplemental oxygen and analgesia
What if severe hypoxemia or respiratory distress occurs?	Mechanical ventilation
Is surgical fixation of the ribs required?	Rarely. Supportive treatment in the form of analgesia, supplemental oxygen, and mechanical ventilation as necessary are the mainstays of therapy.
While hospitalized, he develops unilateral decreased breath sounds and dullness to chest percussion. What complication of flail chest do you suspect?	Hemothorax
What is a hemothorax?	An accumulation of blood in one or both hemithoraces
What is the cause of hemothorax?	It is most often the result of penetrating chest trauma that disrupts systemic or hilar vessels, but may also occur as a result of blunt trauma.
What lab tests should you order?	CBC, PT, PTT, and INR
What imaging test would help support the diagnosis?	CXR
In what position should the patient be for the CXR?	Upright or decubitus
Why?	While an upright or decubitus chest radiograph may detect as little as 200–300 mL of fluid collection, as much as 1 L of fluid in the chest may be missed on a supine film.
What is the treatment for a hemothorax?	A tube thoracostomy (chest tube)

CASE 18

A 64-year-old male with history of HTM, DJD, BPH, and mitral valve prolapse presents to the ER after falling off his bike. He has been exercising for months, but lately has lost more weight than usual (30 lb in 6 weeks) and has been easily fatigued within a mile of his ride. Other than some unsteadiness on his feet, productive cough that is infrequently bloody, and new thigh pain, he feels okay. CXR reveals hazy density in the hilum. (Figure 2–10)

What's your differential diagnosis?

Lung cancer, metastatic cancer, hamartoma, and granuloma (tuberculosis or fungal)

What social history question is important to ask?

Smoking history

Why?

Elderly male presenting with weight loss, hemoptysis, fatigue, and new neurologic complaints and bone pain is concerning for metastatic lung cancer, and smoking causes more than 90% of all lung cancers.

What other general symptoms of cancer should you ask about?

Fever and weakness

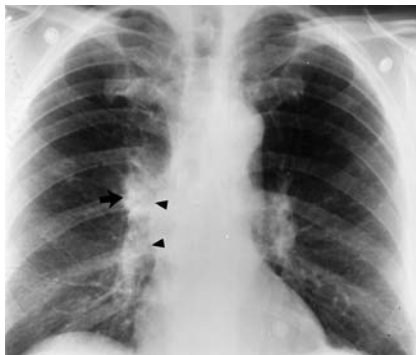


Figure 2–10.

(From Daffner RH. Clinical Radiology The Essentials, 3rd Edition. Philadelphia: Lippincott Williams & Wilkins, 2007.)

What additional respiratory signs and symptoms should you ask about?

Dyspnea, chest pain, wheezing, stridor, hoarseness, and pleural effusion

What metastatic symptom does he present with?

Neurologic abnormalities (he is unsteady on his feet) and bone pain

What basic lab tests should you order and why?

CBC (look for anemia suggesting bone metastasis), LFT, PT, PTT, and platelet count (abnormalities suggest liver metastasis and need normal values if planning a biopsy in future)

What additional radiographic tests should you order and why?

CT scan of the chest (helps to define lung density and with cancer staging), CT of head (assess for metastatic lesions due to neurologic symptoms), and bone scan (due to new thigh pain suspicious for bony mets)

CT of chest defines central lung mass and CT of head and bone scan have findings consistent with metastatic disease. What types of lung cancer present centrally on CXR and CT?

Squamous cell carcinoma and small cell (oat cell) carcinoma

Of the 2, which is more likely in this patient?

Small cell due to rapidly growing and virulent presentation

Which lung tumors are peripherally located on the CXR?

Adenocarcinoma and large cell carcinoma

How will you make your diagnosis?

Lung biopsy

What biopsy procedures will the surgeons and interventional radiologists commonly use to obtain the lung tissue?

Transbronchial biopsy, fine needle aspiration biopsy, thoracentesis, and thoracotomy

Biopsy tissue confirms small cell cancer of the lung. What's the treatment?

Chemotherapy, radiotherapy, immunotherapy, and pain relief when applicable

When is surgery indicated?

In non-small cell lung cancer when chance of curative resection exists

What paraneoplastic syndrome may develop from this patient's small cell carcinoma?

Syndromes characterized by ACTH-like or antidiuretic hormone-like activity

UPPER GI BLEEDING

CASE 1

A 68-year-old male with history of gout, rheumatoid arthritis, CAD, s/p CABG 2 years ago, and AAA repair 4 years ago presents to your office complaining of progressive darkening of stool over last 3 weeks, 1 episode of vomiting with trace amount of bright red blood this morning, and mild shortness of breath (SOB) with exertion.

What's a reasonable differential diagnosis?

PUD, AVMs, aortoenteric fistula

Which is most important to rule out in this patient?

Aortoenteric fistula

Why?

Often the mild “sentinel,” non-exsanguinating initial bleed, with blood per rectum (melena or hematochezia and hematemesis or with chronic intermittent bleeding) followed by a massive life-threatening hemorrhage

What causes it?

A fistula that forms after 2% of abdominal aortic grafts and is located usually between the upper portion of the aortic graft and the distal duodenum

What key risk factor did this patient have?

History of AAA repair (4 years ago on average)

What basic tests should be ordered first?

CBC, PT and international normalized ratio (INR), EKG, CXR, hemocult of stool, nasogastric (NG) lavage

Hg 8, MCV 88, heme-positive stool, negative NG lavage, CXR, EKG, and PT and INR. What test should be ordered next to rule out aortoenteric fistula?

Upper endoscopy

What if endoscopy is not available?

Angiography or abdominal CT scanning

Upper endoscopy confirms the diagnosis of aortoenteric fistula. What is the treatment strategy?

STAT surgical consult, transfuse with packed red blood cells (PRBC), serial Hg/HCT, IV fluids, and antibiotics

How can you explain the negative NG lavage?

A clot formed within the fistula

CASE 2

A 73-year-old male with history of HTN, DJD, macular degeneration, and AS presents to your clinic complaining of dark black sticky stools on and off for the last 2 months.

What's a reasonable differential diagnosis?

Aortoenteric fistula, angiodysplasia, PUD, gastric cancer

Does the patient's history of AS help narrow your differential diagnosis?

Yes, AS is associated with AVM.

Name additional risk factors for AVMs.

Age, chronic renal failure, hereditary hemorrhagic telangiectasia, von Willebrand disease, and scleroderma

What causes AVMs?

Abnormal arteriovenous communication that is hypothesized to arise from chronic intestinal muscular contractions obstructing venous mucosal drainage

What are some other less common ways patients with AVMs present?

Recurrent self-limited hematochezia or hematemesis that is not hemodynamically significant

Where do they most commonly occur?	Colon (cecum and ascending colon)
At what other locations may these be found in patients with chronic liver failure?	Stomach and duodenum
How is the diagnosis made?	Endoscopically
How is it treated?	Iron supplementation with monitoring of hemoglobin for response
How is it treated if actively bleeding?	Endoscopic coagulation
What additional medical therapy may decrease recurrent bleeds?	Combined estrogen and progesterone therapy

CASE 3

A 51-year-old previously healthy male presents to your clinic with 30-lb weight loss over last 4 months, progressive difficulty swallowing food, and trace amounts of blood in vomited food over the last few days. He has even been unable to swallow over-the-counter omeprazole (Prilosec) he takes for frequent longstanding heartburn.

What diagnosis do you suspect?	Esophageal cancer
Why?	Dysphagia, weight loss, vomiting, and hematemesis are characteristic of esophageal cancer.
What other symptoms may a patient present with?	Odynophagia, anorexia, cough, hoarseness, bone pain
What is the most important question to ask the patient?	“Do you drink alcohol and/or use tobacco products?”
Name the 2 most common types of esophageal cancer.	Squamous cell carcinoma and adenocarcinoma
Which is associated with ethyl alcohol (ETOH) and tobacco smoking?	Squamous cell carcinoma

What is associated with adenocarcinoma of the esophagus?

Barrett's esophagus from longstanding reflux disease

What is the best diagnostic test?

Endoscopy with biopsy

What other test may be considered if endoscopy is unavailable?

Barium esophagram

Based on the patient's barium esophagram and history, which cancer does he most likely have?

Adenocarcinoma from Barrett's esophagus (patient had longstanding GERD, major risk factor)

Describe the findings shown in Figure 3-1.

Mass at gastroesophageal junction with irregular margins (*curved arrows*), ulceration (*arrowhead*), and overhanging edges (*arrow*)

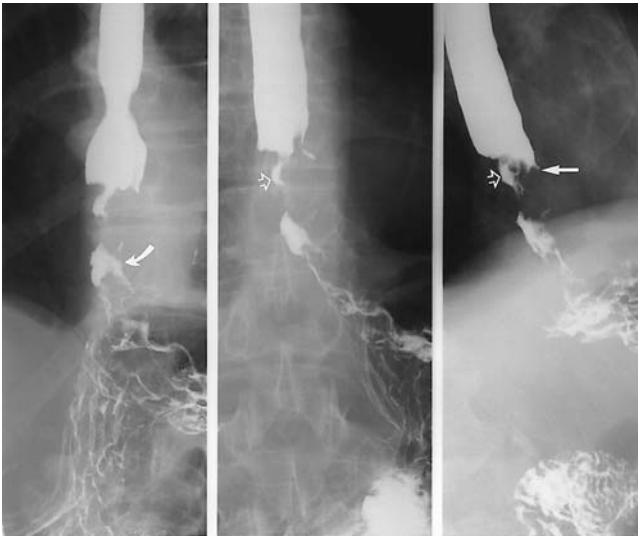


Figure 3-1.

(From Kelsen DP, Daly JM, Kern SE, et al. *Gastrointestinal Oncology: Principles and Practice*. Philadelphia: Lippincott Williams & Wilkins, 2002.)

Why is endoscopy preferred?

Can obtain tissue for diagnosis

What additional tests are performed for staging of the cancer?

Staging requires CT of chest and abdomen, supplemented by endoscopic ultrasound and bone scan.

CASE 4

A 62-year-old female with history of HTN, DM, DJD, asthma, GERD, and depression comes to the ER complaining of more frequent albuterol use for her asthma, hoarseness, and pain with swallowing.

What's your differential diagnosis?

Asthma exacerbation, GERD, esophagitis

Is there a way that all 3 could be present?

Yes

What additional history would be helpful?

Establishing a timeline of worsening reflux disease (heartburn, but can be asymptomatic), followed by more asthma attacks

In addition to heartburn, what other symptoms of reflux esophagitis may be present?

Regurgitation and water brash, which are aggravated on bending and lying down. Bleeding and dysphagia are seen owing to severe disease or complications.

Why does GERD occur?

Imbalance between the aggressive forces within the refluxate (acidic stomach contents) and the esophageal defenses constituted by the antireflux barriers, the luminal clearance mechanisms, and tissue resistance

What are the most common causes of esophagitis (other than GERD) and esophageal ulcers?

Radiation (history of thyroid cancer), pill induced, chemical injury (lye), and infections (often in immunocompromised hosts)

What's a reasonable diagnostic strategy?

Medical therapy first, followed by upper endoscopy or ambulatory 24-hour intraesophageal pH monitoring if therapeutic trial unsuccessful

What is the medical management of GERD?

Lifestyle modification followed by treatment with proton pump inhibitors for 8–12 weeks

CASE 5

A 44-year-old male with known hepatitis C and EtOH cirrhosis confirmed by recent liver biopsy, ascites, HTN, DJD, stomach ulcers, and pancreatitis comes by ambulance to your emergency department (ED) with 4 episodes of large quantity of bright red emesis over the last 3 hours and 1 recent episode of dark stool.

What's your differential diagnosis?

Esophageal varices, Mallory-Weiss tears, PUD

Which is most likely?

Esophageal varices

Why?

Patient has known cirrhosis of liver

What causes varices to develop?

When portal HTN develops in cirrhotics, extrahepatic collateral venous channels between portal and systemic circulation dilate and form varices, most often in the lower esophagus.

What's the first management step for this patient?

STAT labs [CBC, coags, Chem 8, liver function tests (LFTs)], stabilize patient with IVF and PRBC

What's the next step?

Upper endoscopy for diagnosis and treatment

What additional therapy is used to reduce portal pressures?

Octreotide

What if this management fails?

Order surgical consult for transjugular intrahepatic portosystemic shunt (TIPS) evaluation

After acute bleed is stabilized and patient is hemodynamically stable, what prophylactic medication is useful?

β -blockers (decrease portal pressure)

CASE 6

A 47-year-old African-American female with history of severe recurrent PUD presents to the ER with complaints of persistent and progressive abdominal pain, weight loss, and early satiety over the last 7 weeks. Prior to admission, her primary care physician diagnosed her with Helicobacter pylori stomach infection by a blood test.

What's a reasonable differential diagnosis?	Cancer (gastric, esophageal), PUD
Which is most likely?	Gastric cancer
Name some common presenting signs and symptoms of gastric cancer.	Weight loss, abdominal pain (often constant), dyspepsia, early satiety, anorexia, hematemesis, or melena
What risk factors does she have for gastric cancer?	Being African American and <i>H. pylori</i> infection
What additional risk factors are there for gastric cancer?	Family history, hereditary (Asian Americans, Hispanics), gastric polyps, and gastric surgery (Billroth II)
What lab tests would support your suspicion of gastric cancer?	Iron-deficient anemia (chronic blood loss), positive result of guaiac test (50%), and positive carcinoembryonic antigen (CEA)
Which abnormal lab result would raise suspicion of metastasis?	Abnormal liver chemistry tests
What basic imaging test would help support the diagnosis?	Upper GI series
Does the upper GI series shown in Figure 3-2 support the diagnosis of gastric cancer?	Yes
Describe the upper GI findings.	Mass (<i>arrows</i>) with central ulceration (<i>arrowhead</i>) with extension into gastric lumen

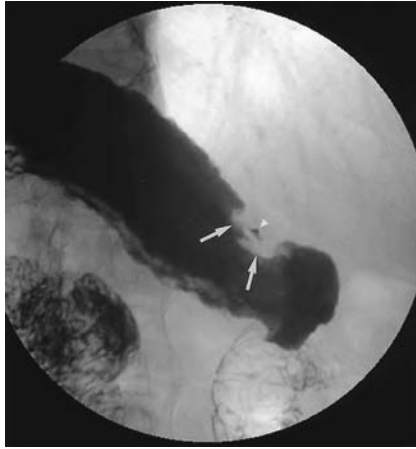

Figure 3–2.

(From Kelsen DP, Daly JM, Kern SE, et al. *Gastrointestinal Oncology: Principles and Practice*. Philadelphia: Lippincott Williams & Wilkins, 2002.)

What's the best test to make the diagnosis?

Upper endoscopy with biopsy

An upper endoscopy is performed; findings and biopsy results are consistent with gastric cancer. What histologic type of gastric cancer is most likely?

Adenocarcinoma (90–95%); others include leiomyosarcoma (common cause of massive UGI bleed) and lymphoma

What additional imaging should be ordered now?

Abdominal and chest CT for staging

What is the therapy?

Surgical resection for localized disease; chemotherapy and radiation may also be used as adjunctive and palliative therapy.

CASE 7

A 44-year-old female with history of HTN, diabetes, COPD, and chronic back pain controlled with ibuprofen was admitted to the hospital 7 days ago after a motor vehicle collision, with significant blood loss that required a splenectomy. She continues to be on the ventilator owing to difficulty in weaning as a result of underlying COPD. You are called to evaluate 2 episodes of coffee ground emesis.

What's a reasonable differential diagnosis?

Esophageal ulcers and esophagitis, hemorrhagic gastritis (HG), and PUD

Which do you suspect?

HG or PUD

What is HG?

Inflammatory hemorrhagic mucosal erosion in the stomach often caused by noxious chemical agents or physiologic stress eroding viable tissue

What is PUD?

A lesion in the gastric or duodenal mucosa that arises when normal mucosal defenses are impaired or are overwhelmed by aggressive luminal factors such as acid or pepsin

What risk factors does this patient have for HG and PUD?

NSAID use, physiologic stress of underlying illness

Name other risk factors for both HG and PUD.

Aspirin, NSAIDs, alcohol, physiologic stress, trauma (endoscopy, NGT)

How do they commonly present?

HG

Often asymptomatic, but may present with dyspepsia; mild cases present with epigastric pain, anorexia, nausea and vomiting; if severe (rare), hematemesis or coffee ground emesis, bloody aspirate in NGT, or melena

PUD

Gnawing/burning epigastric pain (duodenal ulcers are relieved by food while gastric often are not), hematemesis, melena, or coffee ground emesis

What's the first thing to do with this patient?	Determine how severe the bleeding is
What are some physical exam signs in cases of significant blood loss?	Pale, diaphoretic, tachycardia, hypotension and dizziness, melena, hematemesis, and orthostatic symptoms
What lab test is helpful?	Hematocrit (anemia), stool for occult blood or guaiac test
What bedside test helps determine if the patient is still actively bleeding?	NG lavage and aspirate looking for fresh blood (may be false-negative if bleed is post-pyloric)
What is the most sensitive diagnostic test?	Upper endoscopy
What else should be done during endoscopy?	Antral biopsy for <i>H. pylori</i>
What distinguishes the erosions seen in gastritis from those in PUD and HG?	Erosions in gastritis are less than 5 mm in diameter and do not extend through the muscularis mucosa.
What is the initial therapy in massive GI bleeds?	Stabilize the patient with fluid resuscitation and PRBC as needed; if bleeding continues consider intravenous vasopressin or endoscopic control. Surgical intervention may be required.
What additional treatment is required?	Antisecretory therapy (H_2 receptor antagonists or a proton pump inhibitor); treatment for <i>H. pylori</i> if present, may add sucralfate to therapy regimen, especially when NSAID or stress induced; discontinue alcohol and chronic NSAID use

CASE 8

A 22-year-old alcoholic is transferred by ambulance to the ER after being found on the grounds of a fraternity house with dried blood with food particles on his mouth and shirt. Friends told EMS personnel that he was not feeling well earlier and said he felt nauseous and he was going to get sick.

What is the most likely cause of the bleeding?

Mallory-Weiss tear

Why?

Classically, patients present after repeated, violent retching, vomiting, or coughing followed by hematemesis.

What is the cause?

Sudden rise in intra-abdominal pressure that produces a linear, nonpenetrating mucosal laceration at the gastroesophageal junction, resulting in bleeding

How is the diagnosis made?

Endoscopy is the preferred modality for diagnosis.

What are the treatment options?

Most stop bleeding spontaneously. If bleeding persists, endoscopic hemostasis can be attempted by injecting epinephrine or by cauterization.

LOWER GI BLEEDING

CASE 9

A 55-year-old female with history of ulcerative colitis, hepatitis C secondary to IVDA in her teens, and adenomatous colon polyps removed on a flexible sigmoidoscope 12 years ago presents with unexplained weight loss, LLQ abdominal pressure, fatigue and change in bowel habits, and trace amounts of blood on tissue paper. A barium enema taken yesterday is shown in Figure 3–3.

What diagnosis is most likely?

CRC

Why?

Recent change in bowel habits, abdominal pain, rectal bleeding, weight loss are concerning for CRC and abnormal barium enema

What classic finding of CRC is shown on the barium enema?

Apple core lesion that highly suggests a circumferential mass (*arrows*) from CRC

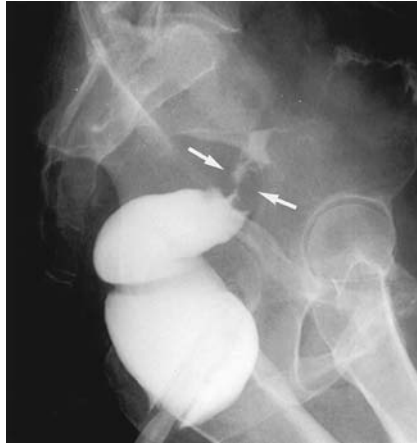


Figure 3–3.

(From Kelsen DP, Daly JM, Kern SE, et al. *Gastrointestinal Oncology: Principles and Practice*. Philadelphia: Lippincott Williams & Wilkins, 2002.)

What risk factor does she have for CRC?	Adenomatous polyps and ulcerative colitis
What additional risk factors are there?	Family history of colon cancer, other adenocarcinomas (breast, ovarian, etc.)
What does CRC most commonly arise from?	Adenomatous polyps (villous polyps are more often malignant than tubular polyps)
What physical exam clues may be found in CRC patients?	Pale skin and conjunctivae (anemia), palpable abdominal or rectal mass, blood on rectal exam, or heme-positive stool
What lab test result would support the diagnosis?	Iron-deficient anemia (microcytic anemia with low iron and ferritin and high total iron-binding capacity)
How is the diagnosis made?	Colonoscopy with biopsy
After the diagnosis is made, what additional radiographic studies are often performed?	CXR, bone scan (if patient complains of bone pain), and abdominal CT scan

What is the treatment?

Surgically resect cancer (if rectal cancer, consider preoperative radiation therapy), adjuvant therapy with 5-FU, and leucovorin may be used in locally advanced and metastatic cases.

CASE 10

A 62-year-old female with history of chronic constipation, type 2 diabetes, and psoriasis presents to the ED with 3 episodes of 300 cc of painless BRBPR since this morning.

What's your differential diagnosis?

Hemorrhoids, diverticulosis, and anal fissure

Which is most likely?

Diverticulosis

Why?

Painless rectal bleeding (large volume bright red to maroon blood) with chronic constipation or crampy postprandial pain in the LLQ, dark red stool common, possibly lightheadedness (if hemodynamically unstable) are characteristic of diverticulosis.

Why are hemorrhoids and anal fissure less likely?

Rarely do these conditions present with a large quantity of blood as seen in this patient.

What causes diverticulosis?

Pouchlike herniations through the muscular layer of the colon (usually sigmoid) around a diverticular arteriole, leading to BRBPR

What risk factors did this patient have for diverticulosis?

Age 60 or older and chronic constipation

What basic physical exam studies should be performed?

Check vital signs for orthostatics (assess degree of blood loss) and stool guaiac test

What laboratory tests should be ordered?

CBC, blood type and cross match test

What diagnostic studies should be ordered?	Proctosigmoidoscope or colonoscopy to identify bleeding as left sided and confirm that no other lesions are present
Can proctosigmoidoscope or colonoscopy reveal the source of the bleeding?	Usually not, because the bleeding tends to obscure the visual field
What is the therapy in hemodynamically stable patients?	Supportive (most bleeding spontaneously resolves) and high-fiber diet
What is the therapy in hemodynamically unstable patients?	Colonoscopy with angiographic control with intra-arterial vasopressin injection
What if bleeding recurs despite above measures?	Consider surgical resection

CASE 11

A 35-year-old overweight sedentary previously healthy male presents to your office complaining of scant amounts of bright red blood on the tissue paper and a slight red tinge to toilet bowel water. He also says when he wipes the skin it's bumpy and itches afterwards.

What differential diagnosis are you considering?	Hemorrhoids and anal fissure
Which is most likely?	Hemorrhoids due to "bumpy" description and anal pruritus (not found with anal fissure)
What causes hemorrhoids?	Swelling and dilatation of a blood vessel at the anus most likely caused by increased vascular pressure
What are the risk factors?	Straining at stool, constipation, prolonged sitting, CHF, portal HTN, pregnancy, obesity, and low-fiber diets
What might the rectal examination reveal?	Bluish tense lumps of skin that may be painful (external hemorrhoids are painful, whereas internal ones are not)

What diagnostic study is ordered?	Rectal exam and proctosigmoidoscopy to reveal red blood and bleeding hemorrhoid
What is the treatment strategy in	
Asymptomatic patients?	High-fiber diet, increase fluid intake, and physical activity
Symptomatic patients?	Sitz baths, topical itch and pain ointments, and oral analgesics if necessary
Severe cases unresponsive to medical therapy?	Banding, ligation, and cauterization

CASE 12

A 22-year-old female with 12-month history of intermittent crampy RLQ abdominal pain, loose, nonbloody stools, and 10-lb weight loss presents to the ER with worsening pain unresponsive to over-the-counter pain medications.

What differential are you considering before examining the patient?	Acute appendicitis, incarcerated hernia, inflammatory bowel disease, intestinal obstruction, ectopic pregnancy, ovarian cyst, torsion of ovarian cyst, salpingitis, tubo-ovarian abscess, kidney stone, and pyelonephritis
On physical exam you find normal vital signs but are impressed with bilateral red eyes, aphthous mouth ulcers, and RLQ tenderness. Does this narrow your differential?	Yes, the red eye (suggests possible iritis) and aphthous ulcers are extraintestinal manifestations of inflammatory bowel disease.
What other extraintestinal clues suggest inflammatory bowel disease?	Uveitis, arthritis, or erythema nodosum
What are the 2 inflammatory bowel diseases?	Crohn disease and ulcerative colitis

What symptoms may present in both?	Abdominal pain, weight loss, fever, chills, nausea, and vomiting
What are the characteristic symptoms of ulcerative colitis?	Bloody diarrhea (classic) with tenesmus
What is the classic symptom of Crohn disease?	Nonbloody diarrhea
Which is more likely here?	Crohn disease
Why?	RLQ (suggest possible terminal ileum involvement characteristic of Crohn disease) and nonbloody diarrhea suggest Crohn disease.
What basic labs should be ordered?	UA (rule out renal causes), B-Hcg (rule out pregnancy), Chem 8, CBC
What imaging test could be considered?	CT scan with PO and IV contrast looking for bowel-wall thickening suggestive of inflammation and underlying IBD
What diagnostic study is ordered?	Colonoscopy with biopsy and slit light exam (due to eye redness, rule out iritis)
What is the characteristic distribution in Crohn disease?	It can affect any region of the GI tract from the mouth to the anus with skip lesions with asymmetric ulceration, cobblestoning, and aphthous ulcers and does not usually affect the rectum. Affects the terminal ileum in 70% of cases.
What is the characteristic distribution in ulcerative colitis?	Usually starts in the rectum and spreads proximally in a symmetric and continuous fashion
Colonoscopy confirms terminal ileum involvement. What's your diagnosis?	Crohn disease
What medications are used to treat mild or moderately active disease and to maintain a remission in IBD?	Sulfasalazine (decrease chronic inflammation) and mesalamine (use if intolerant to sulfasalazine)

What drug can be added for acute exacerbations?	Glucocorticoids (for acute exacerbations) in both oral and topical forms
When is surgery warranted in ulcerative colitis?	In life-threatening conditions (severe ongoing hemorrhage, toxic megacolon, or cancer)
What additional medication can be used in moderately severe Crohn disease patients?	TNF- α inhibitors, e.g., infliximab (Remicade)
When might surgery be considered in Crohn disease?	After medical therapy has failed in treating fistulas, obstruction, abscess, perforation, or severe ongoing hemorrhage
What is the curative treatment for ulcerative colitis?	Total proctocolectomy and ileostomy

CASE 13

A 72-year-old male with history of HTN, DM, PVD, CAD s/p CABG 4 years ago presents with low-grade fever, abdominal pain, and BRBPR. Abdomen is nontender and bowel sounds hypoactive.

What do you suspect?	Ischemic bowel disease caused by blood supply to the small intestine or colon
How do patients present with ischemic bowel disease?	Low-grade fever, bloody diarrhea or hematochezia, and LLQ tenderness
What are his risk factors for ischemic bowel disease?	Old age, atherosclerotic disease, peripheral vascular disease
What additional risk factor is there?	Hypercoagulable states
What imaging study should you order?	CT scan of the abdomen and pelvis looking for bowel wall edema and air (pneumatosis intestinalis)
CT reveals pneumatosis intestinalis. What diagnostic study is ordered next?	Flexible sigmoidoscopy or colonoscopy

What risk is associated with endoscopy?

Perforation

What is the therapy?

Correct underlying causes of low-flow states; no specific therapy is effective.

DIARRHEA

CASE 14

A 14-year-old, previously healthy girl presents with acute onset of nausea, vomiting, abdominal cramping, and nonbloody diarrhea after coming home from a family picnic yesterday. She has had 8 nonbloody bowel movements in the last 24 hours.

What type of infection is most likely?

Acute noninflammatory diarrhea

How does noninflammatory diarrhea present?

Watery, nonbloody diarrhea with associated cramps, bloating, nausea, and/or vomiting; no fever or leukocytosis

What causative organism do you suspect?

Staphylococcus aureus

Why?

S. aureus is associated with food poisoning and prominent vomiting.

What other organism is associated with prominent vomiting?

Viruses (Norwalk and rotavirus)

What organism is associated with

Recent travel (especially Mexico)?

ETEC

Sexual transmission?

Giardia sp

Seafood ingestion?

Vibrio cholerae

What lab tests at a minimum should you order?

CBC (rule out leukocytosis), Chem 8 (assess electrolytes and evidence of dehydration), stool for occult blood, fecal leukocytes (rule out infectious cause)

How is the diagnosis made?	Negative examination of stool for fecal leukocytes and blood
What is the treatment?	Oral rehydration and antidiarrheal agents (loperamide) for mild to moderate cases, supportive otherwise

CASE 15

A 10-year-old previously healthy boy returns from India with his mother and comes down with a low-grade fever and bloody diarrhea.

What type of diarrhea do you suspect?	Inflammatory diarrhea due to fever and bloody diarrhea
Which organism do you suspect?	<i>Entamoeba histolytica</i>
Why?	It's associated with recent travel (especially Asia, India, South and Central America).
What other clues to the diagnosis should you look out for?	
Dysentery-like illness days after food ingestion	<i>Shigella</i>
Dairy product or eggs	<i>Salmonella</i>
Food poisoning	<i>Campylobacter</i>
Recent antibiotic use	<i>Clostridium difficile</i>
Contaminated meat products and hemolytic-uremic syndrome	EHEC 0157:H7
Immunocompromised and HIV-infected patients	Cytomegalovirus
What basic lab test will you order to make the diagnosis of infectious diarrhea?	Fecal leukocytes (should be positive)

What additional tests are required to diagnose *Shigella*, *Salmonella*, *Campylobacter*, and EHEC 0157:H7?

Stool culture

E. histolytica?

Wet mount examination of stool for amebiasis

C. difficile?

C. difficile toxin in the stool or demonstration of pseudomembranes on sigmoidoscopy

Giardia?

Stool parasite exam or duodenal aspirate exam if stool is negative

What is the initial treatment strategy?

Rehydration if necessary and empiric antibiotic treatment with ciprofloxacin, trimethoprim-sulfamethoxazole, or erythromycin while awaiting culture results

What's the specific therapy for

C. difficile?

Metronidazole

Salmonella, *Shigella*, and *Campylobacter*?

Ciprofloxacin

Cytomegalovirus?

Ganciclovir

E. histolytica?

Metronidazole

HEPATIC INFLAMMATION

CASE 16

A 50-year-old previously healthy male decides to see a doctor for the first time since his service in the military due to his wife's urging. The physical exam is unremarkable except for hepatomegaly 2 cm below the costal margin. His liver chemistry tests are abnormal with an AST of 250 and ALT of 88.

What's the first question you are going to ask the patient?

"How much EtOH do you drink?"

Why?	↑ AST (<500), ↑ AST/ALT (3:1) is associated with alcoholic liver disease.
What other lab abnormalities may be present?	↑ MCV, ↑ WBC, and ↑ bilirubin
What course in the disease do you suspect the patient is in?	Early (often asymptomatic with abnormal liver enzyme tests)
What are some signs and symptoms of alcoholic cirrhosis?	Weakness, fatigue, weight loss, jaundice, hepatomegaly, ascites, palmar erythema, spider angiomas, varices, and testicular atrophy
How is the diagnosis made?	History, presentation, and associated liver enzyme tests; liver biopsy may confirm it (shows fat, PMNs, and hyaline)
What is the therapy?	Discontinue all alcoholic beverages; vitamin and nutritional support
When is transplant recommended?	In end-stage cirrhotic liver disease with at least 6 months abstinence from alcohol

CASE 17

A 37-year-old nonsmoking female is diagnosed with emphysematous lung disease after complaining of SOB and wheezing to her primary care physician. The cause of the lung disease is unclear. On a follow-up visit, her symptoms have decreased on therapy. But now the lab reports that there is mild to moderate elevation of her liver chemistry tests suggestive of hepatitis.

Which underlying disease do you suspect?	α_1 -Antitrypsin deficiency because the patient is a young nonsmoker with emphysema of unknown cause presenting with abnormal liver chemistry tests
What organs can α_1-antitrypsin deficiency affect?	Lungs, liver, and pancreas
Do all patients with liver disease have the associated pulmonary emphysema?	No

What is α_1-antitrypsin?	A plasma protein produced in the liver that inhibits proteolytic enzymes such as trypsin
What lab tests support the diagnosis?	Positive ZZ genotype test or low levels of α_1 -antitrypsin (low levels alone are not diagnostic; may be heterozygous)
How is the diagnosis confirmed?	Liver biopsy
What is the treatment?	Supportive
What treatment should be considered if end-stage liver disease develops?	Liver transplant because it is curative by correcting the underlying metabolic defect

CASE 18

A 58-year-old female with history of hypothyroidism, diabetes, and hypercholesteremia presents for follow-up office visit after noting $3\times$ elevation of her ALT and AST 4 weeks ago. At that time, you discontinued the cholesterol-lowering medication and it had no effect. Viral hepatitis was also ruled out.

What disease should be first on your differential diagnosis based on her history?	Autoimmune hepatitis (AIH)
Why?	Female (more common) with other autoimmune disease presenting with elevated liver chemistries is suspicious for AIH.
Name 4 associated lab findings that are helpful in making the diagnosis.	Any or all of the following may be positive: anti-smooth muscle antibody, antinuclear antibody, hypergammaglobulinemia (IgG), and anti-liver-kidney-microsomal antibody.
How is it diagnosed?	Liver biopsy
What is the treatment?	Prednisone and azathioprine

CASE 19

A 28-year-old alcoholic with chronic pancreatitis presents for follow-up after starting Alcoholics Anonymous. She continues to drink but has cut back to 1 six-pack/day. She complains of lower back pain that started after lifting her child into his car seat 1 week ago. Her physical exam is unremarkable, but there is significant elevation of her ALT and AST to around 1000 U/L.

What are the common causes of ALT more than 1000?	Ischemia (recent shock), toxins, drugs, gallstones in biliary tree, viral and autoimmune hepatitis
Which is most likely here?	Drug induced
What was the clue in the presentation?	Recent back pain
What's the most likely and most common offending drug to cause this?	Acetaminophen
Are excessive doses of acetaminophen required to cause acute liver failure in an alcoholic?	No, therapeutic dosing can cause it.
Name some other prescribed drugs that cause severe elevations of AST and ALT.	Isoniazid, phenytoin, 6-mercaptopurine, valproic acid, nitrofurantoin, and ketoconazole
What are patients at risk of?	Acute liver failure
What are some symptoms of acetaminophen-induced acute liver failure?	
Early (0–24 hours)	GI irritation (nausea, vomiting, and anorexia), lethargy, diaphoresis
Late (3–4 days) after ingestion	Progressive hepatic encephalopathy (including confusion, lethargy, and coma), indicating fulminant hepatic failure

What additional liver tests are critical to determine the severity of underlying injury?

Bilirubin and PT or INR

What serum test should you order to determine treatment strategy?

Acetaminophen level

What is the treatment in general for drug hepatotoxicity?

Discontinue medication; consider liver transplant if patient develops fulminant hepatic failure.

What is the treatment for acetaminophen toxicity?

Gastric decontamination using ipecac or gastric lavage, activated charcoal, cathartic, and *N*-acetylcysteine (antidote)

CASE 20

A 55-year-old white male with history of arthritis, diabetes, and dark complexion presents to your clinic after being declined life insurance because of abnormal AST and ALT of around 200 U/L. Physical exam is unremarkable except for mild hepatomegaly 1 cm below the right costal margin and tanned skin.

What underlying liver disease do you suspect?

Hemochromatosis

Why?

Dark complexion (bronze color, tanned appearance), diabetes, and arthritis were clues in the presentation.

What other clues may be presented to you if the patient is male?

Hypogonadism

In practice (real life), how do most patients actually present?

Asymptomatic

What causes hemochromatosis?

A common inherited autosomal recessive disorder of iron metabolism that results in excess iron deposits throughout the body

What lab tests will you order to support your diagnosis? A fasting serum transferrin saturation (above 45% suggests the disease)

How is the diagnosis confirmed? Increased iron weight on liver biopsy

What's the therapy? Phlebotomy or deferoxamine (iron-chelating agent) if unable to tolerate phlebotomy

CASE 21

A previously healthy 17-year-old female returns from vacation with friends and develops progressive nausea and anorexia followed by yellow skin and eyes and dark urine. Her mother calls her friend's mom in the nearby town and learns that there has been an outbreak of this in the last week.

What the most likely cause? Hepatitis A virus (HAV)

How did she get it? Probably via fecal–oral route from contaminated food or water

What are the risk factors for hepatitis A infection? Recent travel to endemic areas, children in day care, eating raw shellfish

What lab tests should be performed? HAV IgM and IgG serum antibody tests, LFTs (AST and ALT), alkaline phosphatase, and bilirubin

How is the diagnosis of acute hepatitis A made? HAV IgM serum antibody test

What lab test indicates previous exposure to HAV and immunity to recurring HAV infection? A positive HAV IgG serum antibody test

What is the treatment? Supportive. HAV immune globulin should be given to all close personal contacts of patients with hepatitis A.

CASE 22

A 44-year-old thin, healthy female married to a man with chronic hepatitis B presents for follow-up after yearly physical exam. You are concerned about mild elevations of her ALT and AST, around 220 U/L. She denies alcohol use, prior IVDA, tattoos, blood transfusions, or family history of liver disease.

What can cause these mild elevations?	Medications, hepatitis B and C, hemochromatosis, fatty liver, AIH, Wilson disease, and α_1 -antitrypsin deficiency
What is the most likely cause?	Hepatitis B
How does it present?	Often asymptomatic (80%), but a prodrome of nausea, anorexia, and malaise followed by jaundice, dark urine, and abdominal pain may occur.
What causes it?	Hepatitis B virus (HBV), a DNA virus
How is it transmitted?	Usually via contaminated blood or sexual contact (her husband has chronic hepatitis B)
What are the risk factors for hepatitis B?	Injection drug users and men who have sex with men, native Asians, health-care workers, tattoos, and vertical transmission in pregnancy
How is the diagnosis of acute hepatitis B made?	Positive hepatitis B surface antigen (HBsAg) and hepatitis B core antibody from the IgM class (IgM anti-HBcAb)
What treatment is available for patients recently exposed to HBV?	Hepatitis B immunoglobulin (HBIG)
What is the medical treatment for acute hepatitis B?	Supportive
What is the medical treatment for chronic (at least 6 months) hepatitis B?	α -Interferon subcutaneous injections or oral lamivudine or adefovir

CASE 23

A 49-year-old male lead singer for a well-known rock band is found to have elevated ALT and AST of around 180 U/L on routine lab tests. He admits to IVDA and alcohol use in the past, but quit drinking 10 years ago. He has made significant changes in his lifestyle and has been routinely exercising and eating well.

What is the most likely cause of his abnormal liver chemistry tests?

Hepatitis C

Why?

IVDA is a risk factor for hepatitis C infection, and he has mild elevation of his liver chemistry tests, which is characteristic of the disease.

What other risk factors are there?

Transfusion recipients (before 1992), health-care workers, tattoos

How is it usually transmitted?

Via contaminated blood transfusions or needles

How can it present?

Majority is asymptomatic, but a prodrome of nausea, anorexia, and malaise followed by jaundice, dark urine, and abdominal pain may occur.

What causes it?

Hepatitis C virus (HCV), an RNA virus

What lab tests should you order?

Hepatitis C serum antibody test, PCR RNA for hepatitis C, LFTs (AST and ALT), alkaline phosphatase, and bilirubin

Which test indicates prior infection?

Hepatitis C antibody

What test indicates ongoing viral infection?

PCR for hepatitis C RNA

What is the treatment for chronic (more than 6 months) hepatitis C?

α -Interferon with oral ribavirin for 6–12 months

CASE 24

A 55-year-old male with history of CAD admitted to the hospital with a cardiac arrest secondary to acute MI is now stabilized in the ICU on pressor medications to sustain adequate blood pressure. On a routine blood draw, you note new elevations of his ALT and AST to 1200 U/L.

What's the most likely cause?	Ischemic hepatitis secondary to hypotension during cardiac arrest
What are the risk factors for ischemic hepatitis?	Low-flow states [shock (often unwitnessed and undocumented), CHF, MI, and arrhythmia]
How is it diagnosed?	History of low-flow state (transient hypotension) preceding rapid rise of transaminases into the thousands
What is the therapy?	Supportive, correct underlying low-flow state

CASE 25

A 24-year-old previously healthy male comes to you because he is having difficulty walking. Physical exam is impressive for golden brown deposits in the cornea and a parkinsonian-like tremor.

What's your most likely diagnosis?	Wilson disease
What were the clues in the presentation?	Young adult with tremor and golden brown corneal deposits
How can Wilson disease present?	As liver disease in adolescents and neuropsychiatric disease in young adults
What are the golden brown corneal deposits called in Wilson disease?	Kayser-Fleischer rings
What other neurologic findings may be found on physical exam?	Rigidity and chorea-type movements (common by age 40)

What psychiatric findings may be found on physical exam?

Depression and psychosis

What causes Wilson disease?

An autosomal recessive disorder of copper metabolism characterized by progressive copper accumulation in the liver, which is then released and taken up by other organs (brain, cornea, kidney, etc.)

Why does the copper accumulate in the liver?

It is unable to excrete sufficient copper into the bile.

What lab tests and physical exam finding support the diagnosis?

Elevated 24-hour urinary copper levels, low serum ceruloplasmin, and Kayser-Fleischer rings

How is the diagnosis confirmed?

Increased copper weight on liver biopsy

What is the medical treatment?

Lifelong copper-chelating agents (penicillamine)

CHOLESTATIC DISEASE

CASE 26

A 41-year-old alcoholic male presents to the ER again with complaints of abdominal pain that radiates to his back and stools that float in the toilet bowl, after drinking large quantities of alcohol. The character of the pain is similar to prior episodes, but is more prolonged this time. He knows alcohol bingeing worsens his condition, but he just can't stop drinking.

What's the most likely cause of his abdominal pain?

Acute or chronic pancreatitis secondary to alcohol

What other condition causes epigastric pain radiating to the back?

Penetrating PUD

Why is pancreatitis more likely?

Patient describes steatorrhea (stools that float), which supports pancreatitis and exocrine insufficiency

What other symptoms may patients with pancreatitis present with?	Jaundice, diabetes, and weight loss
What are common risk factors for pancreatitis?	Chronic alcoholism and history of gallstone disease
What's the basic underlying mechanism of disease?	Inflammation of the pancreas from scarring or stricture of the distal common bile duct
What labs are consistent with pancreatitis?	Elevated amylase and lipase
Can these be normal in pancreatitis?	Yes
When?	Patchy focal disease or significant underlying fibrosis/scarring
What tests can be done on the stool to diagnose pancreatic exocrine dysfunction?	Quantitative fecal fat (>7 g of fat per day), qualitative fecal fat (Sudan test), and stool elastase 1
What imaging studies are helpful in making the diagnosis?	US (rule out gallstones or dilated biliary tree), CT scan (visualize pancreas), and ERCP (visualize pancreatic duct)
What findings on US and CT are consistent with pancreatitis?	Pancreatic calcifications, enlargement, ductal dilatation, and pseudocysts (fluid collection around the pancreas)
What other important disease will CT and US help rule out as a cause of this patient's exacerbation?	Pancreatic cancer
What additional diagnostic test can be ordered if CT and US are inconclusive?	ERCP
What findings on ERCP are diagnostic of pancreatitis?	Beading of the main pancreatic duct with ectatic side branches

What is the medical treatment?

Alcohol abstinence, analgesics, oral pancreatic enzyme supplements (steatorrhea and malnutrition), and insulin (diabetes)

CASE 27

A 51-year-old female with history of diabetes, obesity, HTN, and hyperlipidemia complains of stomach pain and pain under the right rib after eating at fast food restaurants. The pain comes on quickly and usually goes away over the next few hours. It does not occur with drinking water or eating fruit. She wonders if she should stop eating at fast food restaurants. Right now, she does not have any pain.

What is most likely causing her pain?

Biliary colic from gallstone disease

Why does pain occur in biliary colic?

The gallbladder contracts after a fatty meal and presses a stone against the gallbladder outlet or cystic duct opening leading to increased pressure within the gallbladder.

What risk factors does she have for gallstones?

Obesity and diabetes

What are some other risk factors for gallstone formation?

Crohn disease, cirrhosis, and pregnancy

When should biliary colic be suspected?

Intermittent RUQ or midepigastria discomfort or pain that may radiate to the back or to the tip of the scapula

What lab tests should be ordered?

CBC, liver function panel, amylase, lipase, and Chem 8

What imaging study should be ordered?

RUQ US

How is biliary colic diagnosed?

History, presentation, and US revealing gallstones

How is biliary colic treated?

Laparoscopic cholecystectomy

Why is it important to treat it?	To decrease the risk of developing acute cholecystitis
What causes cholecystitis?	A stone becomes impacted in the cystic duct and inflammation develops behind it (unlike biliary colic where it only intermittently obstructs it).
What triggers it?	A large or fatty meal just like with biliary colic
How does cholecystitis present?	Constant severe RUQ pain (may radiate to the right infrascapular area), nausea, vomiting, fever, and leukocytosis
By assessing symptoms, how can you quickly distinguish this from biliary colic?	The RUQ pain often lasts for more than 4–6 hours, and fever is often present.
What are the common physical exam findings?	Ill appearing, fever, tachycardia, and lying still because of underlying parietal peritoneal inflammation, voluntary and involuntary guarding
What is a key sign found on physical exam?	Murphy sign (pain elicited by placing the hand under rib cage on inspiration)
What labs should be ordered?	Same as in biliary colic
How is acute cholecystitis diagnosed?	History, presentation, US and/or HIDA (more sensitive), and elevated WBC count
What is the treatment for acute cholecystitis?	NPO, IV fluids, analgesics, and antibiotics followed by laparoscopic cholecystectomy after the patient is stable
What would you be concerned about if the last patient was jaundiced and had an elevated conjugated bilirubin?	Acute cholangitis

How does acute cholangitis present?	Sudden onset of RUQ pain, fever, and jaundice (Charcot triad); nausea and vomiting may also be present.
What commonly causes acute cholangitis?	Gallstones promote bile stasis and serve as a nidus of infection for bacteria from the duodenum to ascend the biliary tract.
What are the common organisms?	<i>Enterococcus</i> , <i>Escherichia coli</i> , and <i>Klebsiella</i>
What lab finding suggests the diagnosis?	Bilirubinuria, high conjugated bilirubin, and alkaline phosphatase
How is cholangitis diagnosed?	History, presentation, ERCP (US and HIDA less reliable)
What is the treatment for cholangitis?	After stabilizing the patient, proceed with endoscopic removal of common bile duct stone with ERCP followed by laparoscopic cholecystectomy.

CASE 28

A 48-year-old male with history of liver cirrhosis secondary to chronic hepatitis C, colon cancer s/p resection 8 years ago with normal colonoscopy report 6 months ago presents to your office with an 8-lb weight loss over the last 6 weeks without change in diet or exercise, RUQ discomfort, and jaundice.

What is the most likely cause?	Hepatocellular carcinoma (HCC)
Why?	Chronic hepatitis C and cirrhosis of the liver are both risk factors for HCC.
What other risk factors are there for a primary liver cancer?	Chronic hepatitis B, alcoholic cirrhosis, α_1 -antitrypsin deficiency, and hemochromatosis
What is the most common cause of liver cancer?	Metastatic colon and breast cancer (lung, stomach, kidney, and pancreas less common)
Why is colon cancer less likely in this patient?	Lack of changes in bowel habits and normal colonoscopy within the last 6 months

How does HCC commonly present?

Often asymptomatic, but may present with mild to moderate upper abdominal pain, weight loss, early satiety, palpable abdominal mass, worsening ascites, encephalopathy, jaundice, or variceal bleeding

What are the associated lab tests?

Small elevated alkaline phosphatase, occasionally slight increase in ALT or bilirubin

What imaging studies help make the diagnosis?

US and CT scan

Describe the lesion shown in Figure 3–4.

Arterial enhancing lesion (*arrow*) in right lobe of liver consistent with HCC

How is the diagnosis made?

Needle biopsy, often CT or US guided

What studies and tests are available to monitor cirrhotic patients at risk of hepatoma?

US or CT and α -fetoprotein at least yearly

What is the treatment?

Surgical resection for small solitary hepatoma, supportive otherwise

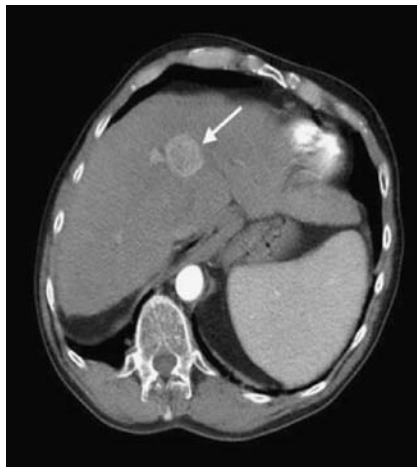


Figure 3–4. Arterial enhancing lesion (*arrow*) in right lobe of liver consistent with HCC.

CASE 29

A 44-year-old female with history of rheumatoid arthritis controlled with immunomodulators and cholecystectomy owing to atypical abdominal pain with elevated alkaline phosphatase and serum bilirubin presents to your office with severe generalized itching after relocating to the area from another state. She has tried over-the-counter Benadryl for the itching, but it has not helped. Other than excoriations on her arms and legs from scratching, her exam is normal.

What is the most likely cause of her itching?

Primary biliary cirrhosis (PBC)

What are the clues in this patient?

Female gender, severe generalized pruritus, known autoimmune disease (rheumatoid arthritis), history of elevated alkaline phosphatase and bilirubin

What else may present as the disease progresses?

Hepatomegaly, weight loss, and diarrhea

What additional features may present years later?

Jaundice, dark urine, pale stools, and signs of portal HTN

What causes PBC?

A slowly progressive autoimmune disease characterized by destruction of intrahepatic ducts and cholestasis

What other diseases may be evident on physical exam?

Other autoimmune diseases (scleroderma, Sjögren syndrome, pernicious anemia, thyroid disorders, rheumatoid arthritis, and vitiligo)

What lab test results suggest the diagnosis?

Increased alkaline phosphatase and bilirubin

What test results are more specific to PBC?

Positive antimitochondrial antibody and elevated serum IgM levels

How is the diagnosis confirmed?

Liver biopsy

What medication may delay early-stage disease progression?

Ursodeoxycholic acid

What medication is used to treat pruritus? Cholestyramine

CASE 30

A 35-year-old male with longstanding history of ulcerative colitis follows up in your clinic for his yearly exam after having preclinic labs done. His CBC and chemistry panel are normal, but the alkaline phosphatase is elevated $3\times$ the normal value.

What disease process are you most concerned about? Primary sclerosing cholangitis (PSC)

Why? Ulcerative colitis is a risk factor for PSC.

What is PSC? A chronic cholestatic disease of unknown etiology characterized by diffuse inflammation, fibrosis, and eventual destruction of extrahepatic and intrahepatic bile ducts

Do the disease activities of PSC and IBD correlate with each other? No

How do most patients present? With elevated cholestatic LFTs, especially alkaline phosphatase

What symptoms or signs might he have? Fatigue and pruritus

What sign suggests advanced PSC? Jaundice

What noninvasive imaging test can be helpful in making a diagnosis? RUQ US or MRI

Is a liver biopsy required to make the diagnosis? No

How is the diagnosis confirmed? ERCP with cholangiogram demonstrating multifocal structuring and dilation of intrahepatic and/or extrahepatic bile ducts

What is the treatment?	ERCP for balloon dilatation of local strictures and liver transplant for end-stage liver disease patients
Does a colectomy in IBD patients protect against PSC?	No
What are PSC patients at increased risk of developing?	Cholangiocarcinoma

PANCREAS

CASE 31

A 55-year-old businessman with history of HTN, hyperlipidemia, and arthritis presents to the ER Saturday night after entertaining clients at a professional hockey game complaining of severe acute 10/10 epigastric pain that radiates to the back, with nausea and nonbloody emesis. This has never occurred before. Lately, his other medical conditions have been well controlled by his primary care physician. However, he has been urinating more after his doctor put him on a hydrochlorothiazide about a week ago. On physical exam, you detect alcohol on his breath and tenderness to palpation in the epigastric area; otherwise the exam is within normal limits.

What could be causing his pain?	Acute pancreatitis, PUD, gastritis, esophagitis, cholecystitis
Which is more likely?	Acute pancreatitis because the pain radiates to the back
Can PUD do that?	Yes, if the patient has a penetrating ulcer
Is this patient at risk of ulcer disease?	Possibly; he has arthritis and may be taking over-the-counter aspirin or other NSAIDs.
Why is PUD less likely in this patient?	No prior episodes of epigastric pain and the current episode occurred acutely
What is the most likely cause then?	Acute pancreatitis

What's the basic pathogenesis in acute pancreatitis?	A sudden nonbacterial inflammation of the pancreas that occurs when pancreatic enzymes escape and digest the pancreas and surrounding tissue
Name the 2 most common causes.	Gallstones disease and alcoholism
What are his risk factors for acute pancreatitis?	Hyperlipidemia, hydrochlorothiazide, and alcohol use
What other risk factors are there?	Other drugs (e.g., furosemide, steroids), infections (e.g., mumps), cardiac bypass surgery, tumors, and peptic ulcers
What 2 findings on physical exam are unique to acute pancreatitis?	Cullen sign (periumbilical discoloration) and Grey Turner sign (bluish discoloration in the flank area)
What abnormal lab values would you expect?	Increased amylase and lipase
What 3 radiographic tests are helpful in making the diagnosis?	Ultrasound, abdominal x-ray, and CT scan of abdomen
Why is the ultrasound useful?	It's inexpensive and gives valuable information about the bile duct and gallbladder.
Describe the associated finding of pancreatitis on the abdominal x-ray shown in Figure 3–5.	Sentinel loop (dilated bowel loop near pancreas) or the colon cutoff sign (distended gas in the right colon that stops near the pancreas); arrows indicate calcifications consistent with chronic pancreatitis often from alcohol use
Why is a CT scan of the abdomen useful?	Can detect extent of pancreatic inflammation and whether or not any sequelae of pancreatitis have developed
How is the diagnosis made?	Presentation and associated lab values (increased amylase and lipase)
What is the initial treatment?	NPO, NG suction (if vomiting), IV fluids, Foley catheter, antibiotics (if fever) and analgesics (narcotics), and H ₂ blockers

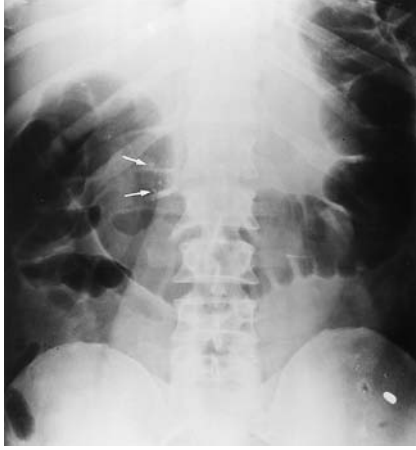

Figure 3–5.
(From Daffner RH. Clinical Radiology: The Essentials. 3rd Ed. Philadelphia: Lippincott Williams & Wilkins, 2007.)

If medical therapy fails, what is the next step in management?

Surgical consult

What prognostic criteria are used to assess mortality risk?

Ranson's criteria

Define Ranson's criteria during the first 24 hours of admission.

Age >55 years, blood glucose >200 mg/dL, serum LDH >350 IU/L, serum AST >250 IU/L, WBC count >16,000 cells/mL

Define Ranson's criteria within 48 hours of admission.

Hematocrit drops >10%, BUN rises >5 mg/dL, serum calcium <8 mg/dL, PaO_2 <60 mm Hg, base deficit <4 mEq/L, fluid sequestration <6 L

How many of Ranson's criteria are needed to indicate poor outcome and increased risk of mortality?

Three or more

CASE 32

A 41-year-old female smoker recently diagnosed with diabetes presents to your office with jaundice. Her friends noticed that she started looking more yellow about 10 days ago and has gradually progressed. She notes that her Accu-Cheks for her diabetes have been higher even with taking the recommended dose of her medications. The physical exam is unremarkable except for a small right supraclavicular node and yellow skin. She wants to know if the yellow skin is from the diabetes or recently prescribed medication.

What do you think she has?	Pancreatic cancer
What is the most common histologic type?	Adenocarcinoma (often of ductal origin)
What were the clues?	Smoker (a risk factor), recent diagnosis of diabetes, supraclavicular node (Virchow node), and painless jaundice
What other symptoms might be presented to you?	Icterus, pancreatitis, abdominal pain that radiates to the back, and weight loss
What other signs may be found on physical exam?	Periumbilical node (Sister Mary Joseph's node), Courvoisier gallbladder (distended gallbladder as a result of common bile duct obstruction), and rectal shelf mass (Blumer shelf)
What do these findings suggest?	Metastatic disease
What labs should you order?	Chem 8, LFT, PT
What are the associated lab values?	Hyperglycemia and increased bilirubin, alkaline phosphatase, AST, and ALT if bile duct obstruction occurs; PT may be elevated because of malabsorption of vitamin K-dependent factors (II, VII, IX, X)
What tumor markers may be elevated?	CA 19-9 and CEA
What imaging is useful?	US (locate site of obstruction), CT (determine extent of disease), and ERCP with brushings (biopsy to confirm diagnosis)

Once the mass is identified, what's the best diagnostic procedure to order?	Endoscopic ultrasound with fine needle aspiration
What is the treatment for localized disease?	Surgical resection
What medical therapy may be employed for metastatic disease?	5-FU

MISCELLANEOUS DISORDERS

CASE 33

A 47-year-old obese male with history of HTN and hyperlipidemia presents with 3-month history of infrequent, intermittent left groin bulging, which occurs most often when lifting heavy boxes at work or straining when going to the bathroom.

What do you suspect this patient has?	Inguinal hernia
What risk factors does he have?	Obesity and excessive straining
What additional risk factor may be present in other patients for an inguinal hernia?	Pregnancy, chronic cough, and ascites
How do most inguinal hernias present?	Often asymptomatic and detected on routine physical exam by detecting a mass or bulge in the inguinal canal as the patient coughs
Your physical exam confirms the findings above. What type of inguinal hernia does he have?	Reducible
What is a reducible hernia at risk of?	Incarceration
How would the physical exam change?	The inguinal bulge would become firm, nonreducible with tenderness to palpation

What are the dreaded complications of incarcerated hernias?

Strangulation and infarction

How is it diagnosed?

Physical exam

What causes an inguinal hernia?

Protrusion of intra-abdominal contents through a defect in the abdominal wall

What treatment should you offer this patient with a reducible hernia?

Elective surgical repair

What if it becomes nonreducible?

Immediate surgical repair

Chapter 4

Nephrology

RENAL FAILURE

CASE 1

A 68-year-old male with history of dementia, CHF, DJD, taking NSAIDs and BPH with an elevated prostate-specific antigen (PSA), presents to the ER from the nursing home with recent onset of worsening mental status and decreased urine output. Due to his confused state, it is difficult to obtain additional history. Routine blood work ordered yesterday from the nursing home is provided, and you see that the serum creatinine (Cr) has increased to 3 from a prior value of 1.2, which was 6 weeks ago.

What's his new diagnosis?

Acute renal failure (ARF)

What 3 broad categories could his ARF be caused from?

Prerenal, renal, and postrenal

Give examples of each.

Prerenal

Inadequate perfusion (volume depletion, CHF, decreased effective blood volume)

Renal

Acute tubular necrosis (ATN), acute interstitial nephritis, acute glomerulonephritis

Postrenal

Obstruction—bladder outlet or bilateral ureteral

What known risk factors does he have for each group?

Prerenal

CHF

Renal

NSAID-induced nephrotoxicity

Postrenal?

BPH; to rule out prostate cancer (PSA is elevated)

What key presenting features in the history would raise your suspicion of

Prerenal?

History of cardiac events, hypotension, recent decompensation of CHF, cirrhosis

Renal?

Drug history, with attention to potential nephrotoxins, including radiocontrast and over-the-counter meds (especially NSAIDs)

Postrenal?

Hematuria, retentive symptoms, flank pain, decreased urine output

What key physical signs would support

Prerenal cause?

Rales, gallop, edema, JVD (CHF exacerbation) or orthostatics, dry mucosae, poor skin turgor (volume depletion)

Obstruction?

Bladder percussion, distention, or abdominal tenderness (including flank pain), nodular enlarged prostate on rectal exam

What simple bedside procedure, if positive, would support obstructive cause?

High post-void residual volume

How is this test done?

Patient is asked to urinate, then a straight catheter or bladder scanner (ultrasound) is used to determine residual bladder volume.

What lab tests are used to narrow the differential?

Urinalysis, urine Na (UNa) and Cr, serum Na, Cr, and BUN (blood urea nitrogen)

How would you interpret the following urine sodium values?

Low UNa (<20 mEq/L)

Suggests functional tubules stimulated to retain sodium as seen in prerenal conditions such as CHF

High UNa in a hypotensive patient

Renal failure secondary to failure of the tubules to retain Na despite appropriate stimulus

What is FENa and how is it calculated?

Fractional excretion of sodium is a refinement of UNa, by adjusting for urinary concentration

$$FENa = \frac{(UNa/PNa)}{(UCr/PCr)} \times 100\%$$

What does a FENa <1% imply?

Tubular retention of Na in attempt to increase glomerular filtration rate (GFR) in such states of prerenal failure (e.g., CHF)

What other lab findings suggest prerenal azotemia?

BUN/Cr >20–40, urinary specific gravity >1.025

How would you interpret the following urine sediment results?

Bland sediment

Suggests prerenal failure or obstruction

Granular casts, tubular cells, and casts

Renal failure secondary to ATN often secondary to medications

RBC casts

Renal failure secondary to glomerulonephritis

WBCs and WBC casts, with eosinophils

Renal failure secondary to acute interstitial nephritis

Heme positive, without RBCs

Renal failure secondary to pigmenturia (hemoglobin or myoglobin)

What additional workup should be ordered based on the following urine sediment tests?

RBC casts

Antistreptolysin O (ASO), antineutrophil cytoplasmic antibody, complements, antinuclear antibody (ANA), hepatitis serologies, and possible renal biopsy

WBCs and WBC casts, with eosinophils acute interstitial nephritis (AIN)

Review medications (including over-the-counter and herbal)

Bland sediment not in a prerenal setting

Abdominal ultrasound to rule out obstruction (95% sensitive)

Describe the appropriate treatment based on cause of ARF.

Prerenal

Ensure adequate volume, maximize cardiac output

Obstruction

Relieve obstruction with Foley, percutaneous nephrostomy, etc., as indicated

Acute glomerular nephritis (GN) and rapidly progressive glomerular nephritis (RPGN)

See sections on those diagnoses

Acute interstitial nephritis

Remove offending agents, consider steroids

ATN

Optimize cardiac output and volume status; loop diuretics to convert oliguric to nonoliguric ATN, if possible; restrict Na, K, protein; dose adjust meds for impaired GFR; avoid further nephrotoxin exposure; dialysis as indicated.

What are the indications for dialysis?

Volume overload, hyperkalemia, acidosis refractory to medical measures, uremic platelet dysfunction with bleeding, uremic syndrome (encephalopathy, pericarditis)

CASE 2

55-year-old male with history of COPD, multifocal tachycardia, arthritis, hypertension, diabetes, and chronic renal insufficiency presents to your clinic for a routine checkup after obtaining a CBC and CMP. His Cr has increased from 2.5 to 3, Hg is 9.5, HgA1C is 8, PO₄ of 6, HCO₃ of 16.

What is the most likely explanation for the following?

Increased Cr

Uncontrolled hypertension or diabetes (the two most common causes of CRF) worsening his underlying CRF

Elevated HgA1C

Uncontrolled diabetes

Low Hg

Low erythropoietin level secondary to decreased production from failing kidneys

High PO_4

Secondary to markedly increased parathyroid hormone in CRF patients as an adaptive response in an attempt to maintain normocalcemia

What should be the goals of this office visit?

Aggressive BP control, optimize diabetes control, lower PO_4 , raise Hg

What's a reasonable approach to the following problems?

Elevated BP

ACE inhibitor (has been shown to decrease risk of progression and development of proteinuria)

Hg 9.5g/dL (anemia)

After other factors (vitamin deficiencies, bone marrow disorders) have been excluded, therapy with recombinant human erythropoietin

High PO_4 (secondary hyperparathyroidism)

Limit dietary phosphate; add a phosphate binder such as calcium acetate or sevelamer to keep PO_4 below 5.5 mg/dL; add active vitamin D analogues (calcitriol, doxercalciferol) to lower iPTH

HCO_3 of 16 (chronic metabolic acidosis)

NaHCO_3 given at 650 mg tid to start to maintain serum HCO_3 in the 18–20 mEq/L range

What drugs should be avoided in CRF?

Nephrotoxins (such as radiocontrast, aminoglycosides) or drugs with significant renal effects (e.g., NSAIDs). Drugs with renal excretion need dose adjustment, as do drugs whose metabolites are renally excreted (e.g., procainamide). Some drugs are avoided entirely (e.g., meperidine).

Name some indications to start dialysis.

GFR of 5–10 cc/min/1.73 m² BSA; uremic signs or symptoms start, hyperkalemia, volume overload, acidosis or hypertension refractory to medical measures

How is GFR calculated?

$$C_{\text{Creat}} = \left[\frac{(140 - \text{age}) \times \text{lean body mass [kg]}}{72 \times \text{serum creatinine}} \right] \times 0.85 \text{ for females}$$

What are the symptoms of uremia?

Fatigue, anorexia, metallic or ammoniacal taste, sleep cycle disturbances, pruritus, dyspnea

What are the signs of uremia?

Asterixis, peripheral neuropathy, serositis (especially pericarditis), dry skin, prurigo, signs of volume overload

FLUID AND ELECTROLYTES

CASE 3

A 55-year-old asymptomatic male with history of HTN, hyperlipidemia, diabetes, and DJD comes to your office for a routine office visit after obtaining routine blood tests prior to his visit. His serum chemistry panel is all within normal limits except for his serum Na, which is low at 131 mmol/L.

What can you infer from his asymptomatic state?

The hyponatremia developed slowly. More rapid or severe hyponatremia can cause headache, lassitude, seizure, and coma.

What 4 broad groups can hyponatremia be classified into?

Pseudohyponatremia, hypovolemia, euvolemia, and hypervolemia

What's the first step in the workup?

Rule out pseudohyponatremia

What is pseudo-hyponatremia?

Apparent hyponatremia with normal or high serum osmolality caused by severe hyperglycemia, hyperlipidemia (>1200 mg/mL), or severe hyperproteinemia (e.g., myeloma)

Is he at risk for this condition?

Yes, he is a known diabetic and has hyperlipidemia.

What would you order to rule this out?

Serum protein, cholesterol, and glucose level (or Accu-Chek).

What is the therapy for pseudohyponatremia?

Treat the underlying disorder

What's the next step if pseudohyponatremia is ruled out?

Assess volume status (hyper-, hypo-, or euvolemic) on physical exam

What are some physical exam clues for Hypervolemia?

Rales, LE edema, JVD (CHF), abdominal ascites (cirrhosis)

Hypovolemia?

Orthostatic hypotension, poor skin turgor, dry mucous membranes

What tests do you order after you establish the patient's volume status?

UNa and urine osmolality

For each of the conditions below, give a brief differential:

Hypovolemic hyponatremia with UNa >20 mEq/L

Renal losses by diuretics, hypoaldosteronism, or salt-wasting nephropathy

Hypovolemic hyponatremia with UNa <10 mEq/L

Extrarenal losses through gastrointestinal (GI) tract, third spacing or insensible losses

Euvolemic hyponatremia with urine osmolality <100 mEq/L

Psychogenic polydipsia (drinking excessive quantities of water)

**Euvolemic hyponatremia
with urine osmolality
>100**

SIADH

**Hypervolemic hypo-
natremia and UNa
<10 mEq/L**

CHF, cirrhosis, or nephrotic syndrome

**Hypervolemic hypo-
natremia and UNa
>20 mEq/L**

Renal failure

**Why is volume overload
(CHF, cirrhosis, nephrosis)
commonly associated with
hyponatremia?**

Despite pathologic sodium retention, even greater amounts of water have been retained, resulting in a dilution of the excess sodium, hence the term “dilutional hyponatremia” often applied here. CHF and decreased *effective* plasma volume stimulate ADH, causing water retention. The renal diluting mechanism may be impaired because of decreased GFR and distal Na delivery. In hospitals, sodium restriction is enforced more successfully than free water restriction.

What is SIADH?

Normovolemic hyponatremia (i.e., net free water accumulation) in a patient lacking known pathophysiologic stimuli to ADH release, such as CHF, cirrhosis, pain, and nausea. Must rule out endocrine disorders (thyroid, adrenal). Urine shows ADH effect: less than maximally dilute.

**What is SIADH usually
associated with?**

- (1) Intrathoracic processes: lung cancer (primary or metastatic to lung), bronchiectasis, tuberculosis
- (2) Intracranial events: hemorrhage, meningitis, encephalitis, tumors

**What drugs may produce an
SIADH-like picture?**

Chlorpropamide, narcotics, phenothiazines, tricyclics, SSRIs, carbamazepine, vincristine, Cytoxan, clofibrate. NSAIDs potentiate ADH effect.

How is hypovolemic hyponatremia treated?

Volume replacement with saline, monitor serum sodium

How is SIADH treated?

Fluid restriction is key, but often difficult to achieve. High protein intake may be helpful, by increasing daily osmotic load to be excreted. Demeclocycline, to deliberately produce nephrogenic diabetes insipidus (DI), has been used in difficult cases. Very low Na (120 mEq/L or less) requires ICU for administration of 3% hypertonic saline.

How is hypervolemic hyponatremia treated?

Fluid restriction is vital. Treat underlying disease (CHF, cirrhosis), and administer diuretics, with careful monitoring of electrolytes.

What are the risks of over-rapid correction of hyponatremia?

Central pontine myelinosis may occur if rate of correction is more than 1–2 mEq/L/hour, or if total increase is over 25 mEq/L over 48 hours. In mild, less symptomatic cases, the correction should be limited to 0.5 mEq/L/hour, or 12 mEq/24 hours.

CASE 4

A 48-year-old female with history of menorrhagia post-op day 2 after hysterectomy for uterine fibroids is found to have an elevated serum Na at 156 on am labs.

What symptoms of hypernatremia may be present?

Depending on severity and rapidity of rise, may see irritability, nausea, confusion, obtundation, fasciculations, seizures

When are symptoms more likely to occur?

Severe elevation or rapid increase from prior baseline serum Na level

What should be done first on physical exam to work up the elevated Na?

Assess volume status (vital signs, orthostatics, rales, edema, skin turgor, mucus membranes)

What typically causes hypernatremia and volume overload?

Excess administration of normal saline or sodium bicarbonate; usually occurs in hospital

If the patient is diagnosed to be hypovolemic or euvolemic, what lab test should be ordered next to narrow your differential?

Urine osmolality

What's a reasonable differential for the following urine osmolality?

<300

Complete DI

300–600

Renal water loss (diuretics or osmotic diuresis with glucose urea or mannitol), partial DI, reset osmostat

>600

Extrarenal water losses (GI or insensible losses)

What is central DI?

Inability of the pituitary to respond normally to hypertonicity by releasing ADH. This may be a complete or partial lack of ADH release.

What are the causes?

Idiopathic, seen in childhood. Adult cases are usually because of head trauma, tumors, or encephalitis.

What is nephrogenic DI?

Lack of response of concentrating segment of collecting tubules to ADH. This may also be partial or complete.

What are the causes?

In adults, hypercalcemia, toxins (e.g., lithium, demeclocycline), hypokalemia, obstructive nephropathy. May be congenital in children. Tubulointerstitial nephritis may reduce the corticomedullary gradient, thereby impairing the concentrating mechanism, but not to the degree seen in true nephrogenic DI.

How is diagnosis of DI confirmed?

Water-deprivation test, with administration of aqueous pitressin to differentiate central from nephrogenic DI

What is the treatment?

Volume depletion, excess treated in usual manner with saline, diuretics, respectively. Calculate free water deficit = $0.6 \times \text{weight (lean)} \times [(\text{Na} - 140)/140]$. Replace with D5W slowly, to lower Na by 1–2 mEq/L/hour.

How is central DI treated?

With ADH or synthetic ADH analogues, such as DDAVP. Ensure adequate access to free water.

How is nephrogenic DI treated?

Paradoxically, thiazides reduce urine output by blocking the tubular-diluting segment. This works best with moderate Na restriction. Ensure free water access. NSAIDs and amiloride may also be of use in reducing urine output, the latter in cases due to chronic lithium use.

CASE 5

A 44-year-old previously healthy male returns to your clinic 1 week after initially presenting with a complaint of generalized weakness. No significant findings were found on physical exam and the patient denied symptoms of depression or insomnia. You obtained a comprehensive metabolic panel, CBC, and TSH level. All the results are within normal limits except for the K level, which is 3.0.

Could this explain his generalized weakness?

Yes, weakness is one of the manifestations of hypokalemia.

What are some other typical clinical manifestations of hypokalemia?

Muscle cramps, paralytic ileus, cardiac arrhythmias and digitoxicity, glucose intolerance, polyuria

What are typical EKG changes in hypokalemia?

Lowering of T wave height and appearance of U waves

His EKG is normal and you've begun to supplement his K. What's the first step in working up his hypokalemia?

Check urine K level

What's your differential if the urine K is <25 mEq/day or <15 mEq/L?

GI losses such as in diarrhea, laxative abuse, vomiting, or nasogastric (NG) suction losses

What's your differential if the urine K is >30 mEq or >15 mEq/L?

Renal losses

What's the next step when hypokalemia is secondary to renal loss?

Check BP to assess if patient is hypertensive, normotensive, or hypotensive

What type of K wasting diseases need to be considered if the patient is hypertensive?

Primary (Conn syndrome) or secondary hyperaldosteronism (renal artery stenosis or renin-secreting tumors), and pseudohyperaldosteronism (Cushing syndrome)

What's the next step for patients whose blood pressure is normal or low?

Assess acid–base status

What's the differential for the following acid–base states?

Acidemic

Diabetic ketoacidosis or renal tubular acidosis (RTA)

Alkalemic

Diuretics; vomiting or NG suction; Bartter or Gitelman disease

What's the treatment strategy for hypokalemia?

Supplement K and Mg as necessary; treat underlying cause; repeat K level after supplementation

For each 1 mEq/L deficit, how much total body K needs to be replaced?

200 mEq

What's the standard oral dosing regimen for K supplementation in nonurgent cases?

KCl 40 mEq PO q 4–6 hours

Is there any role for K-sparing diuretics?

Yes, these are useful in chronic situations provided the patient's K can be adequately monitored. Spironolactone is of particular value in cases of secondary hyperaldosteronism, e.g., cirrhosis and CHF.

CASE 6

A 54-year-old male is seen in the ER for epigastric pain felt secondary to peptic ulcer disease as a result of his significant intake of ibuprofen over the last 2 weeks for arthritic pain. Because he has a normal hemoglobin value, and no nausea, vomiting, or blood per rectum, you are preparing to discharge the patient on Protonix (a proton pump inhibitor to decrease gastric acid) and follow up with his primary care physician when his serum chemistry comes back. His K is elevated at 6.2 mEq/L.

What's the revised diagnosis?

Hyperkalemia

Above what value is hyperkalemia defined?

>5.2 mEq/L

What symptom of hyperkalemia might he describe?

Weakness

What should you do first?

Rule out lab error by repeating test and obtain an EKG

What can cause lab error (pseudohyperkalemia)?

High K readings in blood specimens that do not reflect the true K level in vivo. This may be seen in thrombocytosis, due to release of platelet K in the clot formed in a red-top tube; difficult venipuncture or hemolysis.

What EKG findings of hyperkalemia will you look for?

At first, peaked T waves, with a short QT interval, followed by widened QRS complexes and loss of the P wave, culminating in a "sine wave" pattern, which leads rapidly to ventricular fibrillation or asystole. This progression may proceed rapidly.

If hyperkalemia is confirmed, what's your approach?

Treat the hyperkalemia first then proceed with your workup.

What's the treatment for asymptomatic (no EKG changes) patients?

Five to 10 units of insulin and 25–50 cc D50 glucose (shifts K into cells) and 30–60 g of Kayexalate by mouth (promotes GI loss of K). Hemodialysis is effective in cases of renal failure.

What additional therapy is needed if EKG changes are present?

Calcium gluconate 10% 10 cc, repeat as needed to reverse EKG changes. This does *not* lower serum K, it stabilizes the myocardium and counters arrhythmias.

What can cause hyperkalemia (not pseudohyperkalemia)?

Excessive K intake, decreased renal excretion, redistribution

Give some common examples of each.

Excessive K intake

K replacement therapy, high-K diet

Decreased renal excretion

K-sparing diuretics (e.g., spironolactone, triamterene, amiloride), renal insufficiency, type 4 RTA, ACE inhibitors, heparin, NSAIDs, β -blockers

Redistribution (excessive cellular release)

Insulin deficiency, hemolysis, tissue necrosis, rhabdomyolysis, and burns

What's the mechanism of hyperkalemia in the following medications?

β -blockers

Inhibits renin release and blocks cellular uptake of K if nonselective

ACE inhibitors

Blocks angiotensin II production

Angiotensin receptor blockers and spironolactone?

Inhibits aldosterone

Heparin

Blocks adrenal synthesis of aldosterone

NSAIDs

Reduces renin release

Amiloride and triamterene

Blocks renal K excretion

Once redistribution has been ruled out as a cause, what test should be ordered next?

Transtubular K gradient (TTKG)

What is TTKG?

The TTKG is given by the formula

$$[U_K / (U_{osm} / P_{osm})] / P_K$$

It estimates what the urine-to-plasma K gradient would be at the end of the distal tubule, prior to the concentrating segments of the nephron, and as such corrects for the effects of urinary concentration on interpreting urinary K.

How is it useful?

A normal value is 6–9; a lower value in hyperkalemia suggests hypoaldosteronism or impaired renal response to aldosterone.

What is type IV RTA?

Hyperkalemia with inadequate renal K excretion despite only mild to moderate CRF, also called tubular hyperkalemia, overlaps with hyporeninemic hypoaldosteronism. Seen in diabetes, chronic interstitial nephritis, systemic lupus erythematosus (SLE), sickle cell disease, obstructive uropathy. May be because of combination of low renin production, reduced aldosterone synthesis, and impaired tubular response to aldosterone; the latter cause is most common.

GLOMERULAR DISEASES

CASE 7

A 12-year-old girl presents to the clinic with new onset of hypertension, peripheral edema, joint pain, and dark urine over the last few days. Recently she had a sore throat for which she was given an over-the-counter herbal remedy and Tylenol.

What do you suspect?	Nephritic syndrome secondary to post group A β -hemolytic <i>Streptococcus</i> infection
What's the differential for nephritic syndrome?	Post group A β -hemolytic <i>Streptococcus</i> infection, SLE, vasculitis (Wegener granulomatosis, polyarteritis nodosa), idiopathic glomerulonephritis (membranoproliferative, idiopathic, crescentic, IgA nephropathy), Goodpasture syndrome, Henoch-Schönlein purpura (HSP)
What is nephritic syndrome?	Acute or subacute glomerulonephritis manifesting with hematuria and red blood cell casts
Why do you suspect post-streptococcal GN (PSGN) in this patient?	Sore throat preceded nephritis signs
What usually causes PSGN?	Nephritogenic strains of group A β -hemolytic <i>Streptococcus</i> . The infection may be pharyngitis, or, more commonly worldwide, impetigo.
Describe the classic presenting features in PSGN	Gross hematuria (described as “Coca-Cola urine”), edema, hypertension
Goodpasture syndrome	Acute GN signs and pulmonary involvement, often with frank hemoptysis
Wegener granulomatosis	Epistaxis and sinusitis are common presentations in addition to nephritic signs
IgA nephropathy (also known as Berger disease)	Male with loin pain and gross hematuria shortly after pharyngitis (viral), with spontaneous resolution until the next episode
HSP	Palpable purpura and GI involvement

What physical exam finding may be found in patients with nephritic syndrome?

Hypertension, edema (peripheral, periorbital, or pulmonary), joint pains, dark urine, malar rash (in SLE), palpable purpura (in patients with HSP), heart murmurs (suspect endocarditis), pharyngeal erythema (group A β -hemolytic *Streptococcus* infection)

What initial labs should be ordered to confirm nephritis syndrome?

Urinalysis, serum Cr, BUN, 24-hour urine for protein excretion and Cr clearance

What results are consistent with GN?

Urinalysis

Hematuria (dysmorphic erythrocytes and red cell casts) and proteinuria

24-hour urine for protein excretion

500 mg/day to 3 g/day

Are RBC casts pathognomonic of GN?

No. They may be seen in acute interstitial nephritis and, rarely, after vigorous exercise. In the correct clinical setting, however, they are very strong evidence for GN.

Are RBC casts always seen in GN?

No. After formation in the tubular lumen, they degenerate fairly quickly, forming pigmented coarse granular casts. RBC casts are always accompanied by free RBCs, which, to the trained observer, are dysmorphic, suggesting glomerular origin. Often, several urine specimens need to be examined to demonstrate RBC casts.

What additional tests should be ordered if the following is suspected as the cause of the GN?

PSGN

Streptococcal tests (Streptozyme), ASO quantitative titer

SLE

Anti-DNA antibodies

Wegener granulomatosis	c-ANCA
Pauci-immune RPGN (Wegener disease, Churg- Strauss disease, and microscopic polyarteritis nodosa)	P-ANCA
Goodpasture syndrome	Anti-GBM antibody
IgA nephropathy (a.k.a. Berger disease)	Serum IgA level
What utility does renal ultrasound have in the workup?	Estimates kidney size, which helps distinguish between acute and chronic renal disease
What's the general acute treatment for nephritic syndrome?	Correction of electrolyte abnormalities and acidosis if present. Treat hypertension with furosemide, hydralazine, or nifedipine.
What additional treatment is recommended for PSGN?	Treatment of streptococcal infection with penicillin (or erythromycin in penicillin-allergic patients)
Goodpasture syndrome?	Plasmapheresis, followed by prednisone and cyclophosphamide
Wegener granulomatosis?	Steroids and cyclophosphamide. Plasmapheresis is not well established here.
IgA nephropathy?	ACE inhibitors and fish oil. Steroids and cytotoxic agents are reserved for cases with nephrotic syndrome and/or progressive azotemia.
P-ANCA-positive RPGN?	Pulse methylprednisolone (often with cyclophosphamide or azathioprine)

CASE 8

A 44-year-old with diabetic retinopathy and neuropathy calls your office while you are on-call, complaining of ankle swelling and puffiness around the eyes. She denies chest pain, abdominal swelling, or shortness of breath with exertion.

What known complication of diabetes should you be concerned about in this patient?

Nephrotic syndrome

What other prior complication of diabetes does she have that is almost always associated with nephritic syndrome?

Retinopathy

What are some of the symptoms of nephrotic syndrome?

Swelling, foaming of the urine. Nonspecific findings may include fatigue. The underlying illness (e.g., DM, SLE) may produce additional symptoms.

What are common signs of nephrotic syndrome?

The hallmark sign is edema, which may just be dependent (ankles at the end of the day) or generalized anasarca, including periorbital edema. Ascites and pleural effusions may be present. Additional signs may be present attributable to the underlying disorder.

What are the known primary and secondary causes of nephritic syndrome?

Primary

Focal segmental glomerulosclerosis, membranous nephropathy, minimal change disease, membranoproliferative glomerulonephritis, and IgA nephropathy

Secondary

Diabetes, SLE, amyloid, drugs/toxins (penicillamine, gold, NSAIDs, heroin, ACEI), infections (HBV, HCV, syphilis), malignancy

Is there a unifying mechanism leading to these phenomena?

The loss of albumin through the pathologically leaky glomerular basement membrane leads to hypoalbuminemia. The resulting fall in plasma oncotic pressure leads to increased hepatic synthesis of cholesterol, sodium retention by the kidneys, and the development of edema. The kidneys also lose other proteins, such as opsonins, and clotting factors.

What's the basic workup?

Spot urine for protein and urine sediment, 24-hour protein, serum albumin, glucose

What results do you expect for

Urinalysis?

Elevated protein

Urine sediment?

Oval fat bodies, free fat droplets, and fatty casts. Refractile bodies (Maltese cross appearance) may be seen. The sediment *may* also contain nephritic (q.v.) elements.

Serum protein?

<3 g/dL

24-hour urine protein?

At least 3.5 g/24 hours (confirms nephritic syndrome)

What additional lab test should be ordered in a diabetic?

HgA1c (assess diabetic control over last 3 months)

What additional tests should be ordered when the cause is unclear (not diabetes or drug/toxin related)?

ANA, SPEP (if suspect myeloma), complement (C3, C4, CH-50), LDH, hepatitis B and C screening, and HIV

What's the final step in the workup?

Renal biopsy (confirms the diagnosis)

What is the general therapy?

Avoidance of nephrotoxic drugs and treat underlying secondary cause if found, Na restriction and diuretics for edema, support hose for legs

What medication should be considered to decrease proteinuria and progression to ESRD in diabetic and nondiabetic nephropathy with moderate to severe proteinuria?

ACE inhibitor

What therapy may be considered for primary glomerular disease?

Steroids and cytotoxic therapy (e.g., cyclophosphamide, chlorambucil)

FLANK PAIN

CASE 9

A 32-year-old previously healthy female presents to your clinic complaining of nausea, vomiting, dysuria, and sudden onset of severe flank pain.

What's your differential diagnosis?

UTI, nephrolithiasis, pyelonephritis, diverticulitis, PID, ovarian pathology, appendicitis, small bowel obstruction, ectopic pregnancy

Further questioning reveals that the pain radiates to the groin. What's the most likely diagnosis?

Nephrolithiasis

How does the stone patient typically present?

With renal colic characterized by severe, intermittent, unilateral flank pain lasting 20–60 minutes that radiates to the groin or testicle; dysuria, frequency, nausea, vomiting, and gross hematuria may also be present

Name the 4 major types of kidney stones.

Calcium oxalate, uric acid, struvite, and cystine

What is the most common type?

Calcium oxalate

What endocrine disorder is a risk factor for developing calcium oxalate stones?

Hyperparathyroidism

Which type of stone is associated with urea-splitting bacteria (*Pseudomonas*, *Proteus*, *Klebsiella*) and high urinary pH?

Struvite

What basic diagnostic tests are included in the workup?

Urinalysis, BUN, Cr, serum calcium, KUB x-ray, and CBC (if febrile). Further metabolic workup, including urine collections, are deferred until patient has recovered from acute episode and has returned to usual diet.

What type of stone is not seen on x-ray?

Uric acid stones

What additional diagnostic test may be ordered if suspicion is high in patient with normal renal function and KUB?

Intravenous pyelogram, which has been the gold standard, although CTT scanning may replace it

What test may be useful if obstruction is suspected?

Renal ultrasound, which may also detect radiolucent stones missed on KUB

What is the treatment?

Hydration [oral or intravenous (IV)] and analgesics (narcotics or NSAIDs) as needed for pain

What additional treatment is required if infection is present?

IV antibiotics and aggressive workup for obstruction

What treatment should be considered if an upper tract stone does not pass?

Extracorporeal shock wave lithotripsy to break up stone into smaller fragments, which will then be able to pass

What treatment may be useful if stone is located in the lower urinary tract?

Surgical extraction per cystoscopy

CASE 10

A 78-year-old nursing home patient with history of dementia, DJD, and urinary incontinence with an indwelling Foley catheter presents to the ER with an acute worsening of her mental status, fever of 103°F, chills, nausea, vomiting, and complaints of severe right flank pain.

What diagnosis do you suspect?	Pyelonephritis with likely urosepsis
What major risk factor did this patient have for pyelonephritis?	Indwelling catheter
What other risk factors for pyelonephritis are there?	Urinary tract obstruction, stasis, DM, immunocompromised state, and nephrolithiasis
Does pyelonephritis commonly present like this?	Yes, it often presents with sudden onset of fever, chills, nausea, vomiting, and flank pain with or without concomitant UTI symptoms
What physical exam finding would support your diagnosis?	Right costovertebral tenderness
What labs should you order and why?	UA with culture and sensitivity (confirm infection), blood cultures (assess for bacteremia and aid in future antibiotic selection), CBC with differential (to rule out leukocytosis), Chem 8 (to rule out dehydrated or electrolyte abnormalities)
Can you get the UA from the indwelling Foley?	No, it will be colonized with bacteria; a straight catheter specimen or clean catch specimen must be obtained.
What results do you suspect in the UA?	Elevated leukocyte esterase, nitrates, and WBC casts in the urinalysis
Blood cultures?	Gram-negative rods

Lab tests come back positive for UTI and GNR bacteremia. What noninvasive test can aid in diagnosing pyelonephritis?

Renal ultrasound

Renal ultrasound is positive for right ureter and calyx dilatation consistent with pyelonephritis. What's your diagnosis?

Urosepsis secondary to pyelonephritis secondary to UTI from indwelling catheter (possibly partially obstructed)

Which GNR do you suspect?

E. coli (often ascends from the lower urinary tract)

What is the treatment?

Remove indwelling catheter, IV fluoroquinolone (ciprofloxacin) or third-generation cephalosporin (ceftriaxone) for 1 to 2 days followed by oral ciprofloxacin for 2 weeks

MISCELLANEOUS DISORDERS

CASE 11

A 57-year-old previously healthy male presents with insidious onset of difficulty with urination. He states it is difficult to start urinating and has taken progressively longer to drain his bladder. At first, it was not bothersome, but now he is going to the bathroom twice as often.

What's your differential diagnosis?

Benign prostatic hypertrophy (BPH), diabetes, urologic cancer, calculi, UTI, stricture disease, and a neurologic disorder

Which do you suspect?

BPH

Why?

BPH often presents with urinary obstruction symptoms (hesitancy, decreased stream strength, dribbling, urinary retention, and sense of incomplete emptying).

What causes BPH?

A benign adenomatous hyperplasia of the prostate gland that compresses the prostatic urethra, resulting in decreased urine flow

What physical exam finding would support your suspicion?	An enlarged prostate
What lab tests should you order and why?	UA (UTI?), BUN/Cr ratio (renal failure?), PSA (prostate cancer?), post-void residual volume (overdistended bladder?)
Enlarged prostate is found on PE and above labs are normal. Do you still suspect BPH?	Yes
What diagnostic test can you order to confirm your diagnosis?	Transrectal ultrasound (increased sensitivity)
What is the initial treatment?	α -Blockers (e.g., prazosin, terazosin) to inhibit urinary bladder sphincter contractions and hormone therapy (5- α reductase) to inhibit prostatic conversion of testosterone to dihydrotestosterone, which reduces prostate size
What is the next step if medical intervention fails?	Surgery with transurethral prostatectomy

CASE 12

A 37-year-old obese diabetic female at 30 weeks gestation presents to the office complaining of burning on urination.

What's your differential diagnosis?	UTI, vaginitis, pyelonephritis
Which is most likely?	UTI
Why are the following less likely?	
Vaginitis	Often has vaginal discharge

Pyelonephritis

No fever, nausea, vomiting, chills, elevated temperature, or CVA tenderness

What additional questions would you want to ask to support a diagnosis of UTI?

Any increased urinary frequency, urgency, nocturia, suprapubic pain, hematuria, or history of UTI

What risk factors does she have for a UTI?

DM and pregnancy

Name other UTI risk factors

Recent sexual activity (worth asking about), congenital urologic abnormalities, immunocompromised states

Who is at greatest risk of UTIs?

Sexually active women

What physical exam signs of UTI may be present?

Suprapubic pain (common) and fever (uncommon)

What's the workup?

First-line test

UA

What values are diagnostic of a UTI?

Positive leukocyte esterase, increased nitrates, increased pH

What is the next test if the UA is positive?

Urine culture with sensitivities

What bacterial count is diagnostic of a UTI?

A single species with >100,000 bacteria/mL

Which Gram stain finding and organism are most common?

Gram-negative bacteria, *E. coli*

What's the treatment?

First-line

A 3–7 day oral course of trimethoprim-sulfamethoxazole

If sulfa allergy?

Amoxicillin or ciprofloxacin

CASE 13

An 18-year-old female with history of UTIs, cervical HPV, drug abuse, and 2 prior abortions presents to your office complaining of painful urination and purulent vaginal discharge.

What's your differential diagnosis?	UTI, urethritis, candidiasis
What diagnosis do you suspect?	Urethritis
Why?	Vaginal discharge is common in urethritis and patient has risk factors for it [multiple sexual partners, UTIs, drug abuse, and STDs (cervical HPV)]
What two organisms cause urethritis in women?	Gonococcal (GC) or nongonococcal (NGC)
What symptoms may occur in both?	UTI symptoms (increased frequency, urgency, and dysuria)
Which infectious organism is most likely in this patient?	GC urethritis because the discharge is purulent (NGC is often described as thin, clear to white scanty discharge)
What lab tests should you order?	UA, culture, and Gram stain of urethral discharge (or cervical mucus in women)
What's your diagnosis if the lab reports Gram-negative intracellular diplococci in WBCs or positive Thayer-Martin culture?	GC urethritis
Negative Gram stain?	NGC urethritis
What causes GC urethritis?	<i>Neisseria gonorrhoeae</i>

What causes NGC urethritis?

Chlamydia trachomatis and Ureaplasma urealyticum

Ironically, what is the treatment strategy?

Treat both GC and NGC because of high incidence of coinfection

So, what is the treatment?

Ceftriaxone (for GC) and doxycycline, tetracycline, or Zithromax (for NGC)

What are patients at risk for without treatment?

Urinary strictures, PID, and infertility

Chapter 5

Endocrine Disorders

DIABETES MELLITUS

CASE 1

A 12-year-old female presents to her physician with her mother after abnormal behavior concerning for anorexia. The mother states that over the last 2 weeks her daughter has lost weight while eating and drinking more than usual and she goes to the bathroom frequently. The mother, a recovering anorexic herself, is worried her daughter has the disease. The daughter says she feels fine, but has noticed her vision is blurred once and a while.

What's your differential diagnosis?

Diabetes insipidus, diabetes mellitus (DM), stress hyperglycemia, diabetes secondary to hormonal excess, drugs, pancreatic disease, anorexia

What are you most concerned about?

DM

Why?

Age under 30 and an abrupt onset of weight loss, polydipsia, polyphagia, and polyuria is most concerning for DM.

Which type?

Type 1

What are other names for it?

Insulin-dependent DM and juvenile onset diabetes

What's the mechanism of type 1 diabetes?

Hyperglycemia secondary to relative or complete lack of insulin secretion by the β cells of the pancreas

What damages the insulin receptors?

Islet cell antibodies (found in 90% of patients within the first year of diagnosis) and viral infections (mumps and Coxsackie virus) have been suggested.

What basic labs should you order?

Chem 8 (assess electrolytes, dehydration, kidney function, and glucose level)

How is it diagnosed in**Asymptomatic patients?**

Either by a fasting plasma glucose greater than 126 mg/dL on two separate occasions or by a positive 2-hour oral glucose tolerance test (2 values at 2 hours exceed 200 mg/dL)

Symptomatic patients?

Presence of symptoms (weight loss, polyuria, etc.) with a random plasma glucose greater than 200 mg/dL

What is the initial treatment?

Diabetic diet (60% carbohydrates, 15% protein, and 25% fat not exceeding 35 kcal/kg/day) and physical activity to attain ideal body weight

How is the DM monitored?

Numerous daily capillary blood glucose measurements

What are the recommended fasting, preprandial, and postprandial glucose levels?

Fasting and preprandial between 70 and 120 mg/dL and postprandial less than 160 mg/dL

What lab test is used to assess glycemic control over the last 4 weeks?

Glycosylated hemoglobin A₁C

What is the next therapy in type 1 DM?

Insulin

What chronic conditions are they at risk of with poor disease management?

Signs of end-organ complications (retinopathy, neuropathy, peripheral vascular disease, macrovascular disease, nephropathy, foot disease, and depression)

CASE 2

A 45-year-old female with history of hypertension, obesity, and recently diagnosed hyperlipidemia visits your office 6 weeks after starting her lipid-lowering medication after failing diet and exercise. Her LDL value is much improved, but her glucose value is 140.

What new diagnosis might she have?	DM
Which type?	Type 2
How does type 2 DM present?	Often in obese patients after the age of 40 with gradual onset of symptoms (polyuria, polyphagia, polydipsia, and weight loss) or with an abnormal lab test
What's the basic mechanism causing the disease?	Defects in insulin receptors
What are some common secondary causes of DM?	Medications (steroids, thiazide diuretics, etc.) and pancreatic insufficiency
Which type of DM has a stronger genetic predisposition?	Type 2 greater than type 1 owing to 90% concordance rate in monozygotic twins
How is the diagnosis made in Asymptomatic patients?	Either by a fasting plasma glucose greater than 126 mg/dL on two separate occasions or by a positive 2-hour oral glucose tolerance test (2 values at 2 hours exceed 200 mg/dL)
Symptomatic patients?	Presence of symptoms (weight loss, polyuria, etc.) with a random plasma glucose greater than 200 mg/dL
What is the initial treatment?	Diabetic diet (60% carbohydrates, 15% protein, and 25% fat not exceeding 35 kcal/kg/day) and physical activity to attain ideal body weight
How is the DM monitored?	Numerous daily capillary blood glucose measurements
What are the recommended fasting, preprandial, and postprandial glucose levels?	Fasting and preprandial between 70 and 120 mg/dL and postprandial less than 160 mg/dL

What lab test is used to assess glycemic control over the last 4 weeks?

Glycosylated hemoglobin A₁C

What is the next therapy in type 2 DM?

Oral hypoglycemic agents such as metformin (Glucophage) and acarbose (Precose) followed by insulin if needed

What additional appointments should be made for recently diagnosed diabetics?

Dietary consult, yearly eye and foot exams

CASE 3

A 38-year-old female with history of COPD, hypertension, and type 1 diabetes with retinopathy and renal insufficiency secondary to poor compliance with her insulin regimen is brought to the ED by her husband saying that she was complaining of similar symptoms when her diabetes was diagnosed, but also had some nausea and vomiting and vague abdominal pain. Within the last few hours she has begun to breath rapidly with a fruity smell to her breath and seems to be a bit confused.

What is most likely causing this patient's symptoms?

Diabetic ketoacidosis (DKA)

What's in the differential diagnosis when considering DKA?

Salicylate poisoning (aspirin overdose), metabolic acidosis from methyl alcohol, ethylene glycol ingestion, uremic acidosis, alcoholic ketoacidosis

How does DKA often present?

Polyuria, polydipsia, unexplained weight loss, vomiting, and vague abdominal pain followed by hyperventilation (Kussmaul sign), shock, and coma if untreated

Why does DKA occur?

Extremely low levels of insulin lead to hyperglycemia, hyperglucagonemia, increased stress hormones, and ketoacid production by the liver

Is it more common in type 1 or type 2 diabetes?

Type 1

Why is it less common in type 2 diabetics?	They usually make enough insulin to prevent DKA from developing.
What is the most likely cause in this patient?	Noncompliance with her insulin regimen
What were the clues to non-compliance in the patient?	Patient has developed at least two chronic complications from her underlying disease, which suggests poor disease control and possible noncompliance with taking her insulin
What other triggers to DKA must be considered?	Stress (often infection), MI, or CVA
What might the PE reveal in DKA patients?	Altered mental status, fruity breath odor (from acetone), signs of dehydration (tachycardia, dry mucous membranes, poor skin turgor), tachypnea (Kussmaul respiration), evidence of infection (e.g., diabetic ulcer, pneumonia, pyelonephritis)
What should you order? Labs	STAT Accu-Chek, serum electrolytes, serum ketones, arterial blood gas, CBC, and blood cultures (if infection suspected)
Tests/imaging	EKG to evaluate possible MI or hyperkalemia, and CXR if infection is suspected
How is it diagnosed?	Hyperglycemia, hyperketonemia, and metabolic acidosis with an elevated anion gap
What is the treatment?	Admit for IV fluids and insulin, K supplementation as needed

CASE 4

A 55-year-old male with history of GERD, esophagitis, hypertension, and diabetes is admitted to the hospital for confusion and an Accu-Chek of 850 without an anion gap.

What's his most likely diagnosis?	Nonketotic hyperosmolar coma
Does this occur in type 1 or type 2 diabetics?	Type 2
How does it present?	Polyuria, polydipsia, lethargic, obtunded, or coma with severe hyperglycemia (600 to 2000 mg/100 mL) and dehydration
How is it distinguished from DKA?	Absence of ketoacidosis (no fruity breath or hyperventilation)
Why does ketoacidosis not occur?	Type 2 diabetics make enough insulin to prevent lipolysis and ketoacid production.
What causes the symptoms in nonketotic hyperosmolar coma?	Hyperglycemia, dehydration, and hyperosmolality
What can precipitate it?	Stress, stroke, excessive carbohydrate intake, or infection
What might be found on physical exam?	Altered mental status, signs of dehydration (tachycardia, dry mucous membranes, poor skin turgor), evidence of infection (e.g., diabetic ulcer, pneumonia, pyelonephritis), or stroke
What should you order?	
Labs	STAT Accu-Chek, serum electrolytes, serum ketones, arterial blood gas, CBC, and blood cultures (if infection suspected)
Tests/imaging	EKG to evaluate possible MI or hyperkalemia, and CXR if infection is suspected
How is it diagnosed?	Hyperglycemia without elevated serum ketones or anion gap
What is the treatment?	IVF and parenteral insulin with rigorous blood glucose monitoring

What electrolyte abnormality are patients at risk for with insulin? Hypokalemia

What is the treatment? Potassium supplementation

DISEASES OF THE THYROID AND PARATHYROID GLAND

CASE 5

A 72-year-old male with history of psoriasis, gout, and dementia presents to the clinic for routine checkup and complains of intermittent anxiety, sweating, fatigue, headache, and mild confusion. The symptoms occur usually in the morning and after he takes his medications, which include insulin, hydrochlorothiazide, aspirin, and Lipitor. The symptoms lessen after eating breakfast.

What are the patient's symptoms consistent with? Hypoglycemia

What are the symptoms and signs of

Mild hypoglycemia? Anxiety, diaphoresis, tachycardia, lethargy, confusion, and headache

Severe hypoglycemia? Mild symptoms followed by seizure, stupor, coma, or focal neurologic findings

How is the diagnosis of hypoglycemia made? Hypoglycemic symptoms with a low glucose level that are relieved with treatment

What's the differential diagnosis for hypoglycemia? Insulinoma, insulin use, sulfonylurea use, postgastrectomy patients

Which is most likely in this patient? Insulin use

What labs are ordered when the cause is unclear? Plasma insulin level, insulin antibodies, plasma/urine sulfonylurea levels, C-peptide

What's the diagnosis with High plasma insulin level with insulin antibodies? Exogenous insulin use

Plasma or urine sulfonylurea levels positive?	Oral sulfonylurea use
Elevated C-peptide?	Insulinoma
What is the treatment for Mild hypoglycemia?	Oral carbohydrates (fruit, fruit juice, crackers, etc.)
Severe hypoglycemia?	IV D ₅₀ solution or SC/IM glucagon if IV access is not available
Diabetic and drug-related cause?	Adjust drug therapy, diet, and physical activity
Insulinoma?	Pancreatic spiral CT, arteriography, or ultrasonography (transabdominal and endoscopic) to localize lesion followed by surgical referral

CASE 6

A 62-year-old woman with history of diabetes, bipolar disorder controlled with lithium, COPD secondary to lung cancer, atrial fibrillation controlled with amiodarone, esophageal cancer s/p chemotherapy and radiation presents to clinic with complaints of fatigue, weight gain, and slow bowels. You notice she is wearing a fall coat in the summer. She says it helps her keep warm.

What underlying disease do you suspect?	Hypothyroidism
How does it present?	Often nonspecific symptoms including cold intolerance, fatigue, weight gain, paresthesias (hand and feet), constipation, muscle weakness, muscle cramps, arthralgias, and hoarseness
What is it?	A hypometabolic condition that results from a decrease in thyroid hormone at the cellular level
What risk factors does she have?	History of prior neck radiation and surgery, drugs (amiodarone and lithium can cause hypothyroidism)

What other risk factors may be presented to you?	Other drugs (iodine, α -interferon and interleukin-2), Hashimoto thyroiditis, and pituitary disease
What is a clue that a patient may have received iodine?	Recent radiographic imaging using contrast dye (some contain iodine)
What physical exam findings support hypothyroidism?	Bradycardia, hypothermia, periorbital edema, dry skin, nonpitting edema, and decreased tendon reflexes (prolonged relaxation)
What's the best single screening test for hypothyroidism?	TSH
What result do you expect?	High plasma TSH
What additional test confirms primary hypothyroidism?	Decreased free T4 or FTI (free thyroxine index)
How is secondary hypothyroidism (pituitary disease) diagnosed?	Normal TSH with a decreased T4 index
What is the treatment?	Thyroxine (T4; Synthroid, Levothroid, Levoxyl), start at 50–100 $\mu\text{g/day}$ unless elderly or CAD and then start with 25 $\mu\text{g/day}$ and slowly taper up until TSH level is normalized
What is a possible complication of hypothyroidism?	Myxedema crisis
What can cause it?	Infection (common), trauma, and cold exposure
How does it present?	Hypothermia, hyporeflexia, bradycardia, hypotension, hyponatremia, and hypoventilation
What is the treatment?	IV thyroxine
What additional treatment is suggested in secondary hypothyroidism?	Hydrocortisone (decreases risk of concomitant adrenal insufficiency)

CASE 7

A 41-year-old previously healthy female comes to your office with her husband complaining of feeling nervous and anxious along with a periodic heart pounding in her chest, difficulty sleeping, and feeling hot all the time. Her husband adds additional concerns that her eyes are bulging out and she has nonpitting leg swelling over her shins.

What do you think she has?	Hyperthyroidism
What is it?	A disease characterized by excess free-thyroid hormone in the body due to a hyperfunctioning thyroid gland
What are some common symptoms?	Palpitations (heart pounding), anxiety, nervousness, insomnia, heat intolerance, increased sweating, weight loss, hair loss, and frequent bowel movements
What's the differential diagnosis for hyperthyroidism?	Graves's disease, excess medication, toxic nodular goiter, thyroiditis, and cancer (papillary type most common in the thyroid gland, as well as TSH-secreting pituitary tumors)
What is the most common cause?	Graves disease (γ -immunoglobins bind to TSH receptors)
Who is at increased risk of Graves's disease?	Middle-aged women
What clues in the presentation help you narrow your differential diagnosis?	Eyes bulging (exophthalmus) and nonpitting leg swelling (pretibial myxedema)
How so?	These physical exam signs are specific to Graves's disease.
What additional signs may be apparent on physical exam?	Goiter, tachycardia, fine tremor, stare, eyelid lag, atrial fibrillation, warm skin, and brisk tendon reflexes
What labs should you order?	TSH, Free T4 or T4 index

What's diagnostic of hyperthyroidism?	Low TSH (less than 0.1 $\mu\text{U/mL}$) and high T4 or T4 index
What diagnostic tests can be ordered if cancer is suspected?	Fine needle aspiration and thyroid scans
What is the pharmacologic therapy for hyperthyroidism?	Long-term therapy with the antithyroid drugs methimazole and PTU
What is their mechanism of action?	While both inhibit thyroid hormone synthesis, PTU also inhibits conversion of T4 to T3.
What nuclear medicine therapy is available?	One or 2 doses of radioactive iodine (RAI) to impair thyroid hormone synthesis over the next several months
What surgical treatment is available when medical therapy fails or patient refuses RAI therapy?	Subtotal thyroidectomy
What is the dreaded complication of Graves's disease?	Thyroid storm (often triggered by stress or infection), a medical emergency
How does thyroid storm present?	Fever, tachycardia, weakness, delirium, and shock
What is the treatment?	IV fluids, steroids, PTU, potassium iodide, and a β -blocker

CASE 8

A 71-year-old female is brought to the doctor by her son after he noticed a letter sent to his mother regarding an endocrine health fair she attended where various screening tests were performed for free in an effort to offer enrollment to patients in experimental studies. The letter informed her she should see her doctor due to an elevated calcium and PTH. She informs you she feels fine and saw no reason to bother you with this. She only went to the health fair to have her arthritic knees evaluated.

What's her most likely diagnosis?	Primary hyperparathyroidism
Is her presentation consistent with the diagnosis?	Yes, most often patients are asymptomatic middle-aged or elderly women with an abnormal screening test, but some present with “painful bones, renal stones, abdominal groans, and psychic overtones” if PTH is >13 mg/dL.
What hormone causes primary hyperparathyroidism?	Increased PTH secretion resulting in hypercalcemia
What's the most common cause?	Parathyroid adenoma
What are less common causes?	Parathyroid hyperplasia or carcinoma
What should be done first?	Confirm the diagnosis
What labs should be ordered?	Serum PTH, calcium, and phosphorus at a minimum
What is the diagnosis made?	Hypercalcemia (on at least 2 occasions), hypophosphatemia, and elevated PTH
What additional laboratory finding may be found?	Elevated alkaline phosphatase (in patients with significant bone disease) and hypercalciuria
What radiographic imaging should you order?	Neck ultrasound and CT to look for parathyroid adenomas
What is the treatment if serum calcium rises above 13 to 15 mg/dL or patient is symptomatic?	IVF and furosemide, parenteral salmon calcitonin, pamidronate (bisphosphonate with antiresorptive properties), mithramycin (inhibits bone resorption), and phosphate
What is the definitive treatment for patients with serum calcium levels above 11 mg/dL?	Parathyroidectomy

CASE 9

A 68-year-old female with history of diabetes, gout, and thyroid cancer s/p partial thyroidectomy presents with slow onset of tingling of her lips and fingers 3 weeks after surgery. Her husband thinks it's related to her uncontrolled diabetes.

What do you think?	More likely to be hypoparathyroidism secondary to accidental removal of parathyroid glands during thyroid surgery causing hypocalcemia
What other conditions can cause hypocalcemia?	Renal insufficiency, hypoalbuminemia, vitamin D deficiency, hypomagnesemia, pancreatitis, hyperphosphatemia, pseudo-hypoparathyroidism, autosomal recessive causing end-organ resistance to PTH, sepsis, large blood transfusion (from EDTA in blood)
Describe the following signs on physical exam that suggest hypocalcemia.	
Chvostek sign	Tapping cheek results in facial twitch
Trousseau sign	Carpal spasm occurs just minutes after blood pressure cuff is inflated
What basic labs should you order?	Chem 8, phosphorus, albumin, and PTH
What result is diagnostic of hypoparathyroidism?	Low PTH and Ca with high phosphorus
What's the treatment?	Ca and vitamin D supplementation

MISCELLANEOUS DISORDERS

CASE 10

A 13-year-old previously healthy Caucasian boy presents to your clinic with history of progressive weakness and weight loss. His mother thinks it's related to his decreased appetite. You notice the child appears quite tan and is orthostatic on vital signs.

What do you suspect?	Primary adrenocortical insufficiency
What's the etiology?	Insufficient steroid output from the adrenal cortex due to a disease of the adrenal glands (primary failure) or to disorders of the pituitary or hypothalamus (secondary failure)
How does it commonly present?	Anorexia, nausea, vomiting, weakness, weight loss, fatigue
What clues in the presentation helped narrow your differential diagnosis and specify primary adrenal failure as the most likely cause?	Hyperpigmentation (due to excess ACTH) and orthostasis indicating volume depletion (due to hyponatremia secondary to aldosterone deficiency)
Why does hyperpigmentation occur in primary disease?	ACTH and melanocyte-stimulating hormone (MSH) are derived from the same precursor, so when ACTH production goes up, so does MSH, which leads to hyperpigmented skin
What additional features may only occur in primary adrenal failure?	Hypoglycemia and hyperkalemia
What presentation in the ER should significantly increase your suspicion of primary adrenocortical insufficiency?	A hypotensive orthostatic patient with hyperpigmentation who fails to respond to fluids and has hyponatremia, hyperkalemia, or hypoglycemia of unknown etiology
What's the differential diagnosis for causes of Primary adrenal failure?	Autoimmune destruction (Addison disease most common), infection (HIV, fungal, tuberculosis), hemorrhagic adrenal infarction (anticoagulant therapy), metastasis
Secondary adrenal failure?	Glucocorticoid therapy and pituitary failure due to a disease process or surgery (two most common causes)

Who is at increased risk of secondary causes of adrenocortical insufficiency?	AIDS patients (disseminated infection or ketoconazole treatment) or steroid-dependent patients with abrupt withdrawal of their exogenous steroids
What initial labs should you order?	Chem 8, CBC, 24-hour urinary cortisol, 17-OHCS, 17-KS, and ACTH
What findings support the diagnosis of adrenal insufficiency on Chem 8?	Increased K^+ , decreased Na^+ and Cl^- , decreased glucose, increased BUN:creatinine ratio (prerenal azotemia)
CBC?	Mild normocytic, normochromic anemia
24-hour urinary cortisol, 17-OHCS, and 17-KS?	Decreased
ACTH?	Increased in primary adrenocortical insufficiency
How is it diagnosed?	Inadequate response to Cortrosyn (ACTH) stimulation test (cortisol level does not increase after administration of ACTH)
What lab results distinguish primary and secondary causes?	Primary causes have elevated ACTH and low aldosterone; secondary causes have low ACTH and normal aldosterone
What is the treatment?	Hydrocortisone
What additional treatment is required if hypoaldosteronism exists (primary disease)?	A mineralocorticoid-like fludrocortisone (Florinef)

CASE 11

A 35-year-old female comes to your clinic complaining of fatigue, weakness, and feeling depressed over the last few months. She feels depressed over her appearance. On physical exam you appreciate truncal obesity, rounded face, thin, faint facial hair, acne, a few abdominal striae, and bruises on her arms and legs.

What do these findings suggest?	Cushing syndrome
What is Cushing syndrome?	A syndrome characterized primarily by effects of excess cortisol, although excess mineralocorticoids and androgenic steroids may also be present
What causes it?	Administration of exogenous glucocorticoids (most common) or by excess production of cortisol by the adrenal cortex
What lung disease is associated with Cushing syndrome?	Oat-cell lung cancer can produce ACTH, which stimulates the adrenal cortex to produce excess cortisol
What is Cushing disease?	Excess cortisol production from the adrenal cortex caused by increased ACTH secreted by the pituitary, often from a pituitary microadenoma
What is the best screening test for Cushing syndrome?	A 24-hour urine free-cortisol level (elevated in Cushing syndrome)
What was the test used before 24-hour urine free-cortisol testing became common practice?	1–2 mg overnight dexamethasone suppression test
If the screening test (24-hour urine free-cortisol) is positive, what test is ordered next?	Serum ACTH level
Why?	You're trying to determine if the elevated cortisol level is ACTH dependent (Cushing disease) or independent (e.g., ACTH from lung cancer)
How do you interpret the following results?	
Normal 24-hour urine cortisol and normal ACTH	Not Cushing syndrome

High 24-hour urine cortisol and normal or high ACTH	ACTH-dependent Cushing syndrome
High cortisol with suppressed ACTH	ACTH-independent Cushing syndrome
What additional test is needed in the ACTH-dependent Cushing group?	High-dose dexamethasone test
What are you trying to determine?	Whether the ACTH is produced by the pituitary (Cushing disease) or an ectopic source (e.g., lung cancer)
What lab values indicate a positive high-dose dexamethasone test?	Decreased levels of urinary cortisol or 17-hydroxycorticosteroids following administration of high-dose dexamethasone
What's your diagnosis with a positive result?	Cushing disease
What imaging is ordered for Cushing disease?	CT or MRI of pituitary
ACTH-dependent Cushing syndrome with negative dexamethasone suppression test?	CT or MRI of chest (looking for ectopic ACTH-producing tumors)
ACTH-independent Cushing syndrome?	Adrenal CT or MRI
What's the definitive treatment in all conditions?	Surgery
What's the type of surgery in Cushing disease?	Transsphenoidal microadenectomy
What treatment is available for nonsurgical Cushing disease patients?	Pituitary irradiation

CASE 12

You signed out a 36-year-old female with history of torn right knee ACL s/p surgery years ago who presents to the ER today with her husband. Today she complains of worsening headache over the last few months. At first it was relieved with over-the-counter (OTC) ibuprofen and Tylenol, but over the last few weeks it has become progressively worse and the OTC meds are not helping. She came to the ER today because she developed temporary visual loss and double vision that lasted for 1 hour earlier in the morning. A CT of the head is suggestive of a pituitary or sellar mass lesion.

What can cause this finding?	Benign pituitary adenoma, infiltrative disease, autoimmune phenomena, hypothalamic
Which hormones are usually affected by functioning pituitary tumors?	ACTH, growth hormone (GH), and prolactin (PRL, most common)
Which hormones are rarely affected?	TSH, follicle-stimulating hormone, and luteinizing hormone
Other than calling neurosurgery to review the film, what additional findings would support the CT findings?	Elevated prolactin (hyperprolactinemia), GH (acromegaly), or ACTH (Cushing syndrome) excess
How would hyperprolactinemia commonly present?	Galactorrhea and amenorrhea in women (impotence and loss of libido in men)
How does excess GH present?	Acromegaly in adults resulting in large jaw, forehead, and hands (gigantism in children)
How does excess ACTH present?	Cushing syndrome (see Cushing disease case)
What lab results suggest the diagnosis?	Abnormal level of GH, PRL, or ACTH
What lab test strongly suggests the diagnosis in GH-producing tumors?	Glucose challenge test

What additional diagnostic imaging test will the neurosurgeon recommend?

MRI (preferred over CT)

What medical therapy may be used to control small PRL-secreting adenomas?

Bromocriptine

When is transsphenoidal surgery with or without radiation warranted?

In cases of hormone excess or neurologic symptoms

What additional therapy may be required in hypopituitarism?

Hormone replacement

CASE 13

You're called by the neurosurgery team for a consult on a 24-year-old male who was hospitalized 5 days ago after a severe motor vehicle collision resulting in several bone fractures, including a basilar skull fracture. The consult is for significant imbalance in body fluid input and output. For days he has been making large quantities of dilute urine, which has required up to 6 L of saline to keep up with losses.

What is your differential diagnosis?

Diabetes insipidus, DM, polydipsia, osmotic diuresis (glucose, mannitol, urea)

Which diagnosis do you suspect?

DI

Why?

Large quantity of dilute urine after sustaining significant head trauma (basilar skull fracture) is a risk factor for DI

Name some other risk factors for DI.

Neurosurgical procedures, brain tumors, and drugs (ethanol, phenytoin, or lithium)

Other than polyuria, what do you expect the patient to complain of with DI?

Excessive thirst

What are the two types of DI?	Neurogenic and nephrogenic
What causes neurogenic DI?	Insufficient release of vasopressin by the pituitary
What causes nephrogenic DI?	Distal nephron does not respond to vasopressin
Which is more likely in this patient?	Neurogenic DI
What do you expect to find on physical exam?	Dehydration, hypovolemia with large quantity of urine output recorded by the nurses
How is the diagnosis of DI made?	Dilute urine and increased serum osmolality
What test is ordered to distinguish between central and nephrogenic DI?	Water-deprivation test
What is the treatment for symptomatic neurogenic DI?	The intranasal vasopressin analog desamino-8-D-arginine vasopressin (DDAVP, Desmopressin)
What is the treatment for nephrogenic DI?	Hydration and thiazide diuretics

CASE 14

A 63-year-old male with history of arthritis, carpal tunnel, COPD secondary to smoking, and BPH presents to the hospital after falling off his bike. For months, as part of an exercise program, he has biked 5–10 miles daily down a straight gravel path, but stopped 5 days ago as a result of significant muscle weakness and cramping. In the ER he received a battery of lab tests and a simple CXR. The chemistry panel revealed hyponatremia and the CXR had RML lesion consistent with underlying lung cancer.

What's the most likely diagnosis?	SIADH secondary to underlying lung cancer
--	---

How can SIADH present?	With symptoms of hyponatremia, such as lethargy, muscle cramps, confusion, headache, focal neurologic findings, convulsions, and coma
What's his main risk factor?	Smoking
Which type of lung cancer is this associated with?	Oat-cell carcinoma of the lung
What are some other risk factors for SIADH?	Pulmonary diseases (e.g., pneumonia, tuberculosis), stroke, head lesion (tumor, trauma, infection), and drugs (e.g., chlorpropamide, carbamazepine, and diuretics)
What labs should you order?	Chem 8, serum and urinary osmolality
What are the associated lab findings?	Hyponatremia with a urinary osmolality greater than serum osmolality
How is the diagnosis made?	With the associated lab findings after all other causes have been ruled out (e.g., diuretics, dehydration, anterior pituitary, renal, adrenal, and thyroid disease)
What is the initial treatment?	Correct underlying cause (most likely lung cancer in this case) and fluid restriction

CASE 15

A 55-year-old Asian female with history of emphysema secondary to smoking and RA in remission on methotrexate and prednisone for years presents to the clinic after being discharged from the ER with a wrist fracture after falling in her kitchen.

What underlying disease does she most likely have that put her at risk of the wrist fracture?	Osteoporosis
What risk factors does she have?	Age, postmenopausal, smoker, chronic steroid use, Asian (Hispanics also at increased risk)

What are some secondary causes of osteoporosis?	Hyperthyroidism, hyperparathyroidism, osteomalacia, multiple myeloma, and medications (glucocorticoids most common, as well as T4 overreplacement)
How do most cases present?	Usually asymptomatic until fracture occurs
Which fractures are most common?	Vertebral, wrist (Colles fracture), and hip fractures
What test should you order to diagnose osteoporosis?	Dual-energy x-ray absorptiometry (DXA) bone scan to measure bone mineral density
What are the 2 scores reported in DXA scans?	T and Z score
What are they?	
T score	Number of standard deviations from the mean for young, normal controls
Z score	Number of standard deviations from the mean for an age- and sex-matched control group
How is osteoporosis diagnosed?	T score more than 2 standard deviations below the mean
What's the therapy?	Calcium and vitamin D supplements, bisphosphonate treatment (alendronate and risedronate), weight-bearing exercise, stop smoking, discontinue offending medications, and consider hormone replacement therapy (not first-line therapy) if fails to improve on standard therapy
What test should be ordered to gauge response to therapy?	DXA scan
When?	One year after therapy initiated

Chapter 6

Hematology and Oncology

MALIGNANT NEOPLASMS

CASE 1

A 58-year-old male with history of COPD, HTN, and lung cancer s/p resection, radiation, and chemotherapy years ago presents with profound fatigue, generalized weakness, dyspnea on exertion, fever, petechiae, and easy bruising.

What's your differential diagnosis?

Lung cancer recurrence with metastasis, anemia, acute leukemia

Which is most likely?

Acute leukemia

Why?

Because low levels of WBC, Hg, and PLT can explain all his symptoms

What symptoms may occur with the following in acute leukemia?

Leukopenia

Fever, infection, and sepsis

Anemia

Fatigue, pallor, and dyspnea

Thrombocytopenia

Purpura, bleeding, petechiae

What risk factors does the patient have for acute leukemia?

Radiation and chemotherapy exposure

What other risk factors should be remembered?

Down syndrome and benzene

If acute leukemia is diagnosed, which type does he most likely have?

Acute myelogenous leukemia (AML)

Why?	It is more common in the elderly, whereas ALL is more common in children.
What findings on physical exam would support the diagnosis of acute leukemia?	Splenomegaly, hepatomegaly, lymphadenopathy, and bone tenderness
Do all these need to be present?	No
What tests should you order?	CBC, LDH, peripheral blood smear; pan culture (blood and urine) and CXR due to fever and type and cross for possible transfusion
What results will support the diagnosis of acute leukemia in	
CBC?	Pancytopenia (low WBC, Hg, PLT) supporting bone marrow pathology
LDH?	Elevated (indicative of cell death in leukemia)
The history, physical exam, and basic lab tests suggest acute leukemia. What will clinch the diagnosis?	Blasts in the peripheral blood smear or in bone marrow aspirate (presence of greater than 30% in the bone marrow)
AML is confirmed. What caused it?	A malignant neoplasm of the blood-forming organs characterized by diffuse replacement of bone marrow with proliferating leukocyte precursors resulting in abnormal numbers and forms or immature white cells in circulation
What is the supportive therapy for	
Septic or a low neutrophil count?	Broad-spectrum antibiotics
Active bleeding or platelet count <20,000/μL?	Platelet transfusion

Severe anemia?

RBC transfusion

What is the definitive therapy?

Chemotherapy and bone marrow transplant

CASE 2

A 47-year-old male with history of BPH, HTN, and DJD presents to the office for a yearly physical, and basic lab review done prior to the visit revealed a WBC count of 105,000. The patient says he feels fine and has not noticed any limitations in his usual routine.

What are you concerned about?

Leukemia

What type?

CML

Why?

Elevated WBC of greater than 100,000 is highly suspicious for CML; roughly 40% of patients are asymptomatic on presentation and the median age at presentation is 45

What causes CML?

A malignant myeloproliferation of the hematopoietic stem cells

As CML progresses, what type of leukemias are patients at risk of developing?

AML and ALL

What finding on physical exam would support the diagnosis of CML?

Splenomegaly

Name the three phases of CML.

Chronic, accelerated, and blast

Which stage is this patient in?

Chronic

Name common symptoms that CML patients may present with.

Anemia (pallor, fatigue, and dyspnea on exertion), weight loss, low-grade fevers, night sweats, mild upper left quadrant discomfort (associated splenomegaly)

You know the WBC is elevated. What additional serologic tests should you order now to support your diagnosis?

Leukocyte alkaline phosphatase, LDH

What result do you expect for

leukocyte alkaline phosphatase?

Decreased

LDH?

Increased

What is the significance of low leukocyte alkaline phosphatase?

Distinguishes CML from other myeloproliferative disorders

What additional CBC abnormalities may be found?

Normochromic-normocytic anemia (mild) and thrombocytosis

Your labs and physical exam support the diagnosis of CML. What must be done to confirm the diagnosis?

1. Bone marrow biopsy
2. Cytologic and chromosomal analysis

What findings are required on

Bone marrow biopsy?

Hypercellular bone marrow with granulocyte hyperplasia, increased ratio of myeloid cells to erythroid cells, increased megakaryocytes with few blasts and promyelocytes

Cytologic and chromosomal analysis?

The Philadelphia chromosome (9:22 chromosomal translocation) or its products, the BCR/ABL fusion mRNA, and the Bcr/Abl protein

Chronic phase of CML is diagnosed. What's your treatment plan?

Palliative therapy with chemotherapy (hydroxyurea, decreases leukocytosis and thrombocytosis) and α -interferon (decreases number of cells carrying Philadelphia chromosome) or combination of interferon and cytosine arabinoside

What is the natural progression of CML?	Chronic phase to accelerated and blast phase
What treatment may prevent disease progression?	Bone marrow transplant
What symptoms and signs indicate they are likely progressing into the blast phase?	Increased chronic phase symptoms with lymphadenopathy, bone pain, marked anemia, thrombocytopenia (easy bruising), and predominance of blasts
What are blast phase patients at risk for?	Infection and bleeding due to bone marrow failure (most often causes death)
What treatments are available for the accelerated and blast phases?	Intensive chemotherapy, leukapheresis, and bone marrow transplant; most treatments fail

CASE 3

A 64-year-old male with history of hypertension s/p successful treatment for URTI is noted to have elevated WBC of 5500 with predominance of lymphocytes.

What differential diagnosis are you considering?	Chronic lymphocytic leukemia (CLL), hairy cell leukemia, and Waldenström macroglobulinemia
Which diagnosis do you suspect?	CLL
Why?	Median age at presentation is 65 (patient is 64) and patients often present asymptomatic with elevated lymphocytes
What causes CLL?	Monoclonal expansion of immunoincompetent B lymphocytes (rarely T lymphocytes) into the peripheral blood, bone marrow, spleen, and lymph nodes
What's your diagnostic workup for CLL?	CBC with smear and differential, cell marker studies
Describe the diagnostic findings by CBC with differential and smear	Lymphocyte count greater than 5000/ μ L

Peripheral smear	Monoclonal proliferation of lymphocytes
Cell markers	Positive B-cell antigens CD19 and CD20 along with the T-cell antigen CD5
The diagnosis of CLL is confirmed by the above studies. Will you recommend treatment now?	No
Why?	Treatment indications are not met.
What are they?	Neutropenia, recurrent infection, anemia, thrombocytopenia, constitutional symptoms, massive splenomegaly, and massive lymphadenopathy causing discomfort
Why are CLL patients prone to infections?	Decreased levels of immunoglobulins and impaired cellular immunity
What's your management plan for this patient with early-stage CLL?	Observation for signs or symptoms of disease progression with consideration for IV immunoglobins if hypogammaglobulinemia is present to decrease risk of infection
What symptoms may the patient develop as the disease progresses?	Symptoms of anemia (fatigue, pallor, dyspnea on exertion), thrombocytopenia (easy bruising and gingival bleeding), fever, night sweats, weight loss, splenomegaly, and lymphadenopathy
What therapy will you recommend once he develops signs and symptoms of advanced-stage CLL?	Chemotherapy with consideration for allogeneic stem cell transplantation
What is the median survival after diagnosis?	6 years

CASE 4

A 28-year-old previously healthy female is referred to you from a family practitioner in a rural setting for further workup of a painless lump around her bra strap above the collar bone. She denies any associated symptoms of URTI, fever, chills, or constitutional symptoms. On exam, you find 2 nontender supraclavicular nodes, a Band-Aid where the referring physician biopsied one of the superficial nodes, and mild hepatosplenomegaly.

What's your differential diagnosis?

Infected furuncle, throat infection, dental abscess, cat-scratch fever, lymphoma (Hodgkin lymphoma and non-Hodgkin lymphoma), AIDS/HIV infection

Which do you suspect?

Lymphoma

Why?

It often presents with isolated painless swelling of a lymph node in the neck, axilla, or groin, which then spreads to adjacent groups of lymph nodes; hepatosplenomegaly may be found. No evidence on physical exam of other underlying infection was found.

What basic labs should be included in your workup?

CBC, Chem 8, liver function tests, ESR, and HIV (if risk factors are present; not in this patient)

Your nurse passes you the pathology report and Figure 6–1 from the biopsy taken last week and it says Reed–Sternberg cells were found. What is this pathognomonic for?

Hodgkin disease (non-Hodgkin disease lacks Reed–Sternberg cells)

What causes Hodgkin disease?

Malignancy of the lymphatic system secondary to monoclonal proliferation of B cells

Does this patient have type A or B (A or B symptoms)?

Type A (asymptomatic) due to lack of constitutional symptoms; type B has B symptoms

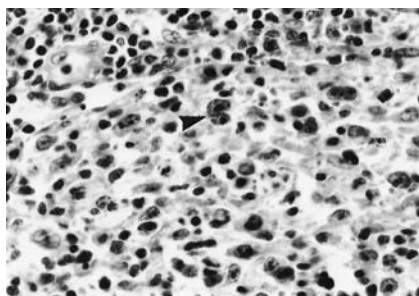


Figure 6–1. Follicle-center lymphoma with a Reed–Sternberg-like cell (*arrow*). Hematoxylin and eosin, 600 \times . (From McClatchey KD. Clinical Laboratory Medicine. 2nd Ed. Philadelphia: Lippincott Williams & Wilkins, 2002.)

Name the common B symptoms.	Fever, chills, night sweats, and weight loss
What do B symptoms suggest?	Advanced disease
Is any further testing required to make the diagnosis?	No. Lymph node biopsy (already done) is the gold standard diagnostic test.
What additional tests are required to stage her disease?	CT scan, gallium or PET scan, bilateral bone marrow biopsy, and aspiration
Imaging states a region of lymphadenopathy and is limited to one side of the diaphragm. What stage does she have?	Stage I
Define the other stages.	
Stage II	Two lymph node regions on one side of diaphragm
Stage III	Lymph node regions on both sides of diaphragm
Stage IV	Disseminated disease with bone marrow or liver involvement
What's the treatment for your patient with stage I disease?	Local radiation

What's the treatment for stage**IIA?**

Radiation

IIB?

Radiation and chemotherapy

III and IV?

Chemotherapy

CASE 5

A 65-year-old African-American male with history of BPH presents with decreased stream strength, sensation of incomplete voiding, blood in urine, unintentional weight loss, and mid-back pain.

What's the differential diagnosis?

UTI, BPH, prostatitis, PCa, bladder cancer, bladder calculi, urethral stricture disease

Which do you suspect?

PCa with bony metastasis

Why?

African-American male over age of 60 (both risk factors for PCa) presenting with bladder outlet obstruction symptoms (decreased stream strength, increased urinary frequency, sense of incomplete voiding) with or without UTI and pyuria with back pain (to rule out bone metastasis), weight loss (to rule out underlying malignancy), and hematuria is highly suspicious of metastatic PCa.

What do you expect to find on rectal exam?

Firm, nodular, or irregular prostate

How is this different from the rectal exam with BPH?

BPH typically has a smooth, symmetrically enlarged prostate with a rubbery consistency

What labs should you order and why?

Chem 8 (to rule out increased creatinine and renal insufficiency), CBC (to rule out anemia or leukocytosis), PSA (increased in most PCa), serum alkaline phosphatase (increased with bony metastasis)

Does a normal PSA value rule out prostate cancer?

No, but it makes the diagnosis less likely

What increase in PSA is strongly correlated with prostate cancer?

A PSA level 3–4 times the normal value

If the alkaline phosphatase comes back elevated, does this confirm bone disease?

No, it could have come from the liver

What lab test can differentiate bone from liver alkaline phosphatase?

Heat fractionization of alkaline phosphatase

What result is consistent with bony mets?

Decreased alkaline phosphatase with heat (bone burns liver lives)

PSA comes back $6\times$ normal (consistent with PCa). What diagnostic test should you order next?

Ultrasound with biopsy

What histologic diagnosis do you expect?

Adenocarcinoma, because it is the most common type

Prostate adenocarcinoma is diagnosed. What additional tests should be ordered because metastasis is suspected because of complaints of bone pain?

Bone scan (for bone metastasis) and CT or MRI (metastatic lymphadenopathy)

What is the treatment for Men under 70 (this patient is 64)?

Radical prostatectomy and radiation

Men over 70?

Conservative or palliative therapy

What additional therapy may be beneficial in late-stage disease?

Antiandrogen therapy (diethylstilbestrol) or castration

What tumor marker test should be ordered periodically to screen for cancer recurrence?

PSA

Does an elevated PSA indicate recurrence?

Possibly, but it also could be BPH

CASE 6

A 50-year-old male presents with painless lymphadenopathy in the neck and mild hepatosplenomegaly.

What differential diagnosis are you considering?

Throat infection, dental abscess, cat-scratch fever, lymphoma [Hodgkin lymphoma and non-Hodgkin lymphoma (NHL)], AIDS/HIV infection

What's number one on your differential?

Lymphoma

Why?

Painless lymphadenopathy with mild hepatosplenomegaly with no other infectious signs or symptoms is highly suggestive of lymphoma.

Would your level of suspicion change if HSM were absent?

No

What basic labs should be ordered?

CBC, Chem 8, LFT, coags (PT, PTT, and INR), ESR, LDH

What results may be found in NHL?

Mild anemia, elevated LDH, and ESR

What diagnostic test should you order?

Tissue biopsy

Biopsy reveals low-grade lymphoma with malignant expansion of B cells (more common than T cell) and no Reed–Sternberg cells were present. What's your diagnosis?

NHL

What additional workup is required?

CT scan, bilateral bone marrow biopsy, and aspiration to stage the disease

Do you expect advanced disease?

No, because there are no B symptoms (fever, chills, night sweats, and weight loss)

Imaging and bone marrow biopsy support localized neck disease. What's your treatment?

Chemotherapy, prednisone, and radiation (owing to localized disease)

Name the common chemotherapy regimens for Low-grade lymphoma

Chlorambucil or cyclophosphamide and prednisone

Intermediate and high-grade lymphomas

CHOP (cyclophosphamide, doxorubicin, vincristine, and prednisone)

When should stem cell or autologous bone marrow transplant be considered?

In patients who relapse following initial treatment with chemotherapy

ANEMIAS

CASE 7

A 65-year-old male with history of mild aortic stenosis calls the clinic to schedule an office visit for progressive fatigue and lethargy over the last 3 months. The appointment is scheduled, but before seeing the patient you request he go to the lab for some basic tests.

What two tests should you order?

CBC (to rule out anemia) with differential and TSH (to rule out hypothyroidism)

Hg 9, MCV 73, TSH 7; what's your diagnosis?

Microcytic anemia

What's the differential diagnosis for microcytic anemia?

Iron deficiency (GI bleed most common, menstruation, genitourinary, hookworm), anemia of chronic disease (ACD), decreased iron absorption (postgastrectomy and celiac disease), increased iron demand (pregnancy), thalassemia trait or syndrome, other hemoglobinopathies, sideroblastic anemia, chronic renal failure, lead poisoning

Which do you suspect in this patient?	GI blood loss most likely secondary to AVMs
Why?	Aortic stenosis is associated with AVMs
What signs of iron-deficient anemia may be evident on physical exam?	Glossitis, koilonychias (“spoon nails”), and angular stomatitis
What basic test can be done at the bedside to support GI blood loss?	Stool guaiac test (tests for occult blood)
Hemocult test is positive (GI blood loss is confirmed). What additional labs should be ordered to diagnose iron-deficient anemia?	Serum iron, ferritin, iron saturation, and total iron-binding capacity (TIBC)
What results do you expect in iron-deficient anemia?	
Serum iron	Low
Ferritin	Low
Percent iron saturation	Low
TIBC?	High
What test would confirm the diagnosis but is rarely done?	Bone marrow biopsy revealing decreased or absent iron stores
What diagnostic procedure should be done in this patient with GI blood loss and iron-deficient anemia?	Colonoscopy and, if negative, upper endoscopy
What is the treatment?	Correct underlying cause, and oral iron-replacement therapy with ferrous sulfate or gluconate

CASE 8

A 37-year-old male with history of alcoholism compliant with Alcoholics Anonymous and Crohn disease s/p ileal resection 3 years ago for SBO presents to your office complaining of getting tired at half his usual running distance. He is concerned that he may have steroid myopathy, which was suggested by an internet health website.

What are you more concerned about?

B₁₂ or folate deficiency

Why?

Fatigue with exercise intolerance is a symptom of anemia, possibly from ileal resection causing B₁₂ deficiency or alcoholism (decreased intake) causing folate deficiency

What other risk factors exist for

Folate deficiency?

Increased demand (pregnancy, hemolytic anemia), malabsorption, and drugs (e.g., ethanol, methotrexate, azathioprim, trimethoprim, phenytoin, and sulfasalazine)

B₁₂ deficiency?

Pernicious anemia, gastrectomy, pancreatic insufficiency, ileal disease or resection, intestinal bacterial overgrowth, and parasites

Which deficiency are patients at greater risk of developing owing to lower body reserves?

Folate deficiency

How long would it take to develop a B₁₂ deficiency?

Years

Which deficiency is most likely in this patient?

B₁₂ due to ileal resection

Labs from 6 months ago reveal mild anemia and macrocytosis. What's the differential diagnosis for macrocytosis?

Alcohol abuse, reticulocytosis, vitamin B₁₂ deficiency, folic acid deficiency, liver disease, hypothyroidism, marrow aplasia, myelofibrosis

What's the basic workup for macrocytosis in a patient with unclear risk factors?

CBC with differential and smear, B₁₂, folate, reticulocyte count, thyroid and liver function studies

What tests should be done in this patient?

CBC with differential and smear, B₁₂, folate

What finding on peripheral smear supports the diagnosis of B₁₂ or folate deficiency?

Presence of hypersegmented neutrophils

How is the diagnosis made?

Increased MCV with a low folate or vitamin B₁₂ level

Lab workup confirms macrocytic anemia with low B₁₂ and hypersegmented neutrophils on smear diagnostic of B₁₂ deficiency. What additional test could determine the cause of the B₁₂ deficiency?

Schilling test

Should this patient be treated?

Yes

Why?

To minimize risk of developing signs or symptoms of vitamin B₁₂ deficiency

What are they?

Neurologic manifestations of decreased vibratory and positional sense, ataxia, paresthesias, confusion, and dementia

What is the therapy for his vitamin B₁₂ deficiency?

Intramuscular vitamin B₁₂

If he resumes drinking and develops folate deficiency, what would be the therapy?

Oral or IV folic acid and alcohol abstinence

CASE 9

A 54-year-old male with history of DJD, BPH s/p treatment of UTI with Bactrim 3 months ago presents complaining of fatigue, dyspnea on exertion, easy bruising, and epistaxis. He denies any chest pain, fever, chills, abdominal pain, or signs of GI blood loss. On physical exam, skin pallor appreciated as well as dry blood in both nares and multiple ecchymosis on the arms. The heart is regular with no murmur rubs or gallops, and the chest is clear to auscultation bilaterally.

What is the single most important lab test to order?

CBC

Why?

Because low platelets and hemoglobin could explain his symptoms on presentation

CBC reveals pancytopenia. What's the next simple lab test?

Peripheral blood smear

Smear reveals a paucity of platelets, red blood cells, granulocytes, monocytes, and reticulocytes. What's the next best test?

Bone marrow aspiration

Marrow is hypocellular. What's your differential diagnosis?

Acquired aplastic anemia, inherited aplastic anemia (Fanconi's anemia), myelodysplastic syndromes, AML

Which is most likely in this patient, given the history, presentation, and diagnostic tests?

Acquired aplastic anemia

What are the most common causes of aplastic anemia?

Idiopathic about 50%; drugs are the second leading cause

What risk factor was present in this patient?

Bactrim (contains sulfa, which has been associated with aplastic anemia)

What are some other risk factors associated with conditions for acquired aplastic anemia?

Viral illness [hepatitis, Epstein-Barr virus, cytomegalovirus (CMV)], drugs (e.g., acetazolamide, chloramphenicol, penicillamine), or radiation

How is aplastic anemia diagnosed?	Pancytopenia with a normal MCV and peripheral blood smear with hypocellular bone marrow biopsy
Why does it occur?	Failure of the bone marrow stem cells
What replaces the normal hemopoietic cells?	Fat
What is the treatment?	Discontinue offending drugs, RBC and platelet transfusions as needed, and bone marrow transplant
What is the therapy for patients unable to receive a Bone Marrow Transplant (BMT)?	Immunosuppressive therapy with cyclosporine, glucocorticoids, and antithymocyte globulin
What are the indications for empiric broad-spectrum antibiotics?	Fever and neutropenia

CASE 10

A 45-year-old male presents with fatigue, dyspnea on exertion, and microcytic anemia.

What is your differential diagnosis for microcytic anemia?	Iron deficiency, ACD, sideroblastic anemia, thalassemia
What labs tests should you order to narrow the differential diagnosis?	Ferritin, serum iron, TIBC, and red cell distribution width (RDW)

Using the table, quiz yourself on the expected values for each disease state listed.

Disease	Ferritin	Iron	TIBC	RDW
Iron deficiency	↓	↓	↑	↑
Chronic disease	N/↑	↓	↓	N
Sideroblastic anemia	N/↑	↑ [—]	Nl	Nl
Thalassemia	Nl/↑	Nl/↑	Nl/↓	Nl/↑

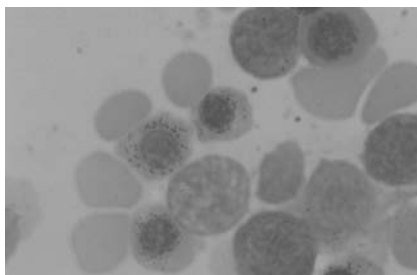


Figure 6–2. Ringed sideroblasts (Prussian blue stain). Numerous erythroblasts demonstrate deposition of granular iron nearly encircling the nucleus. (From McClatchey KD. *Clinical Laboratory Medicine*. 2nd Ed. Philadelphia: Lippincott Williams & Wilkins, 2002.)

The labs come back with normal ferritin, TIBC, and RDW with low serum iron. What's the most likely diagnosis?

Sideroblastic anemia

What risk factors for sideroblastic anemia should you ask about?

Drugs (e.g., isoniazid, chloramphenicol), chronic alcoholism, lead poisoning, malignancy, and chronic inflammation, infection, or myelodysplastic syndrome

How will you confirm the diagnosis?

Bone marrow aspirate

What diagnostic feature is present in Figure 6–2?

Ringed sideroblasts (numerous iron-stained granules surrounding the nucleus)

What causes sideroblastic anemia?

Failure of the RBC to incorporate iron into the heme molecule, resulting in deposition of a “ring” of granules around the RBC nucleus (called ringed sideroblast in the bone marrow) and hypochromic anemia

What is the treatment?

Supportive, with transfusions as necessary, and treat any underlying causes

What are patients at risk of developing despite therapy?

Acute leukemia or complete bone marrow failure, if it is caused by myelodysplastic syndrome

CASE 11

A 22-year-old healthy woman of Mediterranean descent arrives for her first prenatal visit and is found to have a hemoglobin of 9, MCV of 60, RDW 28, retic 8%. She is diagnosed with microcytic anemia. She denied excess menstrual bleeding, weight loss, or change in stool color, character, or frequency. On physical exam, mild splenomegaly is appreciated and guaiac test is negative for occult blood. The remainder of the physical exam is normal.

What diagnoses are you considering?

Iron deficiency, thalassemia, or sideroblastic anemia

What additional labs should be ordered?

Iron panel, which includes serum iron, transferrin, and ferritin

The iron workup is normal. What's the next step?

Peripheral smear

Smear shown in Figure 6–3 reveals basophilic stippling, target cells. What diagnosis does this suggest?

β -Thalassemia

What risk factor did she have for β -thalassemia?

Mediterranean descent

What other risk factors are there for β -thalassemia?

African, Middle Eastern, Indian, or Asian descent

Name the most common adult thalassemia.

β -Thalassemia minor (β -chain mutation)

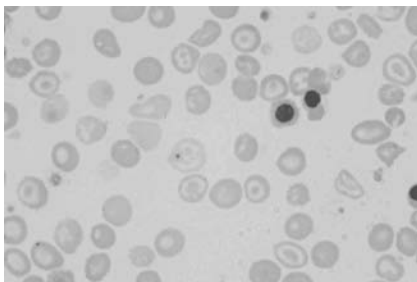


Figure 6–3. β -Thalassemia. (From Anderson SC. Anderson's Atlas of Hematology. Philadelphia: Lippincott Williams & Wilkins, 2003.)

What other disease is β -thalassemia minor most often confused with?

Iron-deficient anemia as a result of the microcytosis

You suspect β -thalassemia minor. What test and results will confirm your diagnosis?

Hemoglobin electrophoresis showing increased levels of fetal hemoglobin and hemoglobin A2

What is the treatment for β -thalassemia minor?

Supportive, no specific treatment required

What causes β -thalassemia?

A genetic mutation in one of the globin genes resulting in failure to produce one of the globin chains

Why do the defective adult hemoglobin molecules hemolyze?

Failure to produce adequate quantities of one of the globin chains creates a surplus of the other. These additional globin chains then precipitate, forming Heinz bodies in the RBC, and destabilize the membrane, causing hemolysis.

What disease is β -thalassemia partially protective for?

Malaria

CASE 12

A 17-year-old male with history of sickle cell disease presents to the ED with acute onset of fever, malaise, chest pain, and shortness of breath after hiking at low altitudes.

What's your diagnosis?

Sickle cell disease crisis with probable acute chest syndrome

How does sickle cell crisis often present?

Fever, malaise, and a painful vaso-occlusive crisis in the back, ribs, and extremities lasting for several days

When should you consider acute chest syndrome?

Any sickle cell disease patient complaining of shortness of breath or chest pain

What causes sickle cell disease?

A single amino acid substitution on the β -chain of globin in the hemoglobin molecule

How does this affect the RBC?	It polymerizes (“sickles”) in the deoxygenated state.
Who is at risk?	Homozygous S patients
What most likely triggered this patient’s attack?	Dehydration secondary to hiking long distances
What else can precipitate it?	Fever, infection, and pregnancy
What labs should you order to support the diagnosis of sickle cell crisis?	CBC, reticulocyte count, MCV, unconjugated bilirubin, LDH, haptoglobin
What lab values do you suspect In general?	Low hemoglobin (5–10 g/dL) with an increased reticulocyte count; MCV may be slightly increased
With hemolysis?	Increased unconjugated bilirubin and LDH, low serum haptoglobin
Describe characteristic findings that support the diagnosis on the peripheral smear in Figure 6–4?	Sickle-shaped RBCs with Howell–Jolly bodies (indicates functional asplenia, may not be present in all)
What depicts the Howell–Jolly bodies in Figure 6–4?	Round, dense red cell inclusions of variable size that stain like the nucleus

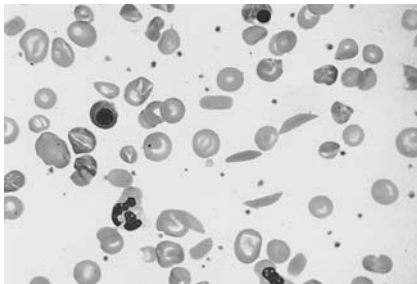


Figure 6–4.

(From Rubin E, Farber JL. Pathology. 3rd Ed. Philadelphia: Lippincott Williams & Wilkins, 1999.)

What additional radiographic study and lab test should be ordered on this patient as a result of his pulmonary symptoms?

CXR and ABG to support the diagnosis of acute chest syndrome

What are you looking for in the CXR and ABG?

Pulmonary infiltrates and hypoxia

The above labs and studies support sickle cell crisis with acute chest syndrome. Do you need to confirm the diagnosis before treating?

No, the patient came in with the diagnosis and has a laboratory profile consistent with the disease; waiting for the definitive test would only delay treatment.

What test would confirm the diagnosis made in the past?

Hemoglobin electrophoresis depicting large numbers of hemoglobin S molecules (heterozygotes have both Hg A and S)

What's your treatment for Sickle cell crisis?

IV hydration, analgesics (narcotics), folate supplements, red blood cell transfusions as needed, and antibiotics if infection suspected

Acute chest syndrome?

Oxygen and empiric antibiotics

What is the preventative treatment?

Oral fluids to prevent dehydration and hypoxia, folic acid supplements, vaccinations (pneumococcal, hepatitis B, and influenzae), and yearly ophthalmologic exams

What is a common complication of chronic sickling?

Functional asplenia from repeated splenic infarctions

What infectious organisms are patients with functional asplenia at risk for?

Encapsulated organisms (e.g., pneumococcus and haemophilus influenzae) and *Salmonella*

CASE 13

A 52-year-old woman with history of HTN, rheumatoid arthritis, DJD, and congestive heart failure (CHF) presents to the clinic after being discharged from the ER for fatigue and mild dyspnea on exertion. The discharge diagnosis reads normocytic anemia with no evidence of acute GI blood loss. Follow-up was recommended with you as her primary care physician. You review the chart and note that she had a screening colonoscopy 2 years ago, which was negative and has had negative occult blood tests and mild anemia in the past with an Hg of 10. Her Hg now per ER records was 9.2.

What defines normocytic anemia?	MCV between 80 and 100
What's the differential diagnosis for normocytic anemia?	Hemolysis, aplastic anemia, acute hemorrhage, renal failure, myelophthisis, combined microcytic and macrocytic anemia (e.g., iron and folate deficiency), endocrine disorders (hypothyroidism, gonadal dysfunction, adrenal insufficiency), ACD (secondary to connective tissue disorders, infection, cancer), bone marrow failure, and lead poisoning
Which is most likely in this patient?	ACD
Which risk factors does she have for it?	Long-standing inflammatory diseases (rheumatoid arthritis), autoimmune disorders (rheumatoid arthritis)
Name 2 other risk factors that should be considered.	Malignancy and chronic infection
What labs should you order to support your diagnosis of ACD?	CBC, serum iron, TIBC, ferritin
What lab values are consistent with ACD?	
CBC	Normochromic normocytic anemia
Serum iron	Low

TIBC	Low
Ferritin	Normal or increased (because it is an acute-phase reactant)
How is ACD diagnosed?	Underlying chronic disease with the above associated lab values
What causes ACD?	Decreased delivery of iron to developing erythroblasts, decreased erythropoietin with respect to degree of anemia, and impaired bone marrow response to erythropoietin
What is the treatment?	Correct underlying disease if possible (are her DM, DJD, and RA optimally managed?) and consider erythropoietin therapy
Which four disease states may benefit from erythropoietin therapy?	Chronic renal insufficiency, chronic infection, chronic inflammatory diseases, and anemia after chemotherapy treatment

CASE 14

A 23-year-old male football player with personal and family history of bleeding problems presents to the ER with pain and loss of function in his right knee after a game with marked edema and effusion of the knee with decreased range of motion. No bony tenderness is found; ligament stress tests are negative.

What's your differential diagnosis?	Fracture, severe strain or sprain, hemarthrosis secondary to hemophilia
Which is most likely?	Hemophilia
Why?	Patient and family have history of bleeding disorder, and hemarthrosis can occur in these patients, especially if playing contact sports.
How does hemophilia often present?	With painful spontaneous bleeding into the joints (hemarthrosis) or with prolonged posttraumatic or postoperative bleeding

Name the 2 most common hemophilias and their respective deficiency.	Hemophilia A (factor VIII deficiency) and hemophilia B (factor IX deficiency)
What causes hemophilia?	A hereditary bleeding defect characterized by a deficiency of specific plasma clotting proteins required for blood coagulation
What is the hereditary pattern?	X-linked (male offspring are often affected while female offspring are carriers)
What imaging test should be done in this patient?	X-ray of the left knee to rule out fracture
X-ray shows a joint effusion but no fracture. What lab tests should you order?	CBC, PTT, PT, fibrinogen, and bleeding time
What associated lab values do you expect to find?	Most often, patients have a prolonged PTT with normal PT, fibrinogen level, and bleeding time.
Labs and presentation are consistent with hemophilia. What diagnostic test should you order next?	Factor-specific assay
What is diagnostic of Hemophilia A?	Factor VIII (decreased)
Hemophilia B?	Factor IX (decreased)
What is your treatment?	Replace deficient factor, avoid platelet-inhibiting drugs (e.g., NSAIDS), and recommend patient play noncontact sports

CASE 15

A 21-year-old college student presents with complaints of heavy menstrual bleeding throughout her life, frequent epistaxis, and an odd rash on her lower extremities after taking aspirin. Upon chart review, you note in the family history that the patient's mother required blood transfusions with her pregnancy.

What's your differential diagnosis?	Thrombocytopenia and von Willebrand disease (vWD)
Which do you suspect?	vWD
How can vWD disease present?	Mucocutaneous bleeding (e.g., menorrhagia, GI bleeding, gingival bleeding, epistaxis, and easy bruising) and soft-tissue bleeding with hemarthrosis
What labs should you order?	CBC, PT, PTT, bleeding time (assesses platelet function)
What do you expect to find with the CBC?	Microcytic anemia due to chronic blood loss
PT?	Normal
PTT?	Prolonged
Bleeding time?	Prolonged
Labs are consistent with vWD. What test will confirm the diagnosis?	Low vWF antigen, abnormal ristocetin cofactor activity, and abnormal ristocetin-induced platelet aggregation
vWD is diagnosed. What causes it?	An autosomal-dominant coagulation disorder characterized by decreased levels of vWF, leading to decreased adherence of platelets to injured vessel walls and decreased stability of factor VIII in the plasma
What is your therapy?	Factor VIII or cryoprecipitates that contain vWF concentrates
What may be useful in the future if she needs surgery?	Desmopressin (DDAVP)
What does DDAVP do?	Increases secretion of vWF from Weibel-Palade bodies in the endothelium

Chapter 7

Neurology

INFECTIOUS DISEASES OF THE CENTRAL NERVOUS SYSTEM

CASE 1

A 32-year-old female with asthma, recurrent paranasal sinus infections, and congenital heart defect visits her ENT doctor complaining of headache, stiff neck, and right arm weakness.

What's your differential diagnosis?

Brain abscess, rapidly growing brain tumors, meningitis, encephalitis, and sub-arachnoid hemorrhage (SAH)

Which do you suspect?

Brain abscess

Why?

Paranasal sinus infections and congenital heart defects are both risk factors for brain abscess.

Name a few other risk factors for brain abscess

Dental procedures, artificial heart valves, recent infection, paranasal sinus infections, and pneumonia

What tests should be included in the workup?

Lumbar puncture, blood and throat cultures, CXR, CT of head, cardiac ECHO in addition to routine chemistry, CBC, and coagulation time (coags)

What are you looking for by ordering the following?

LP

Meningitis (CSF shows pleocytosis, low glucose, elevated protein)

Blood and throat cultures

Causative organisms

CXR

Pneumonia

CTH

Focal brain masses, abscess, evidence of meningeal swelling

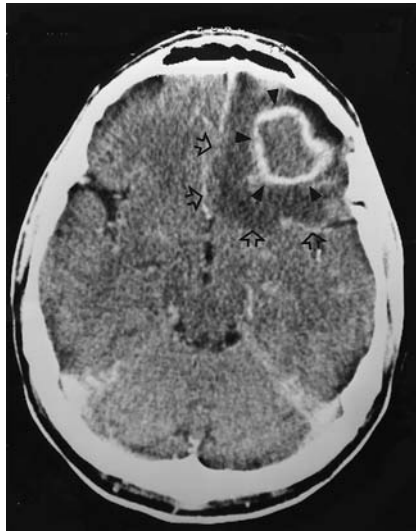


Figure 7–1. Brain abscess. Left frontal brain abscess. CT image after intravenous contrast enhancement shows the rim of the abscess to enhance (arrowheads). Notice the surrounding edema (open arrows). (From Daffner RH. *Clinical Radiology: The Essentials*. 3rd Ed. Philadelphia: Lippincott Williams & Wilkins, 2007.)

Cardiac ECHO

Valve vegetations and congenital heart defects

CBC

Leukocytosis

Chem 8

Check creatine to rule out renal insufficiency, assess electrolytes

Coags

Rule out coagulopathy due to likelihood of diagnostic invasive procedures

What are the radiographic findings with a brain abscess shown in Figure 7–1?

Ring-enhancing lesion

What is the treatment?

Medical

IV antibiotics and sometimes intraventricular antibiotics, steroids to reduce mass effect and edema

Surgical

Ventricular drain to reduce acute intracranial pressure with surgical excision of abscess if antibiotics and drain fail

What additional therapy is required?

Treat source of infection if identified

CASE 2

A 22-year-old previously healthy male is brought to the ED by his mother after displaying bizarre behavior. About 1 week ago, this reserved young man was excessively happy, slept little, and was calling all his friends to go out and meet women. A few days later he complained of a fever and headache with nausea and vomiting. Now he is lethargic and has difficulty speaking.

What's your differential diagnosis?

Viral or bacterial encephalitis, brain abscess, subdural empyema, brain tumors, subdural hematoma

Which is most likely?

Viral encephalitis

Which virus?

Herpes simplex virus

What are the clues?

Bizarre behavior followed by headache, fever, nausea, and vomiting with progressive lethargy, confusion, focal neurologic findings

What are the risk factors?

Usually spontaneous, neonates may be exposed in birth canal of infected mothers

What's in your diagnostic workup?

Chem 8, CBC, PT, INR (international normalized ratio), CT head (or MRI), lumbar puncture for CSF analysis

What do you expect to find in HSV encephalitis?**CBC**

Leukocytosis

Coags

Normal

CT head

Low-density, nonenhancing lesions in the temporal lobe

CSF	Excess WBCs (lymphocytes, monocytes), RBCs (because of hemorrhagic component), and increased protein with decreased or normal glucose
What additional test is ordered to make the diagnosis?	PCR for HSV DNA in the CSF
How was it diagnosed before PCR?	Brain biopsy
What is the treatment?	Acyclovir and anticonvulsants for seizures

CASE 3

A 19-year-old college male with history of asthma, appendectomy, migraines, and splenectomy 3 years ago after a motor vehicle accident calls your office complaining of progressive headache, neck stiffness, and confusion.

What should you tell him?	Go to the ER.
What's your differential diagnosis?	Meningitis (bacterial and viral), encephalitis, brain abscess, SAH, and cerebral vasculitis
What do you suspect?	Bacterial meningitis
How does it commonly present?	Headache, neck stiffness, photophobia, and change in mental status
What causes the symptoms?	Inflammation of the meninges
What risk factor for bacterial meningitis does he have?	Splenectomy (defect in humoral immunity)
What type of bacteria?	Encapsulated bacteria (<i>Streptococcus pneumoniae</i> , <i>Neisseria meningitidis</i> , <i>Haemophilus influenzae</i>)
What physical findings are suggestive of the meningitis (viral and bacterial)?	Fever, nuchal rigidity, mental status abnormalities, focal neurologic findings (e.g., seizures)

What are signs of meningeal irritation on physical exam?

Brudzinski and Kernig signs

Describe them.

Brudzinski sign

Neck flexion while supine leads to involuntary hip and knee flexion

Kernig sign

Knee extension with a flexed hip produces pain

What type of meningitis is suggested by a petechial rash on physical exam?

N. meningitidis

How is bacterial meningitis diagnosed?

Lumbar puncture with CSF analysis

What results do you expect with

Bacterial meningitis?

Increased WBC with high polymorphonuclear cells, high protein, low glucose

Aseptic meningitis (non-bacterial, viral)?

High lymphocytes, normal or slightly elevated protein, normal glucose

What additional CSF test should be done before treatment?

Gram stain and bacterial cultures

What is the empiric treatment for bacterial meningitis in

Adults and children over 3 months?

Third-generation cephalosporin

Infants and neonates?

Ampicillin and cefotaxime

When are antibiotics adjusted?

After results of Gram stain, culture, and drug sensitivity are reported

What is the treatment in aseptic meningitis?

Supportive therapy

CASE 4

An 8-year-old illegal immigrant boy from a third-world country presents to the ER with his mother complaining of severe headache, stiff neck, and inability to move his right arm. The mother informs you that he did not receive all his vaccinations prior to entering the United States.

What's your differential diagnosis?	Meningitis, brain neoplasm, brain abscess, poliomyelitis
Which is most likely considering lack of complete immunizations?	Poliomyelitis
How does it usually present?	Fever, headache, stiff neck, muscle pain followed by asymmetric paralysis
What is poliomyelitis?	A viral infection of the spinal cord caused by poliovirus in the anterior horn and brain stem that causes cell destruction and produces the paralytic manifestations of poliomyelitis
How does the virus enter the body?	Fecal–oral contact
What diagnostic tests should you order?	Throat, stool, or CSF culture for poliovirus and/or polio-specific antibody test
How do you differentiate poliomyelitis from Guillain-Barré syndrome (GBS) or acute inflammatory demyelinating polyneuropathy?	Sensory symptoms are present in GBS but not in polio.
How is poliomyelitis treated?	Supportive, including respiratory support if respiratory failure ensues
How could this have been prevented?	Oral polio vaccination (OPV)

DEGENERATIVE AND HEREDITARY DISEASES OF THE CENTRAL NERVOUS SYSTEM

CASE 5

A 45-year-old male presents to your clinic with a progressive illness over the last few months. First he noticed hand and feet weakness, which is still present. Now he has muscle spasms and difficulty speaking which you appreciate. Physical exam reveals hand and foot weakness, atrophy. It is also positive for hyperreflexia and spasticity of both upper and lower extremities.

What diagnosis is most likely?	ALS
What other name for ALS is there?	Lou Gehrig disease
How does it typically present?	Combination of lower motor dysfunction (hand, foot weakness, atrophy, and muscle twitches) and upper motor neuron dysfunction (hyperreflexia) with or without brainstem involvement (dysarthria and dysphagia)
What test is helpful in supporting the diagnosis?	Electromyography (EMG) and nerve-conduction studies
What imaging should be ordered to rule out spinal cord lesions?	MRI of the cervical and thoracic spine
How is the diagnosis made?	Clinical pattern of both upper and lower motor neuron
How is ALS treated?	The antiglutamatergic drug riluzole increases life expectancy of ALS patients by 4–6 months.
What is the overall prognosis?	Without tracheostomy and ventilatory support, the life expectancy is less than 2 years after bulbar involvement. If there is predominantly spinal involvement, 5-year survival is approximately 20%.

CASE 6

A lady comes to the office with her 81-year-old husband. She apologizes for being late and says that her husband needs frequent direction when driving to familiar places. She adds that he also repeats the same questions frequently and often does not remember what was said 5 minutes ago. But, if she talks about the old days, he can remember it in detail.

What diagnosis do you suspect?	Alzheimer disease
What's in the differential diagnosis for Alzheimer disease?	Pick disease (frontotemporal dementia), vascular dementia, Lewy body dementia and Creutzfeldt–Jakob disease
What test is helpful in ruling out Pick disease and vascular dementia?	CT or MRI of head
What findings on CT suggest diagnosis of Alzheimer disease?	Cortical atrophy
What clinical features if present would suggest Lewy body dementia?	Gait/balance disorder, prominent hallucinations and delusions
What test is helpful to rule out Creutzfeldt–Jakob disease?	EEG
Why suspect Alzheimer disease in this patient?	Most common cause of dementia over age of 80
What symptoms may appear after short-term memory loss?	Disorientation, depression, and agitation
What lab tests should be performed?	Complete blood cell count, serum electrolytes, glucose and BUN/creatinine, serum B12 levels, liver function tests, and thyroid function tests

What are the clinical criteria used to diagnose Alzheimer disease?

Dementia by clinical examination and documented by neuropsychological screens or tests, deficits in two or more areas of cognition, progressive worsening of memory and other cognitive functions, no disturbance of consciousness, onset between the ages of 40 and 90 years, and absence of systemic or CNS disorders, which could account for the progressive deficits of memory and cognition

How is a definitive diagnosis made?

Neuropathologic examination at autopsy

What is the treatment strategy?

Cholinesterase inhibitors (donepezil, rivastigmine, or galantamine)

CASE 7

A 62-year-old male with history of DJD, gout, BPH, and hyperlipidemia presents to the clinic with his wife after noting a tremor in his hand while resting. It goes away with intentional movement. As he walks toward you to the examining room, he appears to shuffle down the hallway and is slightly bent forward.

What disease do you suspect he has?

Parkinson disease

What are the cardinal signs of Parkinson disease?

Resting tremor, cogwheel rigidity, bradykinesia/akinesia, and postural reflex impairment

How do you differentiate parkinsonian tremor from essential tremor?

Parkinsonian tremor occurs at rest, while an essential tremor is a postural tremor seen when maintaining a posture or during an action

What causes Parkinson disease?

A neurodegenerative disease of unknown cause that results in loss of dopaminergic neurons in the substantia nigra pars compacta and the loss of their inputs to the striatum (globus pallidus and caudate nuclei)

Which diagnostic tests are helpful?	An MRI of the brain is usually done to rule out structural causes of parkinsonism.
What are the pathologic findings in Parkinson disease?	Loss of pigmented neurons in the substantia nigra pars compacta and appearance of Lewy bodies
How is the diagnosis made?	Clinically, and is considered definite if any three of the cardinal signs are present
What is the treatment?	Levodopa combined with a peripheral DOPA-decarboxylase inhibitor (carbidopa in Sinemet, benserazide in Madopar) remains the single most effective medication.

NEOPLASMS

CASE 8

A 55-year-old male with history of COPD from 60 pack-years of smoking comes to the ER after falling off his bike. He gradually became weaker on his right side, was not able to maintain his balance, and fell. Since arriving by ambulance, his right-sided facial, arm, and leg weakness has not improved.

What's your differential diagnosis?	Brain tumors, stroke, resolving intracranial hemorrhage, brain abscess
Which is most likely?	Metastatic brain cancer from a primary lung cancer due to excessive smoking history
How does a brain tumor typically present?	Gradual decline in cognitive and intellectual ability, focal neurological signs, or seizures
What is the most common primary brain neoplasm in Adults?	Glioblastoma multiforme (malignant) and meningioma (benign)
Children?	Cerebellar astrocytoma and medulloblastoma

What is the most common source of metastatic brain tumors?

Lung cancer (most likely in this patient)

What are the associated CT or MRI findings?

Irregular lesions with surrounding edema or ring-enhancing lesions with or without edema or solid lesions with or without edema. Ventricles displace to opposite side. Hydrocephalus may be present.

What CT finding should raise suspicion of metastasis?

Multiple brain lesions

What is the treatment?

Steroids to reduce edema, surgical excision or debulking followed by radiation and chemotherapy, anticonvulsants for seizure control

DEMYELINATING DISEASE

CASE 9

A 17-year-old previously healthy female presents to your office complaining of numbness in her right hand for the last 24 hours. She denies any trauma or headache preceding its onset. She does add that over the last month at various times her right field of vision was obscured for less than a day, and one morning she was unsteady on her feet. Because these symptoms went away over time, she did not feel it was necessary to see a doctor. But now she wants an answer to explain the bizarre symptoms.

What do you think she has?

Multiple sclerosis (MS)

Why?

Young female presenting with neurologic signs and symptoms separated by space and time

What is MS?

An acquired disease thought to be an autoimmune disease or viral in etiology that causes plaques of demyelination in the central nervous system

Who gets MS?

Women twice as often as men, with an age of onset from 15 to 50 years, which peaks in the 20s

How does MS commonly present?

Optic neuritis with visual loss, limb weakness, sensory symptoms (such as numbness, paresthesia, and hypesthesia), cerebellar ataxia, nystagmus, and diplopia (due to cranial nerve VI palsy or internuclear ophthalmoplegia)

What findings on the following tests support the diagnosis of MS?

CSF

Mild pleocytosis (5–50 lymphocytes) during acute attacks and increased protein with high IgG and oligoclonal bands, which are persistent between attacks

Electrophysiologic tests

Evoked potential studies (visual-evoked potentials, brainstem auditory-evoked response, somatosensory-evoked potentials) can be used to demonstrate subclinical lesions in CNS pathways.

MRI

Demyelinating plaques can usually be seen as areas of increased signal on T2 MRI, and active plaques may enhance.

How is the diagnosis of MS made?

Documenting multiple CNS lesions in time and space. This is often done by the clinical history and examination, and imaging.

What is the typical course of MS?

Acute onset of symptoms followed by a relapsing/remitting course with episodic exacerbation of new or recurrent symptoms and eventual burn out of active disease

What is the therapy for MS exacerbation?

High-dose IV methylprednisolone may shorten acute exacerbation of MS symptoms, but has no long-term effect on the course of the disease.

What other medications are there for MS?

Two forms of β -interferon (β -interferon 1a or Avonex and β -interferon 1b or Betaseron) and glatiramer (Copaxone) are known as the ABC drugs and are effective in reducing the severity and frequency of exacerbation.

CASE 10

A 55-year-old previously healthy male presents to the clinic with complaints of progressive bilateral weakness of the legs and arms 2 weeks after recovering from an upper respiratory tract infection. The symptoms began with fine paresthesias in the toes and fingertips, followed by lower extremity weakness that slowly progressed over days to involve the arms.

What diagnosis are you considering?	GBS
What is the differential diagnosis of GBS?	Chronic inflammatory demyelinating polyneuropathy, acute intermittent porphyria, central pontine myelinolysis, carcinomatous meningitis, and poliomyelitis
How does GBS present?	Weakness and sensory loss predominate, but ataxia, autonomic dysfunction (postural hypotension and arrhythmias), and back pain may also occur.
What is the pathophysiology of GBS?	An inflammatory demyelination of peripheral nerves, involving both sensory and motor nerves. Spinal roots are often involved early in the disease.
What are the associated triggers of GBS?	Roughly two-thirds of patients have upper respiratory infections or diarrheal illness 2 to 4 weeks prior to onset of weakness.
What is the most commonly identified precipitant of GBS?	<i>Campylobacter</i> infection
What finding on the following support the diagnosis of GBS?	
Physical examination	Weakness and sensory loss with early loss of deep tendon reflexes
Nerve conduction studies	Slowed conduction consistent with demyelination
Cerebrospinal fluid	Elevated protein

How is it diagnosed?	Clinical presentations, physical examination, and nerve conduction studies
What is the treatment strategy?	Plasmapheresis or IVIg can shorten and reduce the severity of the acute phase.
What are the possible complications of GBS?	Respiratory compromise and arrhythmia
What is the overall prognosis?	Recovery begins within 4 weeks after progression ceases. Eighty-five percent are ambulatory within 6 months, but >50% have some residual deficits, 5% remain severely disabled, and 16% are handicapped.

DISEASES OF NEUROMUSCULAR JUNCTION AND MUSCLE

CASE 11

A 32-year-old female presents to your office complaining of double vision, slurring her words, and difficulty swallowing food. These symptoms only appear after a long day or when very busy. For instance, after chewing a lot, she may have difficulty swallowing. And, last weekend while watching a tennis match her vision was blurred by the third set. But, if she rests the symptoms disappear until she resumes similar activity.

What disease do you suspect?	Myasthenia gravis
What is myasthenia gravis?	An autoimmune disease with antibodies against nicotinic receptors at the neuromuscular junction; impairs normal transmission resulting in increased weakness and fatigue
What risk factors does she have?	Age and sex (most are young women in third decade of life)
What are other known risk factors?	Thymoma (15–40%), other autoimmune diseases (15%), and drugs such as penicillamine

What are the common signs of myasthenia gravis?

Fluctuating diplopia, dysarthria, dysphagia, extremity weakness, and respiratory difficulty. Symptoms are often diurnal, with rapid fatiguing and improvement after rest. Sensation and reflexes are preserved.

What is the differential diagnosis for myasthenia gravis?

Lambert–Eaton syndrome, botulism, and drug-induced myasthenia

How is myasthenia gravis differentiated from Lambert–Eaton syndrome?

Rapid repetitive stimulation or sustained muscle activity results in improved strength, not weakness as in MG.

What tests should you order?

Acetylcholine receptor antibodies, EMG, CT chest, and edrophonium test (Tensilon test)

What results support the diagnosis?

Acetylcholine receptor antibodies

Positive

EMG

Decrementing responses to repetitive stimulation on EMG

What test confirms the diagnosis?

Administration of exogenous anticholinesterase such as edrophonium or neostigmine (Tensilon test) provides temporary relief of symptoms.

Why did you order a CT of the chest?

Thymoma is associated with MG and must be excluded by chest CT

What is the treatment strategy for

Moderate symptoms?

Pyridostigmine, an acetylcholinesterase inhibitor that enhances transmission at the neuromuscular junction

Severe symptoms?

Immunosuppression with prednisolone, often with azathioprine

When is surgery indicated?

Thymectomy should be performed if there is thymoma and in patients with more than minimal symptoms under the age of 45 years. Thymectomy is also used if there is residual thymus gland in older patients.

CASE 12

A 3-year-old girl is brought to the clinic by her mother after the child woke up complaining of blurred vision, light sensitivity, and difficulty keeping his eyes open. The mother said she was fine yesterday when they were at the family farm eating some of grandma's home-canned jams and picking apples from the trees.

What should you immediately suspect?

Botulism

What is the differential diagnosis for botulism?

GBS, brainstem infarction, myasthenia gravis, tic paralysis, diphtheria, familial periodic paralysis, poliomyelitis

How does botulism present?

First symptoms (12 hours to 10 days after ingestion) diplopia, ptosis, blurred vision, photophobia

What classical early physical exam finding of botulism should you look for?

Fixed dilated pupils

What was a major clue to the diagnosis?

Recently ingested home-canned foods

What is the pathophysiology of botulism?

Botulinum neurotoxin blocks the release of acetylcholine from presynaptic terminals resulting in paralysis.

How does the toxin enter the body?

Botulinum toxin is released on death and autolysis of *Clostridium botulinum* in contaminated food. The toxin is absorbed from the GI tract into general circulation.

What are the laboratory findings?

Normal cerebrospinal fluid and abnormal EMG

How is the diagnosis confirmed?	By detection of the toxin in suspected food, feces, gastric contents, or by anaerobic culture for presence of <i>C. botulinum</i>
What is the treatment?	Cathartics (removes toxin from the GI tract) and botulism antitoxin
What is the main complication of botulism?	Respiratory failure requiring intubation and ventilator support in 40% of cases

CASE 13

A 4-year-old boy is brought to the clinic with insidious onset of toe-walking, a waddling gait, and difficulty standing and walking. On physical exam you appreciate lumbar lordosis and large calves.

What diagnosis should you suspect?	Muscular dystrophy
Which one is most common in children?	Duchenne muscular dystrophy
What's the other type?	Becker muscular dystrophy
What is the cause of Duchenne and Becker dystrophies?	Abnormalities in the dystrophin gene
How does Duchenne dystrophy present?	Difficulty standing and walking, waddling gait with lumbar lordosis, shortening of the calf muscles with pseudohypertrophy by age 5
How does the disease progress?	Most become wheelchair dependent by age 12 and subsequently develop progressive kyphosis and contractures. Death usually occurs in the third decade from respiratory compromise and infections.
How does Becker dystrophy present?	Similar but less severe symptoms and a later onset than Duchenne
What lab result supports the diagnosis?	Elevated creatine phosphokinase (CPK)

How is the diagnosis confirmed?

Muscle biopsy showing necrosis with variation in muscle fiber size and no dystrophin

What are the treatment options in muscular dystrophy?

Largely supportive with physical therapy, bracing, and pulmonary care

CASE 14

A 38-year-old female with history of urinary tract infections and diabetes presents to your office complaining of difficulty climbing stairs and putting her groceries away in the kitchen cabinets. She has not had this problem before. While listening to her, you notice an erythematous rash around her eyes.

What diagnosis do you suspect?

Dermatomyositis

What are the two most common forms of inflammatory myositis?

Polymyositis (PM) and DM

How do you tell them apart?

DM has a skin rash

Describe the heliotrope rash associated with DM shown in Figure 7-2.

Red violaceous eruption on the upper eyelids

Describe Gottron sign associated with DM shown in Figure 7-3.

Symmetric erythematous violet-colored eruption with scales over the extensor surfaces of the metacarpophalangeal and interphalangeal joints of the fingers

Describe the weakness in PM and DM.

Progressive symmetric weakness of proximal muscles of hips and shoulders, often with myalgia and muscle tenderness

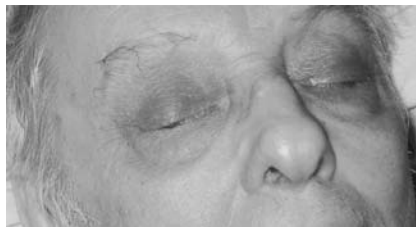

Figure 7-2. Classic heliotropic rash about the eyes of this patient with DM.

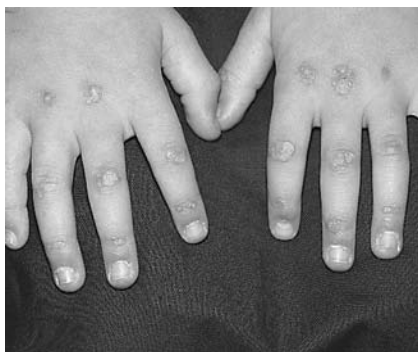

Figure 7-3. Dermatomyositis: Gottron papules on joints of fingers.

What lab values should be elevated?	CPK and aldolase to establish the extent of muscle breakdown
What special test will aid in making the diagnosis?	EMG with an “irritative” myopathy pattern
How is the diagnosis confirmed?	A muscle biopsy that reveals necrosis, degeneration, regeneration, and an inflammatory cell infiltrate
What additional workup needs to be done?	Search for an underlying malignancy
Why?	An underlying malignancy is found in 15% to 25% of cases
How is myositis treated?	Prednisone with gradual taper once a response is obtained; treat underlying malignancy if found

VASCULAR DISEASES OF THE CENTRAL NERVOUS SYSTEM

CASE 15

A 72-year-old male with history of diabetes, COPD secondary to smoking, hypertension, CAD s/p CABG 6 years ago presents to the ER with right-sided weakness and dysarthria that began 6 hours ago. On physical exam, you appreciate right-sided weakness and a strong bruit over the carotids.

What should be in your differential diagnosis?	Transient ischemic attack (TIA) stroke, amaurosis fugax (shade comes down over ipsilateral eye) indicating possible internal carotid stenosis
What risk factors for atherosclerosis does he have?	Atherosclerosis, smoking, hypertension, diabetes mellitus
What additional risk factors are associated with atherosclerosis?	Hypothyroidism, hyperuricemia, hypercholesterolemia, or hypertriglyceridemia
What is the significance of the carotid bruit?	Suggestive of significant carotid stenosis
What diagnostic tests should you order?	
Labs	Chem 8, CBC, PT/INR, CK-MB, and troponin
Imaging	CT or MRI of head, duplex ultrasound of all 4 neck vessels or magnetic resonance arteriography, transthoracic echocardiogram (TTE)
Why 4 vessel ultrasound?	Present status of collateral circulation important to surgeon
Why TTE?	High incidence of coronary artery disease and MI in patients with severe carotid stenosis
How do you detect emboli breaking off the carotid plaque?	Transcranial Doppler studies of the circle of Willis
Additional studies if this patient was younger with a family history of stroke?	Antithrombin III, anticardiolipins, serum homocysteine, factor V Leiden, protein C, protein S, sickle cell
What is the medical treatment?	Treat known risk factors, aspirin, aspirin plus dipyridamole, and clopidogrel
What surgical treatment is available?	Carotid endarterectomy if stenosis >50% lumen or if stenosis demonstrates ulcerated plaques

Why surgery for ulcerated plaques?

To remove source of platelet or thrombotic emboli

CASE 16

A 64-year-old male with history of HTN, Achilles tendon rupture, CAD s/p MI with abnormal LV function (akinetic portion of ventricle) presents to the ER in atrial fibrillation with left-sided hemiparesis and aphasia with the STAT CT scan shown in Figure 7–4.

What's the most likely cause?

Cardioembolic stroke

How does cardioembolic stroke present?

Any of the following: acute onset hemiparesis, hemianesthesia, impaired level of consciousness, decreasing level of consciousness (cerebral edema), loss of vision (homonymous hemianopia), loss of language (dysphasia or aphasia), neglect on paralyzed side (anosognosia autotopagnosia)

What are his known risk factors?

Atrial fibrillation and akinetic portion of LV from prior MI

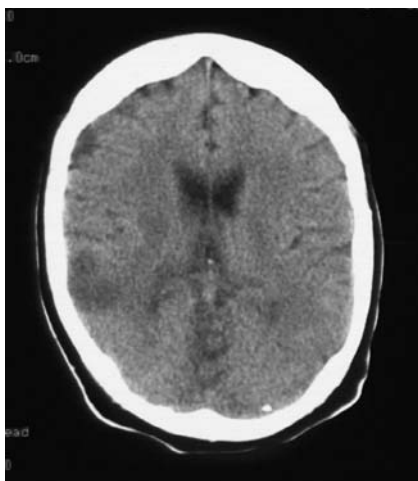


Figure 7–4. CT Scan showing left MCA stroke.

Name other risk factors predisposing to embolism.	Diseased heart valves (rheumatic fever, bacterial endocarditis), recent MI with mural thrombosis, ventricular aneurysm, patent foramen ovale (PFO), artificial heart valves, ulcerated atheromatous plaques in ascending aorta or internal carotid artery
What causes the stroke?	Cerebral infarction and loss of neurologic function because of embolism of a cerebral artery
What do you expect to find on neurologic examination?	Hemiparesis or hemiplegia with flaccid limbs and depressed reflexes, and extensor plantar responses on affected side, gradual development of spasticity, and increased reflexes on affected side after 72 hours
What labs should you order?	CBC, PT/INR, Chem 8, CK-MB, troponin
What tests should you order?	Noncontrast CT scan of head to determine if ischemic or hemorrhage infarction and anatomic site, EKG, 2D echocardiogram, TTE, 4 vessel (carotid and vertebral arteries) duplex ultrasound (Doppler and real time), cardiology consultation to rule out or detect associated heart disease (stroke patients have a high risk of MI)
What is the treatment strategy in this patient with atrial fibrillation?	Assume cardiac embolism and anticoagulate
When else is anticoagulation treatment warranted?	If studies reveal source of embolism, i.e., valvular disease, PFO, mural thrombus, cerebral arteritis, recent MI
When should anticoagulants be prescribed?	Use anticoagulants—heparin followed by warfarin—in cases of proven embolus
What tests should be ordered if patient is anticoagulated?	Activated clotting time or partial thromboplastin time (PTT) for heparin therapy. PT with INR for Coumadin therapy

What additional therapy is indicated for long-term prevention of recurrent stroke or MI? Treat atrial fibrillation; may need cardioversion and/or antiarrhythmic drugs. If present treat hypertension, diabetes mellitus, hyperlipidemia, hyperuricemia, hypothyroidism, obesity, tobacco abuse, alcoholism.

When is surgical treatment indicated? PFO or heart valve replacement

What therapy is available for patients who cannot or refuse to take anti-coagulation? Aspirin, aspirin plus dipyridamole, clopidogrel, or ticlopidine

CASE 17

A 72-year-old male with history of HTN, CAD s/p 3-vessel CABG 4 years ago, and TIAs presents to the ER after developing over 24 hours of a clumsy right hand and dysarthria. Because he had TIAs in the past he thought it would go away as long as he kept taking his aspirin. Preliminary MRI shows multiple small subcortical lesions.

What's your diagnosis? Lacunar stroke

What is the usual presentation? Clumsy hand with dysarthria, dysphasia, or ataxia

What causes it? Small vessel vasculopathy due to atherosclerosis, arteriosclerosis, or embolism of terminal penetrating arteries

What are the risk factors? Hypertension, atherosclerosis and diabetes mellitus, and carotid artery stenosis

What radiographic studies should be ordered? CT or MRI will show small localized lesions which may be cortical, subcortical, or located in deeper structures, including the internal capsule, caudate nucleus putamen, brainstem, or cerebellum.

What is the treatment?	Treat underlying risk factors. Give aspirin or clopidogrel.
Surgical treatment?	Carotid endarterectomy in those patients with >50% stenosis to eliminate repeated embolism
What is the prognosis with mild symptoms?	Most have rapid improvement, but major stroke or MI is a risk factor.

CASE 18

Your attending asks you to see a patient in the ER examining room who had a stroke and asks you to obtain a history from the patient and his wife and tell him where the lesion was without seeing the imaging reports.

What are the main arteries to consider before walking into the room?	Middle cerebral artery, anterior cerebral artery, posterior cerebral artery, and verteobasilar artery
Recall common symptoms of stroke in	
Anterior cerebral artery	Contralateral leg weakness and behavioral changes
Middle cerebral artery	Contralateral limb weakness (arm > leg) with sensory loss, homonymous hemianopsia, aphasia (dominant hemisphere involvement), sensory neglect or apraxia (nondominant hemisphere)
Posterior cerebral artery	Contralateral homonymous hemianopsia, sensory loss, thalamic pain, or involuntary movements
Vertebrobasilar artery (unilateral occlusion)	Ipsilateral cranial nerve abnormalities with contralateral weakness and sensory deprivation
What imaging modalities will help you determine if it's ischemic or hemorrhagic?	MRI or CT

Which test is more likely to show signs of cerebral ischemia soon after a stroke?

MRI

What are the basic principles to treating strokes?

Do not use antihypertensives in a patient with an evolving stroke (may further decrease cerebral blood flow); search for underlying causes (e.g., carotid embolism, carotid artery stenosis, hemorrhagic bleed), consider heparin in nonhemorrhagic-evolving stroke, aspirin, or Plavix.

CASE 19

A 64-year-old male with history of uncontrolled hypertension, atrial fibrillation on Coumadin, hiatal hernia, and diverticulosis presents to the ER after a motor vehicle collision with sudden onset headache, nausea, vomiting followed by change in mental status.

What most likely happened?

Intracranial hemorrhage

What are the pathologic changes prior to intracranial hemorrhage?

Arteriolosclerosis of the penetrating vessels entering the brain leading to weakness of vessel walls and occasionally aneurysm formation (Charcot–Bouchard aneurysm)

What risk factors does he have?

Hypertension, anticoagulated (Coumadin), trauma

How might his symptoms advance?

Stupor and coma

What 3 things should you do first in the ER?

1. Establish airway
2. Obtain coagulation profile (PT and PTT)
3. Obtain head CT

What are the associated findings in the spinal fluid?

CSF can be clear unless there has been associated bleeding into the subarachnoid space.

CT is diagnostic of intracerebral hemorrhage. What's the treatment?

Control hypertension, maintain airway, and monitor the heart. Stabilize coagulation deficits and lower intracranial pressure, if necessary.

CASE 20

A 32-year-old medical resident with history of polycystic kidney disease and coarctation of the aorta presents after weight lifting with acute onset of severe headache with pain spreading to back of head and stiff neck. Later he developed nausea, vomiting, and confusion. Prior to this, the patient had a headache that was unresponsive to over-the-counter analgesics, which had worked before. This is the worst headache of his life. The STAT noncontrast CT head taken in the ER is shown in Figure 7–5.

What diagnosis is most likely?

SAH

What are the causes of SAH?

Ruptured saccular (Berry) aneurysm around the circle of Willis, trauma, bleeding diathesis, arteriovenous malformations, and illicit drug use (cocaine and amphetamine)

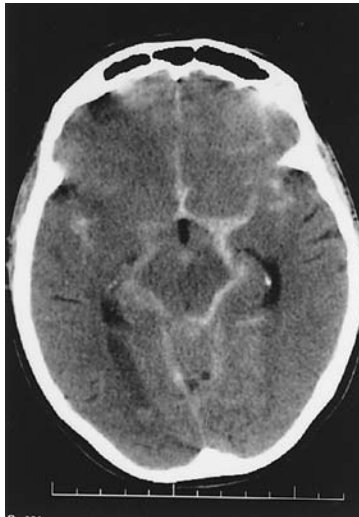


Figure 7–5. CT in the axial plane of a patient with SAH. Bone is white, acute blood (white) outlines the subarachnoid space, brain is grey, and cerebrospinal fluid in third and lateral ventricles is black. (From Haines DE. *Neuroanatomy: An Atlas of Structures, Sections, and Systems*. 6th Ed. Philadelphia: Lippincott Williams & Wilkins, 2004.)

Based on history, what cause do you suspect?

Ruptured Berry aneurysm

What were the clues?

PCK and coarctation of aorta are both associated with Berry aneurysms.

When does ruptured aneurysm occur?

When patient is active, at work, exercising, or straining, but it can occur at rest also

How does a ruptured aneurysm present?

Sudden-onset severe headache (worst headache of their life) with pain spreading to occiput and neck and nuchal rigidity

What's the name for the headache that the patient had that was unresponsive to over-the-counter medications?

Sentinel headache

Is sentinel headache always a feature of saccular aneurysm?

No, sentinel headache rarely indicates presence of aneurysm.

What fundoscopic change might you find on physical exam?

Papilledema can develop as early as 6 hours after rupture of aneurysm

What labs should be included in the workup?

CBC, PT, PTT, INR, and CMP

What's the diagnostic test?

CT head without contrast, showing blood within the pia and arachnoid layers

What's the therapy?

IV narcotics for pain, diazepam for anxiety and seizure prophylaxis, surgery for drainage, if easily accessible

Prognosis of ruptured saccular aneurysm?

30% die within 24 hours; 40% die within 7 days; 50% of survivors have second bleed; 60% die within 6 months.

EPISODIC DISORDERS

CASE 21

A 48-year-old female with history of drug abuse presents to the ER with uncontrollable jerking of the right arm for the last 5 minutes. She says this has never happened before.

What do you suspect?	New onset of seizure
What's in the differential diagnosis for seizure?	TIA, migraine, metabolic derangements, transient global amnesia, paroxysmal movement disorders, pseudoseizure
What are common causes of seizure in the various groups below?	
Children	Fever, CNS infections, and electrolyte abnormalities
Adult	Alcohol and drug withdrawal, electrolyte imbalance, trauma, eclampsia
Elderly	Trauma, brain cancer, CVA
What types of seizures are there?	Partial (simple and complex) and generalized (absence seizures, tonic-clonic, tonic, clonic, myoclonic, and atonic)
How are simple and complex partial seizures similar?	Both have focal motor or sensory deficits
How are they different?	Simple has no alteration in consciousness while complex does
What type of seizure does this patient present with?	Simple partial seizure
What cause do you suspect?	ETOH or drug withdrawal
What labs should you order?	CBC, chemistry studies for electrolytes, glucose, calcium, magnesium, uremia, and hepatic encephalopathy, and toxicology screen

What diagnostic tests are helpful?	EEG and MRI to locate focal abnormality
Can simple seizures progress to something else?	Yes, either type can evolve secondarily to generalized
Describe the following types of generalized seizures.	
Absence (petit mal)	Brief loss of consciousness without loss of muscle tone, aura, or postictal confusion
Tonic-clonic (grand mal)	Aura may occur before tonic contraction with arched back followed by rapid alteration of muscle contraction and relaxation, postictal confusion, and headache common
What's the workup?	Same as partial seizure
How are seizures treated?	A single seizure of unknown cause, or seizures secondary to specific or treatable causes (febrile seizures, alcohol withdrawal seizures, seizures secondary to hypoglycemia, etc.) do not require initiation of anticonvulsant therapy.
When is chronic anticonvulsant therapy warranted?	Recurrent seizures
Name commonly used drugs of choice for	
Simple partial, complex partial, and generalized tonic-clonic seizures	Phenytoin, carbamazepine, and valproic acid
Absence, myoclonic, and atonic seizures	Valproic acid and ethosuximide
When is surgery warranted?	Seizures refractory to medical treatment
What is status epilepticus?	Continuing or recurring seizures without complete recovery between attacks, lasting more than 20 minutes

What type of seizure does it occur with?	Any type
What labs should you order?	CBC, chemistry panel, anticonvulsant drug levels, and arterial blood gas should be sent STAT; also send a toxicology screen and do a finger stick for glucose.
What's the medical therapy?	IV fosphenytoin followed by IV lorazepam if seizures persist
What's required if respiratory failure develops?	Intubation

Chapter 8

Rheumatology

GENERAL MUSCULOSKELETAL PROBLEMS

CASE 1

A 40-year-old female with history of irritable bowel syndrome (IBS, a.k.a visceral hypersensitivity) presents with complaints of multiple areas of tender muscles, stiffness, generalized fatigue, and not sleeping well.

What's your differential diagnosis?

Muscle strain or sprain, fibromyalgia, hypothyroidism, psychogenic rheumatism, polymyalgia rheumatica (PMR), temporal arteritis (TA)

Which is most likely?

Fibromyalgia

Why?

Because she presents with the classic poorly localized muscle pain that spares the joints, stiffness, fatigue, nonrestorative sleep with an associated condition of IBS

What other associated conditions are there?

Tension headache and dysmenorrhea

What physical exam findings do you expect to find?

Bilateral tender points over the trapezius ridge, posterior cervical musculature, upper gluteal area, and trochanteric bursae

What are the associated lab findings?

Normal white blood cell (WBC) count and erythrocyte sedimentation rate (ESR)

How is the diagnosis made?

Clinical history and physical exam

What is the treatment strategy?

Tricyclic antidepressants, physical therapy, and aerobic exercise for muscle aches. No role for NSAIDs.

CASE 2

A 20-year-old female presents 1 week after camping in Connecticut in July with a new rash (Figure 8–1) with low-grade fever, headache, malaise, and myalgias.

What is your differential diagnosis?

Lyme disease, viral syndrome, juvenile rheumatoid arthritis (RA)

Which is most likely?

Lyme disease

Why?

Patient presents with classic rash of erythema chronicum migrans (bulls-eye appearance) 1 week after (onset often 7–10 days) camping in high prevalence area (Connecticut) during peak incidence time (May to August) with mild influenza-like symptoms

Do all patients present like this 1 week after?

No, some may only have the rash.

What laboratory test should you order first?

Enzyme-linked immunosorbent assay (ELISA)

What additional test should you order if the ELISA test is positive?

A Western blot to confirm because ELISA tests are often false-positives

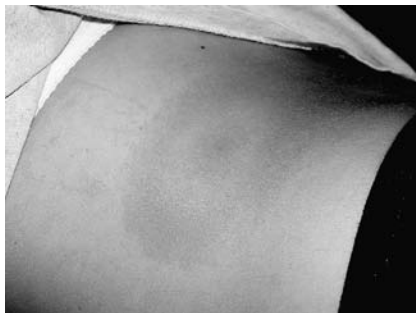

Figure 8–1.

(From Goodheart HP. Goodheart's Photoguide of Common Skin Disorders. 2nd Ed. Philadelphia: Lippincott Williams & Wilkins, 2003.)

Can ELISA and Western blot distinguish between active and previous infections?	No
How is the diagnosis made?	Strong clinical suspicion (endemic area, tick bite, and rash) with positive ELISA and Western blot
What causes Lyme disease?	The tick spirochete <i>Borrelia burgdorferi</i>
What areas of the country have a high prevalence of this tick?	Northeastern coastal states, the upper Midwest, and northern California
What is the treatment?	Oral doxycycline or amoxicillin and probenecid
Why is it important to treat Lyme disease?	To prevent potential rheumatologic, cardiac, and neurologic complications

CASE 3

A 62-year-old female with history of HTN and diabetes presents with progressive left-sided throbbing temporal headaches, scalp tenderness, and slight blurring of vision.

What's your differential diagnosis?	TA, cerebral vascular accident, retinal detachment
Which diagnosis is most likely?	TA
Why?	
Age	Over 50
Headache	Unilateral and temporal
Eyesight	Blurred
What physical exam finding would support your diagnosis?	Nodular, enlarged, tender, or pulseless temporal artery

Is this always present?	No
What additional symptom is present in some patients and fairly specific for TA?	Jaw or tongue claudication with mastication
What lab test should you order?	ESR
What value supports the diagnosis of TA?	>50
How is diagnosis confirmed?	Temporal artery biopsy
What do you expect the pathology report to say?	Granuloma with giant multinucleated giant cells of the intima and media with disruption of the internal elastic lamina
What causes TA (a.k.a. giant cell arteritis)?	A progressive inflammatory disorder of unknown etiology that affects mainly large cranial arteries, primarily the temporal artery
What is the TA treatment?	High-dose oral prednisone (60 mg/daily) immediately without biopsy results with gradual tapering
Why start treatment without biopsy confirmation?	To prevent irreversible blindness
6 months later the same woman returns to clinic and is grateful to you for saving her vision, but complains of fatigue and difficulty with climbing stairs, getting out of bed in the morning, and combing her hair because of muscle pain and stiffness. What's your differential diagnosis?	Polymyositis/dermatomyositis, PMR, thyroid disease, viral myalgia or myopathy secondary to steroids, alcohol or electrolyte imbalance
Which is most likely?	PMR

Why?	It often coexists in patients with a history of TA and often presents in elderly patients over the age of 50.
Why is polymyositis less likely?	The patient complains of muscle pain and stiffness, not weakness.
What labs should you order?	CBC, TSH, ESR, CK, and aldolase
What results would support your diagnosis of PMR?	Anemia and elevated ESR
How is PMR diagnosed?	Clinically based on pain and stiffness (not weakness) in the shoulder and pelvic girdle area; fever, malaise, and weight loss may be present.
What causes PMR?	PMR is a chronic, intermittent, inflammatory disease of the large arteries.
What's the treatment?	Low-dose prednisone with gradual tapering

CASE 4

A 48-year-old female with history of degenerative joint disease (DJD) and prolapsed bladder presents with progressive difficulty climbing stairs, combing her hair, and a new facial rash.

What is this woman's main clinical problem?	Proximal muscle weakness of the shoulder and pelvic girdle
What's your differential diagnosis?	Dermatomyositis, polymyositis, drug-induced or inflammatory myopathy, thyroid disease, systemic lupus erythematosus (SLE), vasculitis
Physical exam confirms 3/5 bilateral shoulder and pelvic girdle weakness and a heliotrope skin rash (bilateral raccoon eyes). What's the most likely diagnosis?	Dermatomyositis

What labs should you order to support your diagnosis?	Elevated creatine phosphokinase and aldolase
What additional test could you order?	EMG
What would you expect it to find?	Muscle irritability, low-amplitude potentials, polyphasic potentials, and fibrillations
How is the diagnosis confirmed?	Muscle biopsy
What do you expect the pathology report to say?	Muscle cell degeneration with an inflammatory infiltrate, phagocytic debris, and perifascicular muscle fiber atrophy
How would polymyositis be diagnosed?	Identical to dermatomyositis without the heliotrope skin rash
Describe the treatment strategy for both DM and PM.	High-dose oral prednisone with taper to goal of normalizing muscle enzymes

CASE 5

A 44-year-old woman with history of joint pains and DJD presents with complaint of her finger tips turning blue in cold weather and difficulty swallowing her food over the past month.

What's your differential diagnosis for cyanotic fingers?	Raynaud phenomenon, RA, progressive systemic sclerosis, SLE, Buerger disease
Which is most likely given the brief history?	Raynaud phenomenon
Does her complaint of dysphagia broaden your differential from simply Raynaud to explain her symptoms?	Yes
Why?	Raynaud phenomenon and esophageal dysmotility are part of a limited form of systemic scleroderma called CREST syndrome

What do the letters in CREST stand for?	Calcinosis, Raynaud phenomenon, Esophageal dysmotility, Sclerodactyly, Telangiectasias
Who is at the greatest risk of developing CREST?	Women in their third to fifth decade (this patient was female and 44)
How many patients with CREST (limited scleroderma) commonly present early in the disease?	Thick, tight, shiny skin, Raynaud phenomenon, and polyarthralgia (this patient had joint pain)
How is the diagnosis made?	Strong clinical suspicion, anticentromere antibodies
What problems are associated with the antibody tests?	Lack of sensitivity and (usually) specificity decreases their effectiveness in making the diagnosis.
What is the pathogenesis behind CREST syndrome?	Diffuse fibrosis of the skin and internal organs of unknown etiology
What is the treatment strategy?	Symptomatic and supportive because no definitive treatment is available
What is the treatment for the following?	
Severe Raynaud phenomenon	Vasodilating drugs (Ca-channel blockers or prazosin)
Skin and periarticular changes	Physical therapy
GI hypomotility (dysphagia)	Aggressive gastroesophageal management, antibiotics for intestinal bacteria overgrowth, and prokinetic agents such as metoclopramide if significant gastroparesis develops

CASE 6

A 38-year-old female returns to your clinic for follow-up of low-grade fever, fatigue, and malaise that was attributed to a viral illness and symptomatic therapy with acetaminophen recommended. She now complains of joint pain, bright light sensitivity, nausea, and a rash on her face that is in the shape of a butterfly.

What is most striking about her complaints?	Multisystem involvement
What is your differential diagnosis for multisystem complaints?	HIV, SLE, scleroderma, RA, mixed connective tissue disease
Which is most likely in her?	SLE
Why?	Waxing and waning of multisystem complaints with fever, fatigue, malaise, malar rash ("butterfly" skin rash), and photosensitivity is a common initial presentation for SLE.
What causes it?	Unknown, but autoantibodies to nuclear and other autoantigens are suspected
Name other common presentations of SLE by organ system.	
Musculoskeletal	Arthralgias, myalgias, and arthritis
Central nervous system	Seizures, psychosis, anxiety, and depression
Cardiac	Pericarditis, myocarditis, endocarditis, and arrhythmias
Gastrointestinal	Nausea, vomiting, anorexia, and abdominal pain
Vascular and hematologic	Anemia, thrombocytopenia, lymphadenopathy, and splenomegaly
Immune	Lymphadenopathy and splenomegaly
Renal	Impairment may be from associated vasculitis.
When should the diagnosis be considered?	When a young woman presents with multisystemic findings
What serologic markers should you order?	Antinuclear antibody, anti-double stranded DNA, and anti-Sm

Which serologic tests are more specific?	Anti-double stranded DNA and anti-Sm
The diagnosis is made. What is your treatment for her?	NSAIDs, hydroxychloroquine (for her dermatologic and musculoskeletal manifestations)
Are steroids indicated in her case now?	No
When are steroids appropriate?	For severe systemic symptoms (glomerulonephritis, severe CNS involvement, thrombocytopenia, and hemolytic anemia) and debilitating manifestations unresponsive to conservative treatment

DISORDERS OF THE BACK, SPINE, AND BONE

CASE 7

A 22-year-old male presents to your clinic complaining of low back pain after falling on his back while playing basketball.

What's your brief differential diagnosis for low back pain?	Lumbar strain, disk disease, vertebral fracture
How do they commonly present?	
Strain	Localized lower back pain without radiation (nerve root not involved) with regional tenderness, severe restriction of movements, and paraspinal muscle spasms on exam
Lumbar disk disease	Back pain with decreased mobility and compensatory posture. Pain will radiate to the groin and or leg (usually unilateral) if nerve root is compressed.
Vertebral fractures	Sudden onset of excruciating pain
What are red flag symptoms of back pain?	Bowel or bladder incontinence

What level is involved if bowel or bladder symptoms are present?

Conus medullaris or cauda equina

What tests should be ordered if lumbar disk disease or vertebral fracture is suspected?

X-ray or CT scan

How are the various diagnoses made?

Clinical presentation and x-ray or CT scan

What is the treatment strategy for acute lower back pain?

NSAIDs, bed rest, muscle relaxants, and surgical consult if radiographic studies reveal underlying pathology or red flag symptoms are present

What additional medication should be prescribed without delay if red flag symptoms are present?

IV steroids

CASE 8

A 17-year-old male with history of multiple admissions for heroin overdose presents to the ER complaining of dull back pain. He denies any recent trauma or history of back disease. Spinal tenderness, swelling, warmth, and erythema exist in the mid-thoracic region without radiation.

What's in your differential diagnosis for back pain?

Strain, disk disease, fracture, and osteomyelitis

Which should be highest on your differential diagnosis for this patient?

Osteomyelitis

What causes it?

An infection of the bone, usually caused by direct or hematogenous spread of bacteria from a wound or local infection

Why do you suspect it in this patient?

IVDA (strong risk factor), spinal tenderness, and warmth on exam

What other risk factors exist for osteomyelitis?	Coexisting infections, age, diabetes, and immunodeficiency (HIV)
What are other common presentations of osteomyelitis?	Incapacitated or limping with dull pain over long bones (femur, humerus, tibia)
What physical exam clues did this patient have for osteomyelitis?	Point tenderness, swelling, warmth
What additional findings are common?	Systemic fever, erythema, effusion, decreased range of motion, and regional muscle spasms in the affected area
What should you order?	
Labs	WBC count, ESR, C-reactive protein, and blood cultures
Imaging in increasing order of sensitivity and specificity	X-ray, radionucleotide bone scanning, CT, and MRI
What's the problem with x-ray?	May not be positive until at least 10 days after infection
So, if your clinical suspicion is high and the x-ray is negative, should you order additional imaging?	Yes
What is a common radiographic report for osteomyelitis?	Destruction of normal bony architecture (bone erosion, periosteal elevation) with evidence of soft-tissue swelling
Is imaging enough for the diagnosis?	No, it is suggestive.
What additional diagnostic test should you order to support the diagnosis and direct therapy?	Gram stain and culture of needle-aspirated pus from the bone
How is the diagnosis ultimately made?	Bone biopsy and culture of specimen

What causative organisms do you suspect in Nondiabetic?

Staphylococcus aureus and coagulase-negative staphylococci

Diabetics?

Polymicrobial infections with Gram-negative rods and anaerobes

What's your empiric therapy for

Gram-positive?

Nafcillin

Gram-negative?

Third-generation cephalosporin (ceftriaxone)

What will determine which antibiotic to continue treatment with?

Culture and sensitivity results

How long will you need to treat for?

Four to 6 weeks

When is surgical debridement necessary?

Failed medical treatment, undrained pus, or septic arthritis

THE SERONEGATIVE SPONDYLOARTHROPATHIES

Name the four spondyloarthropathies

Ankylosing spondylitis, Reiter syndrome, colitic arthritis, psoriatic arthritis

What do they have in common?

Spondylitis, sacroilitis, inflammation at the tendon insertion points (enthesopathy), asymmetric oligoarthritis, extraarticular finding (inflammatory eye disease, urethritis, mucocutaneous lesions), and HLA-B27 association

CASE 9

A 23-year-old male presents with complaints of gradual onset of morning stiffness and low back pain that worsens with rest and improves with activity.

What's your differential diagnosis?

Ankylosing spondylitis, Reiter syndrome, RA, musculoskeletal strain

What's most likely?	Ankylosing spondylitis
Why?	Male, under 40, morning stiffness, and low back pain that lessen with activity is classic presentation
What causes ankylosing spondylitis?	Inflammation and ossification of joints and ligaments of the spine and sacroiliac joints (hips and shoulder most common) of unknown etiology
What do you expect to find on physical exam?	Decreased range of motion in lumbar spine and loss of lumbar lordosis
What lab tests will you order to support your diagnosis?	Elevated HLA-B27 and ESR and absent rheumatoid factor
What diagnostic imaging study should you order?	X-ray of the lumbar spine and sacroiliac joints
What diagnostic phrase do you expect to read in the report?	"Bamboo-spine" with fusion of the sacroiliac joints
The diagnosis of ankylosing spondylitis is made. What's your treatment?	NSAIDs (indomethacin) for symptomatic relief, physical therapy, and sleep on a firm bed without a pillow

CASE 10

A 24-year-old male presents with history of diarrhea 3 weeks ago and returns to the clinic with redness in the eyes, tearing, painful urination, mouth sores, and right knee pain.

What's your differential diagnosis?	Reiter syndrome, arthritis associated with IBD, gonococcal arthritis, juvenile RA
Which is most likely?	Reiter syndrome
What's another name for it?	Reactive arthritis
Why is it called this?	It often occurs after (reacting to) STD or diarrhea (as in this patient)

Which organisms are associated with the diarrhea seen in Reiter syndrome?

Salmonella, Shigella, or Yersinia

What classic triad of Reiter's did this patient present with?

Conjunctivitis (redness in the eyes, tearing), urethritis (painful urination), and asymmetric oligoarthritis (right knee pain)

What lab test findings do you expect?

Positive HLA-B27, elevated WBC, and ESR

How will you make the diagnosis?

Clinical history and presentation

What is the treatment?

NSAIDs (indomethacin) for pain and inflammation, referral to ophthalmologist if suspect uveitis, treat underlying STD if present

CASE 11

A 22-year-old female with a long history of ulcerative colitis (UC) who has experienced a recent flare due to noncompliance with her rx medication presents with bloody diarrhea and knee and ankle pain.

What's your brief differential diagnosis?

Septic arthritis, colitic arthritis, gonococcal arthritis

What is the most likely explanation for her joint pain?

UC flare causing colitic arthritis

Why?

History of IBD, peripheral joint discomfort (not spinal)

What other extraintestinal features of IBD may be found on exam?

Pyodermic gangrenosum, uveitis, erythema nodosum

Should joint aspiration be considered?

Yes, it will help rule out septic arthritis.

What lab tests should you order?

Stool studies, UA, HLA-B27, CBC, and blood cultures if bacteremia suspected

How is the diagnosis made?	Clinical presentation and a negative HLA-B27 lab test
What is the treatment?	Sulfasalazine for intestinal inflammation and NSAIDs for peripheral arthritis; local injection of glucocorticoids and physical therapy may be used as needed.

CASE 12

A 31-year-old female with known psoriasis and IBS presents with complaints of swollen tender fingers. On exam you confirm distal interphalangea (DIP) joint swelling, warmth, tenderness, and restricted motion with pitting of the nails.

What's your differential diagnosis?	Psoriatic arthritis, gout, Reiter syndrome, osteoarthritis (OA)
Which is most likely?	Psoriatic arthritis
Why?	Asymmetric oligoarthritis or symmetric polyarthritis presenting in a patient with known psoriasis and nail pitting is highly suggestive of psoriatic arthritis.
What is a classic description of the DIP joint on exams?	Sausage shaped
What radiographic image should you order?	Hand x-ray
What classic radiographic finding do you suspect?	Pencil and cup deformity of the phalynx
How will you make the diagnosis?	Clinical presentation with associated psoriatic findings on the skin, nail, and hair
How is it distinguished from rheumatoid arthritis?	Rheumatoid factor is negative in psoriatic arthritis
What is the treatment?	NSAIDs (indomethacin), intraarticular steroids if oligoarticular form of the disease

OSTEOARTHRITIS AND ARTHROPATHIES

CASE 13

A 37-year-old previously healthy male presents with difficulty walking due to severe pain, swelling, redness, and warmth of his right great toe over the last 24 hours after partying all night at a friend's bachelor party. His hangover has subsided, but his big toe pain continues despite taking Tylenol.

What's your differential diagnosis?	Gout, pseudogout, hyperparathyroidism, fracture secondary to trauma sustained while intoxicated
Which is most likely?	Gout
Why?	Acute attack of excruciating pain in a single joint of the foot or ankle, most commonly the big toe (Podagra), is classic for gout.
What could have triggered this attack?	Dehydration and high alcohol intake
What other risk factors for gout are there?	Surgery, fasting, and binge eating (meat)
What lab tests should you order?	CBC, ESR, and serum uric acid
Is hyperuricemia required to make the diagnosis?	No, one-third of patients have normal serum uric acid levels during an acute attack.
How will you make the diagnosis?	Aspirate the joint
What finding is diagnostic?	Needle-shaped negatively birefringent crystals within PMNs under a polarized light microscope
What causes gout?	An inborn error in uric acid metabolism leads to crystal deposition in the peripheral joints.

What is the first line of treatment?	High-dose oral NSAIDs or colchicine (if contraindication to NSAID use)
Name two common contraindications to NSAID use.	History of NSAID-related bleed and advanced renal insufficiency
What prophylactic medications can be used between attacks?	Allopurinol 300 mg daily (if consistent hyperuricemia due to uric acid overproduction) or probenecid (if chronic underexcretion of uric acid ≤ 700 mg in urine per 24 hours)

CASE 14

A 55-year-old obese male with history of HTN, diabetes, and lumbago presents with bilateral knee pain that has worsened slowly over the last 2 years. The knee pain is worse in the morning, lasts less than 30 minutes, and improves with activity.

What diagnosis do you suspect?	OA, also known as degenerative joint disease
What causes OA?	Deterioration of the articular cartilage and formation of reactive new bone at the articular surface in one or more joints
What in the history is consistent with OA?	
Age	Most often over 40 (he's 55)
Weight	Obesity
Joints affected	Those under chronic use or weight bearing
Symptom onset and duration	Short-lived morning stiffness and pain (often less than 30 minutes)
What do you expect to find on physical exam?	Decreased range of joint motion, pain with movement, small effusions, and crepitus

What physical exam finding would be present in patients with OA in the hands from overuse?	Heberdon nodes (body deformity at DIP common) and Bouchard nodes (bony deformity at PIP less common)
Are blood tests required to make the diagnosis?	No, patients have normal WBC and ESR.
What would be found if the joint was aspirated?	Straw-colored joint fluid with few WBCs
What imaging should be ordered?	Plain x-rays of affected joints
What findings do you expect?	Joint space narrowing with osteophytes
How is it diagnosed?	Clinical exam and x-ray findings
What's your first line of therapy?	NSAIDs or aspirin, weight reduction, exercise, physical therapy
What if these fail and the patient is severely disabled?	Total joint replacement (knee replacement most common)

CASE 15

A 68-year-old male with history of hemochromatosis, diabetes, and hypertension presents with left knee warmth and tenderness that has progressed over the last week.

What's your differential diagnosis?	Gout, pseudogout, septic arthritis, or trauma
What tests should you order?	
Labs	CBC, ESR, PT, and INR
Imaging	X-ray
Procedure	Aspiration of knee synovial fluid
How will you make the diagnosis?	Synovial fluid analysis

Synovial fluid analyzed under polarized light microscope shows positively birefringent rhomboid-shaped crystals. What's your diagnosis?	Pseudogout
What causes pseudogout?	Accumulation of calcium pyrophosphate crystals in the peripheral joint space
What risk factors did this patient have for pseudogout?	Old age, hemochromatosis, and diabetes
Name other risk factors.	Trauma, advanced osteoarthritis, gout, hyperparathyroidism, hypothyroidism, and amyloidosis
What joint is most commonly affected?	Knee (as in this patient)
What is the treatment?	Brief high-dose course of NSAIDs (indomethacin)

CASE 16

A 33-year-old female with history of UTIs presents with morning stiffness lasting 90 minutes with fatigue, weakness, and tender knuckles. On exam you find symmetrical PIP and MCP tenderness and swelling.

What's your differential diagnosis?	RA, gout, erosive osteoarthritis, pseudogout, SLE
Which is most likely?	RA
What supports RA?	
Age	Often presents in second to fifth decade (she's 33)
Gender	Females > Males
Common symptoms	Significant morning stiffness lasting more than 1 hour with fatigue, weakness, and joint pain

Physical exam findings	Symmetrical joint pain, tenderness, swelling, and warmth that most commonly involves the hands (PIP and MCP joints very common, DIP spared)
What other joints can be affected?	Wrists, elbows, ankles, and feet
What tests should you order?	CBC, ESR, RF, synovial fluid analysis
What results would support RA in the CBC?	Mild anemia
ESR?	Elevated
RF?	>1:80
Synovial fluid?	Yellow-white, turbid fluid with WBC in the range of 3500–50,000 cells/ μ L
How is the diagnosis made?	A positive rheumatoid factor with an elevated sedimentation rate with presentation of significant morning stiffness lasting more than 1 hour and symmetric polyarthritis
What causes RA?	A chronic systemic inflammatory disease of unknown etiology causing symmetric joint inflammation, deformation, and bone erosion from chronic synovial inflammation
Describe 2 syndromes associated with RA	Felty syndrome (RA, Splenomegaly, neutropenia) Sjögren Syndrome (dry eyes, mouth, parotid gland enlargement)
What is the treatment for mild to moderate cases?	NSAIDs to reduce pain and swelling and disease-modifying drugs like methotrexate or hydroxychloroquine
What medications are considered for moderate to severe cases or those unresponsive to first-line therapy?	Short-term steroid use or TNF-inhibitor medications like etanercept (Enbrel) or infliximab (Remicade)

What additional nonmedical treatment may be helpful?

Physical therapy

When is surgery warranted?

When other therapies have failed to reduce chronic pain and improve joint function

CASE 17

A 19-year-old female presents to the ER with her mother complaining of right knee pain with difficulty bending it. She plays soccer and has injured her knee before and twisted it last week during practice, but is concerned because it is not getting better. On exam, the right knee is tender, warm, erythematous, and swollen with minor superficial abrasions.

What's your differential diagnosis?

Gout, pseudogout, septic arthritis, spondyloarthropathy, juvenile RA, foreign body synovitis, RA, rheumatic fever, AIDS, cellulites, Lyme arthritis, neuropathic arthropathy, and sarcoidosis

What risk factor does she have for septic arthritis stated in the history?

Trauma (although minor and unlikely the culprit)

What additional history should you obtain?

Sexual history and IVDA, after excusing mother from the room

Why? What are you considering?

Septic arthritis possibly secondary to gonococcus or staphylococcus

Which joint is commonly involved in both?

Large joints (knee or hip most commonly)

What in the history is inconsistent with gonococcal septic arthritis?

Gonococcal cases often begin as a migratory polyarthralgia that becomes a monoarthritis, tenosynovitis of the wrists, fingers, knees, and ankles, a maculopapular or vesicular dermatitis of the lower extremities or trunk, all of which are absent in her presentation.

What's your diagnostic approach?

Aspirate joint fluid for WBC count, culture, and Gram stain; blood cultures; all orifices cultured for gonorrhea in Thayer–Martin medium

When gonorrhea is under consideration, what additional test should be ordered?

Syphilis serology

What's your most important diagnostic test?

Aspirate synovial fluid from the joint

The synovial fluid is turbid, WBC count of 78,000 cells/ μ L, and PMNs of 92%. What's your diagnosis?

Septic arthritis

What is the diagnostic criteria for septic arthritis?

Turbid fluid, WBC count greater than 50,000 cells/ μ L, PMNs greater than 90%

What's your initial treatment?

1. Hospitalize for intravenous antibiotics
2. Immobilize the joint

What dictates antibiotic selection?

Gram stain and culture results

The culture is positive for staphylococci. What is your treatment?

Intravenous nafcillin or vancomycin followed by an oral antibiotic (dicloxacillin) for a total of 3–6 weeks

What if the Gram stain was positive for gonococci?

Ceftriaxone 1 g daily for 14 days (but at least 7 days after symptoms resolve)

When should surgery be consulted with septic joints?

Septic hip, inadequate needle drainage, no response to therapy after 5–7 days, coexistent osteomyelitis, or prosthetic joint infection, none of which is present in this patient

Chapter 9

Dermatology

SKIN ERUPTIONS

CASE 1

A 14-year-old girl is distraught because her face has broken out with skin lesions (Figures 9–1 and 9–2). On examination you confirm that the skin condition is limited to the face.

Describe the lesions.	Papular lesion with open (whitehead) and closed (blackhead) comedones
What's your most likely diagnosis?	Mild facial acne
What's the differential diagnosis for facial acne?	<i>Staphylococcus aureus</i> folliculitis, pseudofolliculitis barbae, rosacea, and periorbital dermatitis
Why is acne most likely in the differential diagnosis?	Because it is the most common facial skin condition presenting in adolescents (especially at puberty)
How is acne diagnosed?	History and physical exam

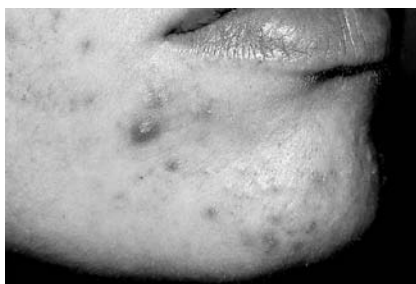

Figure 9–1.

(From Goodheart HP. Goodheart's Photoguide of Common Skin Disorders. 2nd Ed. Philadelphia: Lippincott Williams & Wilkins, 2003.)

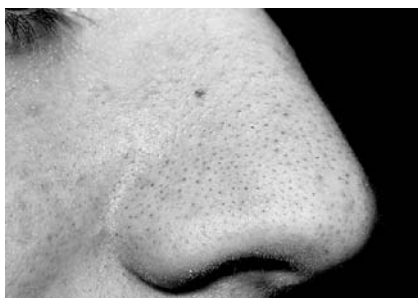

Figure 9-2.

(From Goodheart HP. Goodheart's Photoguide of Common Skin Disorders. 2nd Ed. Philadelphia: Lippincott Williams & Wilkins, 2003.)

What causes it?

A multifactorial process associated with excess sebum production, overgrowth of *Propionibacterium acnes*, androgen excess, inflammation, and abnormal keratin production causing hair follicle plugging

What treatments are available?

Benzoyl peroxide (decreases *P. acnes*), retinoic acid (decreases abnormal keratin production), and topical antibiotics (erythromycin and clindamycin)

CASE 2

A 65-year-old avid golfer living in Florida, with a history of ulcerative colitis and on a small dose of prednisone and Imuran (steroid-sparing agent) presents with well-marginated, reddish papule with rough (feels like sandpaper) yellow-brown scales <1 cm on sun-exposed skin (Figure 9-3).

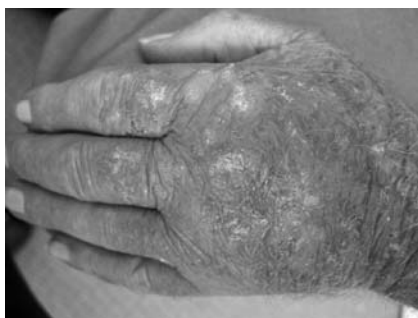

Figure 9-3.

(Image provided by Stedman's Dermatology & Immunology Words, 3rd Edition a LWW WK book.)

What is your differential diagnosis?	Squamous cell carcinoma (SCC), flat warts, superficial basal cell carcinoma (BCC), actinic keratosis (AK)
Which is most likely?	AK
Why?	His frequently sun-exposed skin (golf) and immunocompromised status (on Imuran) are strong risk factors for AK.
Is clinical history and PE enough to make the diagnosis?	No, you must perform a skin biopsy to exclude cancer.
The biopsy confirms AK; what did the pathologist see?	Clonal proliferation of atypical keratinocytes
Why is it important to treat AK?	Untreated patients are at risk for SCC (1:1000 risk).
What is the treatment?	Cryosurgery (preferred), topical 5-fluorouracil cream, or electrocautery

CASE 3

A morbidly obese woman with uncontrolled diabetes and COPD on steroid inhalers presents with itching and burning sensation in the inner thighs and pain with swallowing. On exam you find beefy-red lesions of varying sizes on warm moist areas of the body (inner thigh, axillae, beneath breasts) (Figure 9–4) and white plaques on the tongue (Figure 9–5).

What do you see?	Small peripheral papules and pustules that have become confluent centrally giving a beefy-red appearance
What's your differential diagnosis?	Cutaneous candidiasis, impetigo, eczematous dermatitis, psoriasis, dermatophytosis, pityriasis versicolor
What do you see?	White plaques on the oral mucosa and tongue
What's your differential diagnosis for the oral lesion?	Oral candidiasis, hairy leukoplakia, hyperkeratosis, lichen planus, SCC

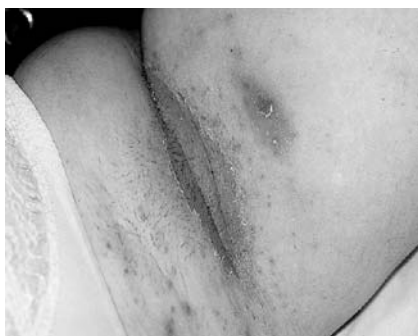

Figure 9-4.

(From Goodheart HP. Goodheart's Photoguide of Common Skin Disorders. 2nd Ed. Philadelphia: Lippincott Williams & Wilkins, 2003.)

What organism could be causing both of these lesions?

Candida albicans

How do you make the diagnosis?

Microscopic visualization of yeast and pseudohyphae using 10% potassium hydroxide

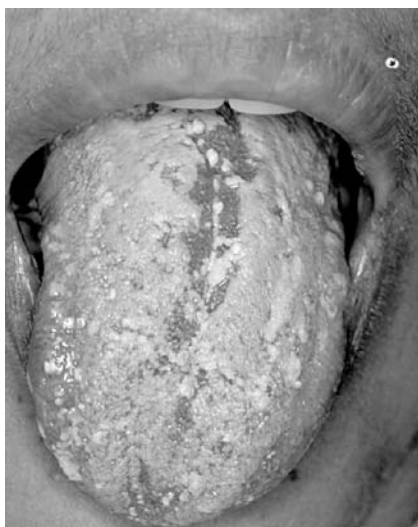

Figure 9-5.

(From Goodheart HP. Goodheart's Photoguide of Common Skin Disorders. 2nd Ed. Philadelphia: Lippincott Williams & Wilkins, 2003.)

What risk factors did this patient have to develop candidiasis?

Diabetic, obesity, and steroid inhaler (probably swallowed and failed to rinse mouth out after use)

What additional risk factor needs to be considered when oral candidiasis presents?

Immunosuppression (HIV/AIDS?)

What is the treatment for Skin lesions?

Nystatin cream and ketoconazole cream

Oral candidiasis?

Nystatin liquid ("swish and swallow")

CASE 4

A 68-year-old woman with uncontrolled diabetes with end-stage manifestations of neuropathy, vascular insufficiency, and retinopathy presents with pain in left ankle after tripping over a vacuum cleaner last week. On exam you find a small ulcer that's tender, warm, and red with a diffuse border (Figure 9–6).

How would you describe this?

Small, shallow ulcer with peripheral erythema, edema, and diffuse border

What most likely caused it?

A polymicrobial bacterial infection secondary to skin trauma (tripped over vacuum cleaner) in a patient with vascular insufficiency secondary to diabetes mellitus

What risk factors does this patient have?

Diabetes, skin trauma, vascular insufficiency

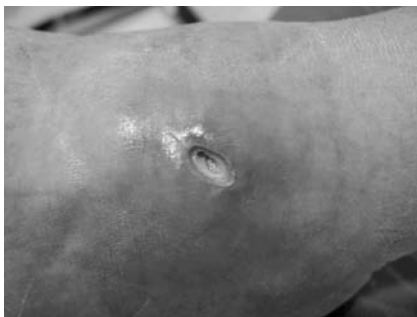

Figure 9–6.

(Image provided by Stedman's Dermatology & Immunology Words, 3rd Edition a LWW WK book.)

What other risk factors exist?	Immunosuppression, lymphatic and venous obstruction
What labs should you order?	CBC, Gram stain and cultures of skin lesions, blood cultures, and possible skin biopsy
What empiric antibiotics should you prescribe after cultures are obtained?	Oxacillin or a cefazolin
What organisms are you targeting?	Group A β -hemolytic streptococci and <i>Staphylococcus aureus</i>
What additional treatment may be required in diabetics?	Anaerobic antibiotics (e.g., metronidazole or clindamycin) because of increased risk of polymicrobial infection

CASE 5

A 48-year-old female comes to the emergency room after wearing latex gloves for the first time with new onset of bilateral hand redness, pruritis, and swelling (Figure 9–7).

What is the most likely cause?	Mild contact dermatitis from a latex allergy
How would a severe case present?	Severe swelling and blistering

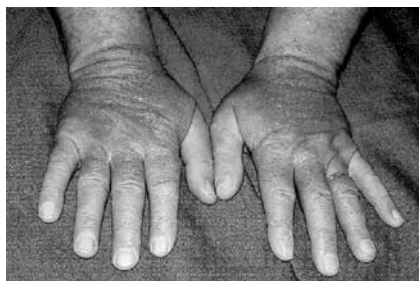

Figure 9–7.

(From Goodheart HP. Goodheart's Photoguide of Common Skin Disorders. 2nd Ed. Philadelphia: Lippincott Williams & Wilkins, 2003.)

What other common causes of contact dermatitis are there?	Soaps, detergents, dyes, solvents, drugs, cosmetics, poison ivy, poison oak, rubber, latex, metals
How is contact dermatitis diagnosed?	History and patch testing
What is the treatment?	Remove and avoid irritant, wash affected area with soap and water, antihistamine (pruritis), and topical corticosteroids
What therapy modification is made in severe cases (especially if face is affected)?	Systemic steroids (prednisone)

CASE 6

A 77-year-old woman with history of HTN, stressed out over her son's wedding, developed low-grade fever, malaise, and a tingling pain in her abdomen beginning around the umbilicus and radiating around to the back.

What's your differential diagnosis?	Herpes zoster, cholecystitis, pleuritis, acute abdomen, diabetic neuropathy, vertebral radicular disease
Your physical exam and lab results are normal. What's your most likely diagnosis?	Herpes zoster ("shingles")
Why?	Prodrome symptoms in a patient with pain in a dermatomal distribution with normal PE and labs
When will the rash appear?	Three days from onset of prodrome symptoms
Describe the rash that will develop.	Erythematous and maculopapular rash that rapidly progresses to grouped vesicles that become pustular and crust over; hemorrhagic crusts may be present (Figure 9–8)
What is the differential diagnosis when a patient presents with a shingles-like rash?	Herpes simplex virus, poison ivy or poison oak, contact dermatitis

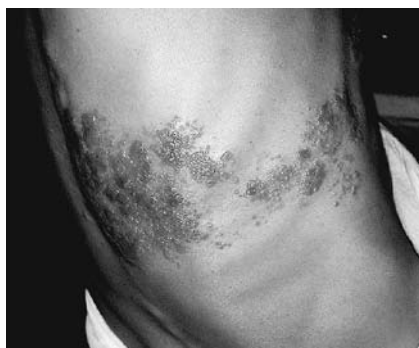

Figure 9-8.

(From Goodheart HP. *Goodheart's Photoguide of Common Skin Disorders*. 2nd Ed. Philadelphia: Lippincott Williams & Wilkins, 2003.)

What was this patient's risk factor?	Elderly
What other risk factors should be considered?	Immunocompromised (unlikely in this patient), spinal surgery, spinal cord radiation
How is the diagnosis often made?	History and presentation
What test would confirm the diagnosis?	Positive Tzanck smear demonstrating multinucleated giant cells
What is the problem with the Tzanck smear?	It is also positive for herpes simplex virus and a false-negative results may occur
What causes shingles?	A latent reaction to the varicella-zoster virus from a prior chicken pox (herpes varicella) infection
Where was the virus hiding?	Sensory nerve ganglia
What is the treatment?	Analgesics, topical calamine lotion, contact isolation precautions while rash is present (it is contagious)
What additional treatment is used in immunocompromised patients?	Acyclovir

CASE 7

A 23-year-old man presents with silvery scales on bright red, well-demarcated plaques most often on the knees, elbows, and scalp (Figure 9–9).

What's your differential diagnosis?

Psoriasis, seborrheic dermatitis, lichen simplex chronicus, candidiasis, psoriasiform drug eruption, tinea corporis, mycosis fungoides

What is your most likely diagnosis?

Psoriasis

Why?

Distribution of rash on knees, elbows, and scalp is classic for psoriasis.

Is family history important?

Yes, because the risk of developing the rash is significantly increased if present in the parents.

What additional finding on physical exam would support psoriasis?

Nail pitting or onycholysis

How is the diagnosis made?

History and presentation

What confirms the diagnosis?

Skin biopsy (although often not required)

What are some of the pathologic findings in psoriasis?

Marked epidermal thickening, increased mitosis of keratinocytes, and inflammatory cells in the dermis

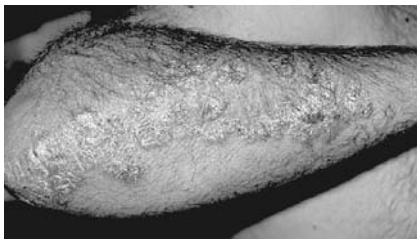

Figure 9–9.

(From Goodheart HP. Goodheart's Photoguide of Common Skin Disorders. 2nd Ed. Philadelphia: Lippincott Williams & Wilkins, 2003.)

What is the basic problem in this disease?

Keratinocytes produce roughly 28 times the normal quantity of epidermal cells.

What treatments are available?

Ultraviolet light, topical corticosteroids, and topical tar

CASE 8

An 8-year-old boy presents with intense itching in the finger web spaces and flexor surfaces of the wrists. On physical exam, the linear tan ridges are identified with small vesicles or papules at the end (Figure 9–10).

What's your differential diagnosis?

Scabies, drug reaction, contact dermatitis

Which is most likely?

Scabies

Why?

Scabies commonly presents with intensely pruritic erythematous papular skin lesions.

What are common sites for scabies infection?

Hands (often flexor surfaces), axillary folds, trunk, buttocks, and genitalia

How long are lesions typically?

2–3 mm long and the width of a hair

How will you make the diagnosis?

Scrape the lesion and look for the scabies mite, eggs, or feces under the microscope

What causes scabies?

Female *Sarcoptes scabiei* ("itch mite") lay eggs in the skin that release larvae that irritate the hair follicles

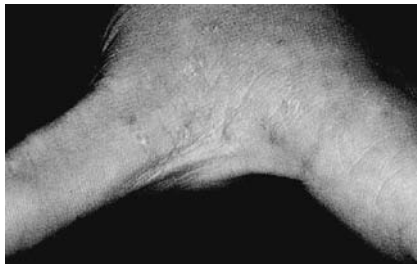

Figure 9–10.

(From Fleisher GR, Ludwig S, Baskin MN. Atlas of Pediatric Emergency Medicine. Philadelphia: Lippincott Williams & Wilkins, 2004.)

What is the treatment?

Permethrin 5% cream (preferred) or lindane 1% cream (neurotoxicity risk). Wash all clothing, sheets, and linens in hot water.

CASE 9

A 19-year-old male with history of drug abuse and multiple sexual partners over the last year presents with a painless ulcer pictured (Figure 9–11).

What is your differential diagnosis?

Primary syphilis, chancroid, lymphogranuloma venereum, granuloma inguinale, herpes, Breschet syndrome, trauma

Your physical exam confirms as pictured above. What is the most likely diagnosis?

Primary syphilis

Why?

A painless, indurated, superficial ulceration in a patient with multiple sexual partners is consistent with syphilis.

What are the risk factors for contracting syphilis?

Sexual contact (most common and most likely in this patient), blood transfusions, and vertical transmission from mother to infant

When was he most likely exposed?

Three weeks ago (typical incubation period)

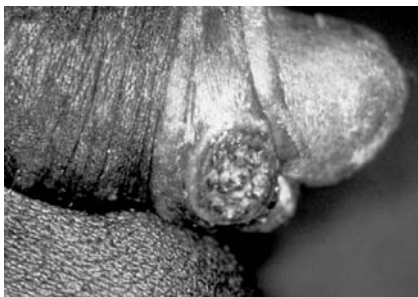

Figure 9–11.

(From Goodheart HP. Goodheart's Photoguide of Common Skin Disorders. 2nd Ed. Philadelphia: Lippincott Williams & Wilkins, 2003.)

What diagnostic tests are available?**Inexpensive serologic**

Venereal disease research laboratory and rapid plasma reagin

Expensive serologic

Fluorescent treponemal antibody absorption test and microhemagglutinin antigen—*Treponema pallidum*

Microscopy

Dark-field microscopy of lesion exudates to reveal the spirochete *Treponema pallidum*

How is diagnosis made?

History, presentation, and positive serologic studies or microscopy

What is the treatment?

Benzathine penicillin G, 2.4 million units in a single dose

If the patient refuses therapy, how long will it take the chancre to heal?

6–8 weeks

What can occur if primary syphilis is not treated?

Secondary or tertiary syphilis

Give examples of possible presentations for both.**Secondary syphilis**

Flu-like illness (malaise, headache, anorexia), generalized nontender lymphadenopathy, and a maculopapular rash [especially on palms and soles as shown (Figure 9–12)]

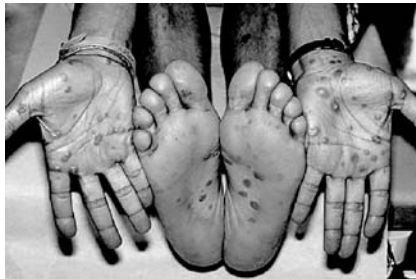

Figure 9–12.

(From Goodheart HP. Goodheart's Photoguide of Common Skin Disorders. 2nd Ed. Philadelphia: Lippincott Williams & Wilkins, 2003.)

Tertiary syphilis

Cutaneous gumma, aortic aneurysms, general paresis, tabes dorsalis, or meningitis

CASE 10

A 55-year-old retired professional caddy for Jack Nicklaus presents with a rash on his nose that has failed therapy with self-prescribed over-the-counter medication (Figure 9–13).

What's your differential diagnosis?

BCC, sebaceous hyperplasia, intradermal nevi, molluscum contagiosum

What is most likely?

BCC

Why?

Classic risk factors of excessive exposure to sunlight (professional caddy), light-skinned person (Irish) with presentation on sun-exposed area is highly suspicious for BCC.

What is the natural history of the BCC lesion?

Begins as a pale, “pearly” papule with dilated blood vessels (telangiectasia) that enlarges peripherally and develops a central depression or ulceration that crusts and bleeds

How do you make the diagnosis?

Biopsy




Figure 9–13.

(From Goodheart HP. Goodheart's Photoguide of Common Skin Disorders. 2nd Ed. Philadelphia: Lippincott Williams & Wilkins, 2003.)

What would be seen by the pathologist?

A nidus of epidermal basal cells extending into the dermis with large basophilic oval nuclei

What's the treatment?

Surgical excision

CASE 11

A 45-year-old woman with history of noninsulin-dependent diabetes and a severe sunburn as a child presents with a dark spot on her skin (Figure 9–14).

What's your differential diagnosis?

Malignant melanoma, dysplastic nevi, vascular skin tumors, BCC

Which is most likely?

Malignant melanoma

Why?

The pigmented lesion has the classic ABCD of melanoma: A, asymmetry; B, border irregularity; C, color variation; D, diameter >6 mm.

Where is this lesion most likely found?

Lower extremity (more common in women)

What if the patient had been a man?

Trunk

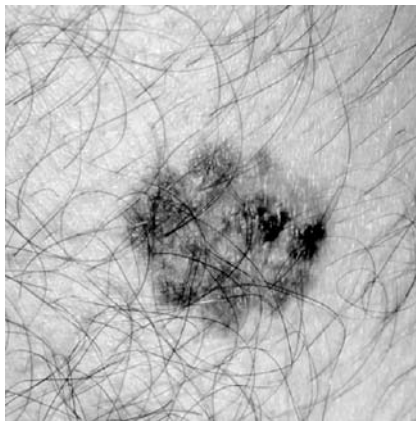


Figure 9–14.

(From Goodheart HP. Goodheart's Photoguide of Common Skin Disorders. 2nd Ed. Philadelphia: Lippincott Williams & Wilkins, 2003.)

Can melanoma present elsewhere?	Yes
What put this patient at risk?	Sun exposure (severe burn in childhood)
What other risk factors exist for melanoma?	Dysplastic nevi, prior melanoma, family history (first-degree relative) and xeroderma pigmentosum
How is it diagnosed?	Excisional biopsy
What will the pathology report most likely find?	Superficial spreading melanocytes, which is the most common form (70%) of melanoma
What is the treatment?	Wide excision

CASE 12

A 62-year-old fair-skinned male golf course greens-keeper with history of diabetes and AK presents with a new skin lesion (Figure 9–15).

What is your differential diagnosis?	SCC, BCC, AK, malignant melanoma, keratoacanthoma
You are informed that it began as a crusted red papule that became nodular (and occasionally ulcerates). What is your most likely diagnosis?	SCC

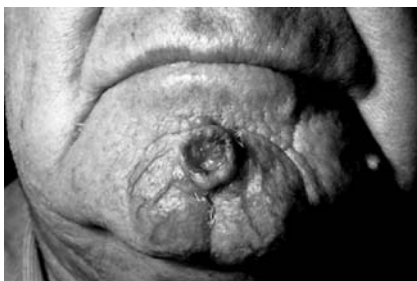

Figure 9–15.

(From Weber J, Kelley J. *Health Assessment in Nursing*. 2nd Ed. Philadelphia: Lippincott Williams & Wilkins, 2003.)

What are this patient's risk factors for SCC?

Older age (up to 10 times risk in elderly), male (2–3 times risk), sun exposure (greens-keeper), fair skin, AK

How will you confirm your diagnosis of SCC?

Skin biopsy

What will the pathology report say?

Atypical epithelial cells arising from the epidermis and extending into the dermis consistent with SCC

What specific epithelial cell does SCC arise from?

Keratinocytes

What is the treatment?

Surgical excision

CASE 13

A 16-year-old boy presents with a painless, firm, well-circumscribed nodule with cornified epithelium (Figure 9–16).

What is your differential diagnosis?

Viral wart, scar tissue, molluscum contagiosum, condyloma lata, seborrheic keratosis

Which diagnosis do you suspect?

Viral warts (verruca vulgaris)

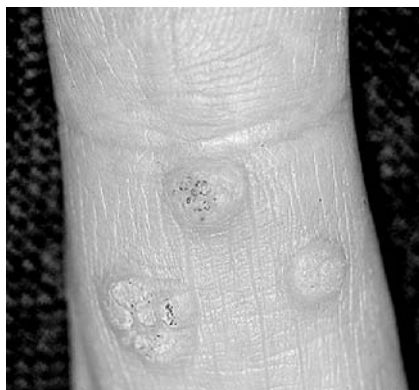

Figure 9–16.

(From Goodheart HP. Goodheart's Photoguide of Common Skin Disorders. 2nd Ed. Philadelphia: Lippincott Williams & Wilkins, 2003.)

Where do viral warts commonly appear?	Fingers, knees, elbows, and feet
What size are they?	Less than 1 cm
What are the risk factors to ask about?	Local irritation, trauma, immunosuppressive diseases or drug use, atopic dermatitis
How is the diagnosis often made?	Clinically
How would you confirm it?	Biopsy
What would the pathology report say?	Human papilloma virus (HPV) found in the nuclei and nucleoli of the epidermal stratum granulosum and keratin layers
What is the treatment?	Topical salicylic acid or cryotherapy

CASE 14

An 18-year-old African-American male presents after having sutures removed 3 weeks ago for a laceration during a motor vehicle accident with an enlarging well-demarcated scar (Figure 9–17).

What's your differential diagnosis?	Keloid, hypertrophic scar, dermatofibroma, BCC
--	--

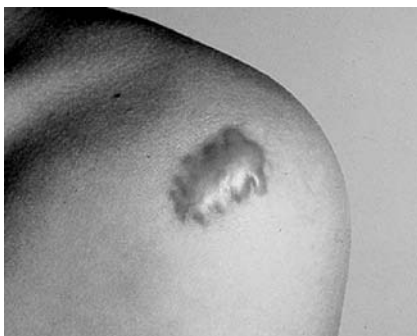

Figure 9–17.

(From Willis MC. Medical Terminology: A Programmed Learning Approach to the Language of Health Care. Baltimore: Lippincott Williams & Wilkins, 2002.)

Which is most likely?	Keloid
Why?	Patient has classic risk factors and presentation for keloid formation
What are his risk factors?	Dark skin pigment (African American), adolescence, and recent skin trauma in same location
What are other risk factors for keloid formation?	Pregnancy, inflammation, and family history
How is the diagnosis often made?	Clinically
How could it be confirmed?	Biopsy
What would the pathology report show?	Whorls of hyalinized collagen bundles with thinning of the dermis and decreased elastic tissue
What causes it?	Irregular organization of fibroblasts following skin injury
What is the treatment?	Local steroid injections

Chapter 10

Obstetrics and Gynecology

UTERUS

CASE 1

A 35-year-old obese African American female presents with menorrhagia for the last 4 months and a sense of pressure in the pelvis. On physical examination, you appreciate an enlarged, mobile uterus with an irregular contour on bimanual examination.

What's your broad differential diagnosis for menorrhagia in this patient?

Coagulopathy, structural lesion such as uterine or cervical cancer, fibroids, endometriosis

Which is suggested by the physical exam findings?

Fibroids (a.k.a. leiomyoma)

How do fibroids present?

Often asymptomatic, but may present with abnormal uterine bleeding, a pelvic mass, and sensations of pressure in the pelvis

What is it?

Benign hormonally responsive uterine tumor also known as a myoma or fibroma that is composed of smooth muscle tissue which usually regresses after menopause

What are this patient's risk factors?

African American and obesity

What other risk factors have been reported?

Premenopausal, nonsmokers

Describe findings on the following tests that support the diagnosis of fibroids:

Physical exam

Enlarged, mobile uterus with an irregular contour on bimanual examination

Abdominal x-ray	Discrete, calcified round masses
Hysterosalpingography	Distinct areas lacking contrast
Ultrasound	“Snowstorm” image
What additional procedure is required if the diagnosis is uncertain?	Biopsy of suspicious mass
What is the treatment strategy in	
Asymptomatic patients?	None as the fibroids shrink after menopause
Symptomatic patients?	Gonadotropin-releasing hormone agonists result in decreased LH and FSH with resultant menopause-like state
What are the indications for surgery?	A rapidly growing myoma in a menopausal female usually warrants hysterectomy or myomectomy.

CASE 2

A 31-year-old female G0P0 presents to your clinic with her husband after being unable to get pregnant after trying for 6 months. She also complains of abnormal menstrual bleeding and worsening pain with menses.

What is the differential diagnosis?	Pelvic inflammatory disease (PID), ovarian cancer, and leiomyomas
Which is most likely?	Endometriosis
What were the clues?	Progressive dysmenorrhea, dyspareunia, abnormal bleeding, cyclical pelvic pain, and infertility are suggestive of endometriosis.
What is endometriosis?	Ectopic growth of uterine glands and stroma
What are the most common locations?	Ovary and pelvic peritoneum

Name the main risk factor.	Family history
What may be appreciated on physical exam?	Uterosacral nodularity on rectovaginal examination or a fixed retroverted uterus
What labs should be included in the workup?	CBC and ESR (may suggest an acute or chronic inflammatory process), urinalysis (UA) and urine culture to rule out urologic source (e.g., cystitis, stones), and a pregnancy test and tests for sexually transmitted diseases (gonorrhea, chlamydia), when appropriate
What imaging is useful?	Abdominal ultrasound
What's the definitive diagnostic test?	Laparoscopy
What's the medical treatment?	Danazol, GnRH analogs, and estrogen–progesterone oral contraceptives
What alternative therapy is available if medical therapy fails?	Laparoscopic excision
What definitive therapy exists?	Total abdominal hysterectomy and bilateral salpingo-oophorectomy (TAHBSO)

CASE 3

A 55-year-old postmenopausal woman presents to your clinic complaining of vaginal bleeding for the last 6 weeks.

What are you most concerned about?	Endometrial cancer
Why?	Abnormal vaginal bleeding (especially in postmenopausal women) is the most common presentation.
What causes it?	Chronic exposure to unopposed estrogen
What are the risk factors?	Exogenous estrogen use, obesity, nulliparity, early menarche, late menopause, anovulatory cycles, diabetes mellitus, and polycystic ovarian syndrome

What's in your differential diagnosis?	Endometrial atrophy, polyp, hyperplasia, hormonal effect, and cervical cancer
What tests are included in the workup?	Speculum exam, pap smear, and endometrial biopsy
How is endometrial cancer diagnosed?	Endometrial biopsy
What is the most common histologic type?	Adenocarcinoma
What radiologic test is useful to screen for metastasis?	CXR
What is the treatment for stage 1 cancer (confined to endometrium)?	TAHBSO
What additional therapy is available for more advanced disease?	Radiation, chemotherapy, and hormone therapy (high-dose progestins and antiestrogens)

OVARY

CASE 4

A 44-year-old G1P1 female with no known cardiac or liver disease presents to your clinic complaining of vague abdominal discomfort, increased abdominal girth, and weight loss. On exam, you appreciate abdominal distention and a fluid wave suggestive of underlying ascites.

What's the most likely diagnosis?	Ovarian cancer
How does it present?	Asymptomatic early on, but later vague gastrointestinal symptoms, abdominal discomfort, fullness, early satiety, ascites, pain, pelvic mass, and weight loss are common
What are her risk factors?	Middle-age and low parity
What other risk factors should be investigated?	Family history, delayed childbearing (over 30), and infertility

What's in the differential diagnosis of ovarian cancer?	Endometriomas, ovarian cysts, tuboovarian abscess, nongynecologic causes of a pelvic mass (e.g., colon cancer), ectopic pregnancy
What must not be overlooked on the physical exam?	Pelvic examination
What physical exam findings are suggestive of ovarian cancer?	Fixed, irregular pelvic mass with upper abdominal mass or ascites
What 2 tests must be included in the workup?	Abdominal or transvaginal ultrasound and CA-125
Why should the CA-125 be ordered?	It is often elevated in ovarian cancer
Is this tumor marker useful for screening?	No, it is most useful to evaluate response to treatment, but is still commonly ordered on initial workup.
How is the diagnosis confirmed?	Laparotomy
What's the treatment for Young patients with low-grade disease?	Unilateral oophorectomy
Advanced cases?	Radical surgery (TAHBSO, omentectomy, debulking), radiation, and chemotherapy

CERVIX

CASE 5

A 31-year-old female previously treated for human papilloma virus (HPV) presents to your clinic after having vaginal bleeding after intercourse.

What's the most likely diagnosis?	Cervical cancer
How does it present?	Often asymptomatic, but postcoital bleeding, abnormal vaginal bleeding, pelvic pain, and urinary tract infections may occur

What known risk factor does she have?	HPV infection
What HPV types can cause it?	HPV types 16, 18, and 31
What other risk factors should be considered?	Cervical dysplasia, multiple sexual partners, having intercourse at an early age, and smoking
What screening test should be performed?	Pap smear
How is the diagnosis confirmed?	Biopsy
What is the most common histologic type?	Squamous cell carcinoma (about 90%)
What's the treatment?	Hysterectomy and pelvic node dissection
What additional therapy is useful in advanced disease?	Radiation and chemotherapy

MENSTRUAL DISORDERS

CASE 6

A 35-year-old female is referred to you after an extensive workup for irregular bleeding with anovulation. Her β -hCG was negative, abdominal and transvaginal ultrasound revealed normal anatomy, and serology was negative for a coagulopathy. Her pap smear and pelvic exam were unremarkable.

What has been ruled out?	Pregnancy, structural pelvic pathology (e.g., fibroids, polyps, etc.), cervical cancer, and coagulopathy
What should be considered now?	Dysfunctional uterine bleeding
What is it?	Abnormal uterine bleeding, often with anovulation, in the absence of other anatomic lesions

What causes it?	Dysfunction of the hypothalamic-pituitary-gonadal axis, resulting in continuous noncyclic estrogen stimulation of the endometrium causing it to outgrow its blood supply and slough off at irregular times and unpredictable amounts
How does it often present?	Irregular, often heavy uterine bleeding with anovulation
What basic tests can be ordered to determine whether ovulation is occurring?	A daily basal body temperature graph and day 23–35 serum progesterone level
What is the gold standard test to diagnose anovulation and dysfunctional uterine bleeding?	Endometrial biopsy
What is the treatment?	Progestational agent (e.g., medroxyprogesterone) for a minimum of 10 days during the luteal phase for several cycles
What is an alternative treatment?	Oral contraceptives 4 times a day for 1 week, then begin normal regimen for at least 3 months

BREAST

CASE 7

A 38-year-old female presents with a palpable breast lump that she detected while showering. She denies any nipple discharge, bone pain, or abnormality in the breast's appearance.

What are you most concerned about?	Breast cancer
How does it commonly present?	As a palpable painless mass or identified in an abnormal mammogram without a palpable mass

What risk factors should be questioned?	Family history (first-degree relatives), early menarche, late menopause, nullparity and first pregnancy after age 30, and previous breast cancer or biopsies with atypical changes
What physical exam findings suggest breast cancer?	Color change, dimpling, nipple retraction, axillary mass, and bone pain (rare)
What test should be ordered first?	Mammogram
What findings on mammogram suggest breast cancer?	Clustered microcalcifications and stellate densities
How is the diagnosis confirmed?	Biopsy (excisional, incisional, or fine needle)
What's the treatment for Stage I or II?	Either modified radical mastectomy or lumpectomy followed by radiation; axillary lymph node sampling
Locally advanced (stage III)?	Combination chemotherapy and radiation therapy prior to mastectomy
Metastatic (stage IV) disease?	Combinations of chemotherapy, hormone therapy, and radiation therapy

COMPLICATED PREGNANCY

CASE 8

A 25-year-old female in third trimester of pregnancy develops severe abdominal pain and vaginal bleeding after being struck in the abdomen by her abusive husband.

What complication should you be concerned about?	Abruptio placenta
What is it?	Separation of a normally implanted placenta from the uterine wall
How does it classically present?	Third trimester bleeding with severe abdominal pain

What principal risk factor does she have?	Trauma
What other risk factors should be investigated?	Hypertension, cigarettes, cocaine, and previous abruption
What physical exam findings support the diagnosis?	Firm tender uterus with or without signs of fetal distress
What labs should be ordered?	Type and screen, CBC, coagulation studies, fibrinogen level, and cocaine drug screen
What imaging test should be ordered?	Abdominal ultrasound
How is the diagnosis made?	Clinical history and presentation
How is the diagnosis confirmed?	Examination of placenta after delivery
What is the treatment if mother and fetus are stable?	Bed rest with a fetal monitor
What is the treatment for uncontrollable hemorrhaging or maternal or fetal compromise?	Immediate cesarean section

CASE 9

A 24-year-old female with history of PID presents with acute onset of right lower quadrant abdominal pain and vaginal spotting. Prior to the abrupt onset of pain, she had some crampy abdominal pain, nausea, and rare spotting. Her menses is now 3 weeks late.

What do you suspect?	Ectopic pregnancy (fertilized ovum implants outside the uterus) with possible rupture
Why?	Amenorrhea, nausea, spotting, and crampy lower abdominal pain are characteristic of an ectopic pregnancy.

What symptoms are worrisome for rupture?	Rapid onset of severe sharp abdominal or pelvic pain, guarding, rigidity, rebound tenderness, and vaginal bleeding; hypotension and shock may be present.
What risk factor does she have?	PID
What other risk factors should be questioned?	Intrauterine device (IUD), tubal surgery, and prior ectopic pregnancy
What physical exam findings support the diagnosis?	Tender abdomen and adenexae; adnexal mass may be appreciated
What lab tests should be ordered?	CBC, blood type, antibody screen and crossmatch, quantitative β -hCG level
What lab result supports the diagnosis?	A β -hCG level that fails to double in 48 hours and lack of gestational sac in utero
If pregnancy test is positive, what radiographic study should be ordered next?	Transvaginal or transabdominal ultrasound (may reveal empty uterine cavity and an adnexal mass)
How is the diagnosis confirmed?	Laparoscopy
What medical treatment should all Rh-negative women receive?	RhoGAM
What are the treatment options for unruptured ectopic pregnancies if detected early?	Methotrexate, laparoscopic tubal surgery, or salpingectomy
What is the treatment for a ruptured ectopic pregnancy?	Laparoscopic salpingectomy or salpingostomy after patient is stabilized

CASE 10

A 26-year-old female with 3 prior abortions now in her third trimester of an uncomplicated pregnancy presents with intermittent painless bright red vaginal bleeding. Over the last 4 days it has occurred twice and only soaked 3 pads. She denies any abdominal pain, trauma, or drug use. She is still able to feel the baby kick as before.

What should you be concerned about?

Placenta previa

Why?

Sudden onset of painless bright red third-trimester vaginal bleeding; often resolves spontaneously and reoccurs days later

Where does the placenta lie in placenta previa?

Over or near the cervical os

What is her known risk factor?

Prior abortions

What are the other risk factors?

Multiparity, advanced maternal age, and previous cesarean section

Should a vaginal exam be conducted during the physical exam?

No, it may cause increased bleeding

What basic labs should be ordered?

CBC, blood type, blood screen, and coagulation studies

How is it diagnosed?

Transabdominal or transvaginal ultrasound

What is the treatment for placenta previa with minor bleeding?

Bed rest, tocolytics if necessary, and delivery by cesarean section

What is the treatment for placenta previa with severe bleeding?

Stabilize mother and immediate cesarean section

CASE 11

A 26-year-old G3P3 female with history of hypertension presents to the ER with progressive onset of headache, blurred vision, nausea, and vomiting. Her current blood pressure is 170/90 mm Hg.

What diagnosis do you suspect?	Preeclampsia (pregnancy-induced hypertension)
What's its classic presentation?	Headache, blurred vision, scotomata, edema, nausea, and vomiting
What are the risk factors?	Multiple gestation and preexisting hypertension
What other risk factors are there?	Molar pregnancy and age
What findings may be apparent on physical exam?	Hypertension, generalized nondependent edema, and oliguria
What will the UA reveal?	Proteinuria
How is hypertension defined in pregnancy?	A blood pressure >140/90 or a 30 mm Hg increase in systolic or 15 mm Hg increase in diastolic during pregnancy
How is mild preeclampsia diagnosed?	Hypertension with nondependent edema or 2+ dipstick proteinuria
How is severe preeclampsia diagnosed?	Blood pressure of 160/110 mm Hg, oliguria, 3+ dipstick proteinuria, or evidence of end-organ damage
How is eclampsia diagnosed?	Seizure activity in a preeclamptic patient
What is the treatment goal?	Avoid complications of end organ damage and eclampsia
How is mild preeclampsia treated?	Bed rest with decreased water intake; induce delivery if fetus is full term, and use IV magnesium for seizure prophylaxis

How are severe preeclampsia and eclampsia treated?

Deliver baby after mother has been stabilized, may use antihypertensive medications, such as hydralazine, use magnesium for seizure prophylaxis, and add IV diazepam if seizures develop

MISCELLANEOUS CONDITIONS

CASE 12

A 22-year-old female in her 17th week of pregnancy presents to your office concerned about vaginal spotting and uterine cramping.

What are you concerned about?

Spontaneous abortion (SAB) (spontaneous loss of a pregnancy before 20-weeks gestation)

What is the main cause in first-trimester SAB?

Fetal chromosomal abnormalities

What are some common causes of second trimester SAB?

Maternal infections, cervical incompetence, uterine anomalies, endocrine abnormalities, systemic disease, and environmental factors (e.g., smoking, alcohol, and cocaine)

What should be included in the workup to assess maternal and fetal well being?

Maternal vital signs and fetal heart rate

What lab tests should be ordered?

β -hCG, CBC, type and screen, and PTT

What radiographic study is helpful to determine viable pregnancies?

Transvaginal or transabdominal ultrasound

Describe the exam findings in the different types of SABs:

Threatened abortion

Cervical os is closed

Inevitable abortion

Cervix is dilated or membranes have ruptured

Incomplete abortion	Dilated cervix with some of the products of conception passing through the cervix
Complete abortion	All products of conception have passed through the cervix
Missed abortion	Retention of failed intrauterine pregnancy for at least 4 weeks
How is an abortion diagnosed?	History, presentation, speculum exam findings, and ultrasound if needed
What is the treatment for the different types of abortions?	
Threatened	Maternal bed rest and pelvic rest for stable mothers with a viable fetus
Inevitable	Either wait for the abortion to complete or perform a dilation and curettage (D&C)
Incomplete	D&C
Missed	D&C (preferred) or await SAB (risk of hemorrhage)

GASTROENTEROLOGY

CASE 1

A previously healthy 20-day-old infant is brought to your office by his exhausted parents complaining that their child has been crying most days for the last week with his legs drawn up toward his belly.

What differential diagnosis are you considering?

Bone fracture, physical abuse, incarcerated hernia, milk or formula intolerance, corneal abrasion, and colic

You've completed a thorough physical exam and other than the child crying excessively and the abdomen being slightly distended, he appears to be healthy. What is your most likely diagnosis?

Colic

Why?

Healthy child with normal physical exam crying excessively for more than 3 hours/day for 3 days a week during first 3 months of life is diagnostic of colic.

Why does this not fit formula or milk intolerance?

Lack of diarrhea or vomiting

What causes colic?

Unknown

What treatment should you begin?

Carry and cuddle baby when crying, supportive counseling (this is nothing you have done to the baby), and parental reassurance (it's going to get better)

Are there any medications to prescribe?

No

When do most cases of colic resolve? By 3 months

CASE 2

A 2-week-old infant presents with progressively worse projectile nonbilious vomiting after meals for the last 3 days.

What's your differential diagnosis? Gastroenteritis, pyloric stenosis, UTI, formula intolerance, drug withdrawal, gastric or duodenal web

On physical exam you find a firm, 1–2 cm “olive” 2 or 3 cm above the umbilicus with a visible peristaltic wave over the epigastrium. What just came to the top of your DDx? Pyloric stenosis

What does the olive represent? Hypertrophied pylorus

Before ordering your diagnostic test, you need to order what lab test? Chem 8 to check for hypochloremic hypokalemic metabolic alkalosis secondary to excess gastric fluid loss

Your chemistries come back within normal limits. What diagnostic test do you want to order? Abdominal ultrasound (90–100% sensitive, best diagnostic test)

The ultrasound comes back with the result of poor study owing to patient movement. What is the next test you order? Upper GI study

Report comes back stating findings are consistent with pyloric stenosis. What causes it? Hypertrophy of the circular muscle of the pylorus causing gastric outlet obstruction

At what age does it usually present? 1–10 weeks

What is the incidence?	3 per 100 live births
Is there a gender bias?	Yes. Males are affected four times as often as females.
Is there a racial bias?	Yes. Whites are the most frequently affected, followed by African Americans. Asians and Indians are rarely affected.
Does birth order play a role?	Yes. First-born children are the most frequently affected.
What is the treatment of choice?	Pylorotomy
Is this curative?	Yes

CASE 3

A 6-month-old boy presents with recurrent and severe paroxysmal colicky abdominal pain, emesis, loud cries, and bloody mucus stools. The emesis was initially clear, but has become bile stained prior to presentation.

What is your differential diagnosis?	Adhesions causing SBO, intussusception, gastroenteritis, appendicitis
You examine the child and find an oblong sausage-shaped palpable mass in the RUQ or mid-epigastric area and currant jelly-appearing stool. What do you think the diagnosis is now?	Intussusception
Why?	Triad of colicky abdominal pain, emesis, currant jelly stools, and palpable RUQ mass in age-appropriate child (usually 3 months to 6 years, 66% before 1st year) and this is the most common cause of intestinal obstruction in this age group
What basic labs and tests should you order?	Chem 8, CBC, UA, stool guaiac

What imaging test will suggest the diagnosis?	Plain x-ray showing a soft tissue mass that displaces the gas-filled bowel with or without evidence of bowel obstruction
Does a normal x-ray rule out intussusception?	No
What test will you order to make the diagnosis?	An air or barium enema done under fluoroscopic guidance
What do you expect it to show?	Filling defect at the distal end of the intussusception, giving a “coiled spring” appearance
What causes it?	A telescoping of part of the intestine into a segment distal to itself
What is the primary site of intussusception?	95% of cases are ileocolic, beginning just proximal to the cecum.
What gives the coiled spring appearance on barium enema?	It occurs when contrast fills the space between the intussusceptum and the intussusciptions.
What causes this?	Usually, no cause is found. There is an association with adenoviruses and gastroenteritis. Other causes include Meckel diverticulum, intestinal polyps, and Henoch-Schönlein purpura.
How does a lead point such as a Meckel diverticulum cause intussusception?	It has been suggested that the lead point, such as a Meckel diverticulum or swollen Peyer patches from infection, stimulates the ileum to contract in an attempt to extrude the mass and thus causes an intussusception.
What causes the abdominal pain?	Peristalsis pulling on the intussusceptum. As peristalsis is an on-and-off phenomenon, so the pain initially comes and goes, and children are fine in between spells. When they have the pain, younger children will usually pull up their knees and strain.

Why does bleeding occur?	The intestine pulls the mesentery along with itself, constricting it. This leads to venous pooling and edema of the mucosa, followed by bleeding.
How is this treated?	Barium enema (the diagnostic test); the pressure of the enema is usually sufficient to reduce the intussusception.
What if this fails?	Surgery

CASE 4

A concerned mother calls you because her 3-year-old child has been acting strangely since visiting his grandmother this morning who has multiple medical conditions requiring numerous medications. The grandma complained to the mother earlier that the boy had spilled all her medications in her pill box on the floor. For the last 15 minutes, the child has begun to salivate, has watery eyes, urinated on himself, and has thrown up in the back seat of the car.

What are you most concerned about?	Poisoning
Who's at greatest risk of poisoning?	Children <5 years old
When should a diagnosis of poisoning be considered?	In a patient with a known or suspected exposure to a toxin, or in an individual with the sudden onset of mental status changes, respiratory aberrations, abnormal behavior, shock, autonomic dysfunction, vomiting and/or diarrhea, dysrhythmia, or metabolic derangements not otherwise explained
What does the mother need to do first?	Take the child to the ER.
What four types of poisoning syndromes should you be considering in this child?	Cholinergic, anticholinergic, sympathomimetic, sympatholytic

How does cholinergic syndrome present, and what drugs cause this?

This comes from stimulation of muscarinic and nicotinic receptors. The mnemonic **SLUDGE** is helpful here: **S**alivation, **L**acrimation, **U**rination, **D**efecation, **G**I cramps, and **E**mesis. Pupils are constricted. Drugs that cause this include organophosphates, physostigmine, and nicotine.

How does anticholinergic syndrome present, and what drugs cause this?

“Mad as a hatter, hot as a hare, dry as a bone, red as a beet.” Tachycardia and hypertension are also seen, and pupils are dilated. Drugs to consider are atropine, scopolamine, cyclic antidepressants, jimsonweed, antihistamines, and *Amanita muscaria* poisoning.

How does sympathomimetic syndrome present, and what drugs cause this?

Heart rate and blood pressure are increased, and the temperature is elevated. The patient is diaphoretic, pupils are dilated, the mouth is dry, and he is frequently agitated. Drugs include amphetamines, cocaine, phencyclidine, pseudoephedrine, caffeine, methylphenidate, and theophylline.

How does sympatholytic syndrome present, and what drugs cause this?

As expected, this is the opposite of sympathomimetic. Affected patients have bradycardia, hypotension, and hypothermia. The skin is dry, pupils constricted, and bowel sounds may be absent. There may be signs of central nervous system depression. Think of opioids, alcohol, heroin, barbiturates, benzodiazapines, and clonidine.

Which type does this child most likely have?

Cholinergic

What labs should you order?

CMP, CBC, urine, and serum drug screen

How do urine and serum toxicology screens differ?

Urine screens are designed primarily for drugs of abuse, while serum tests are for over-the-counter products and alcohol.

What therapy should this child receive?	Ipecac syrup to induce vomiting and activated charcoal to help absorb toxin
When should emesis not be induced?	Coma, convulsions, caustics, cyclic anti-depressants, and hydrocarbons (the 5 Cs)
What additional measure may be used?	Gastric lavage
What are the limitations of gastric lavage?	The ingestion must be recent (within 1 to 2 hours) and the patient must be able to protect his airway (i.e., no depression of sensorium or potential of seizure).
When should activated charcoal not be used?	If there is a possibility of endoscopy, drugs for which there is an oral antidote, hydrocarbons, and those that do not adsorb to it, including heavy metals, lithium, iron, acids, alkalis, alcohols, and cyanide
What additional measures should be taken at grandma's house?	Keep medications and other toxic substances out of reach by using childproof cabinets, drawers, and medicine bottles.

HEAD AND NECK INFECTIONS

CASE 5

A 24-month-old toddler is brought to the walk-in clinic with persistent crying and inability to be calmed for last 18 hours. The mother says that since yesterday the child has been pulling on his right ear and crying. She has taken his temperature and it was 37.7°C. Tylenol has not worked and she wants to know what can be done next. She later informs you that last week he had some clear nasal discharge, but it has significantly decreased over the last few days.

What should you suspect?	Inner ear infection (acute otitis media [AOM])
Why?	Child <24 months old, presenting with irritability and pulling on ear is a classic presentation for AOM.

Why does the child pull on his ear?	AOM causes pain and a sense of fullness in the ear secondary to fluid in the middle ear.
What additional signs and symptoms may occur in AOM?	Hearing loss, vertigo, tinnitus, fever, purulent otorrhea
What is a common risk factor for AOM?	Preceding viral upper respiratory infection
What are the 4 most common viruses associated with AOM?	Respiratory syncytial virus (RSV), rhinoviruses, influenza viruses, and adenoviruses
What are the 3 most common bacterial causes of AOM?	<i>Streptococcus pneumoniae</i> , <i>Haemophilus influenzae</i> , <i>Moraxella catarrhalis</i>
What clinical findings on otoscopy of AOM do you expect to find?	Injection, erythema, loss of luster of tympanic membrane, loss of translucency of some or all of membrane, bulging of membrane or loss of landmarks
Is erythema diagnostic of AOM?	No, erythema may be caused by inflammation of mucosa throughout the upper respiratory tract.
How is the diagnosis made?	Pneumatic otoscopy, with or without tympanometry
What is the treatment strategy for AOM?	Oral antibiotics for 10 days
What are first-line treatment options?	Amoxicillin, or trimethoprim-sulfamethoxazole (TMP-SMZ) for penicillin-allergic persons
What are the typical doses of amoxicillin and TMP-SMZ used?	Amoxicillin 250–500 mg by mouth 3 times a day, or TMP-SMZ 1 tablet by mouth twice a day
What medication can be used to treat pain and fever?	Children's Tylenol

CASE 6

A 12-year-old boy presents to the clinic with a 2-week history of frontal headache accompanied by nasal drainage. The child said at first the drainage was clear and accompanied by a cough, but has now turned a dark yellow color with brown streaks. He has been taking antihistamines for his allergies and over-the-counter Tylenol, but it has not helped. His mother wants to know if it's time for an antibiotic.

What is this child's presentation consistent with?	Acute sinusitis
What is acute sinusitis?	Inflammation of the mucosal lining of the paranasal sinuses, lasting up to 3 weeks.
Where does the infection most likely reside in this child?	Frontal sinus
Why?	He complains of a frontal headache.
What other sinuses can be involved in acute sinusitis?	Maxillary, ethmoid, sphenoid
What type of acute sinusitis did this child have initially?	Acute viral sinusitis
How does viral sinusitis most commonly present?	Nasal drainage and cough
What other signs and symptoms commonly occur with it?	Fever and sore throat
What are the common agents in viral sinusitis?	Rhinovirus, coronavirus, influenza, parainfluenza, adenovirus, enterovirus, and RSV
What is the most likely explanation for the recent change in nasal discharge?	Superimposed acute bacterial rhinosinusitis (ABRS)
Define it.	Sinusitis with bacterial superinfection

What is the major risk factor for developing ABRS?	Viral sinusitis for more than 7–10 days (which he had)
What are the two most common bacterial agents in ABRS?	<i>Streptococcus pneumoniae</i> and nontypable <i>Hemophilus influenzae</i>
What other pathogens may cause ABRS?	<i>Moraxella catarrhalis</i> , other streptococcal species, anaerobic bacteria, and <i>Staphylococcus aureus</i>
How does ABRS most commonly present?	Purulent nasal drainage and sinus pressure or tenderness
What other signs and symptoms may occur?	Fever is present in about one-half of cases. Sinus pain may be worse when bending or supine.
What is the gold standard for the diagnosis of ABRS?	Sinus puncture with culture of the aspirated fluid
How is a clinical diagnosis of ABRS made?	Vancomycin-resistant streptococci (VRS) present >10 days (or worsens after 5–7 days) and is accompanied by some of the following symptoms: nasal drainage, nasal congestion, facial pain/pressure (particularly with unilateral predominance), postnasal drainage, fever, cough, fatigue, hyposmia/anosmia, maxillary dental pain, ear pressure/fullness.
What is the treatment strategy for ABRS?	Oral antibiotics for at least 10 days
What are first-line treatment options for mild to moderate disease in a β-lactam nonallergic adult with no recent antibiotic exposure?	“High-dose” amoxicillin, amoxicillin/clavulanic acid, cefpodoxime, or cefuroxime axetil
What first-line antibiotic options are recommended for a β-lactam allergic patient with mild to moderate disease?	TMP-SMZ, doxycycline, or a macrolide (e.g., clarithromycin, azithromycin)

CASE 7

A 15-year-old boy complains of rapid onset of severe sore throat, fever of 38°C, and mild headache. The physical exam provided by the school nurse notes anterior cervical adenopathy and red posterior pharynx with white exudates.

What's the most likely diagnosis?	Exudative pharyngitis
Define it.	Inflammation of the pharynx, presenting with sore throat and tonsillopharyngeal exudates
What's the most common cause of pharyngitis?	Viruses
Which viruses can cause exudative pharyngitis?	Epstein-Barr virus (EBV) (infectious mononucleosis), herpes simplex virus, and adenovirus
What additional clinical findings would suggest EBV infection?	Fatigue, malaise, and prominent cervical adenopathy (particularly posterior cervical). Exudate is seen in one-half of cases and palatal petechiae are seen in 25%. Splenomegaly may also occur.
What office-based laboratory test can help establish the diagnosis of infectious mononucleosis as a result of EBV?	The "spot" test for heterophile antibodies (the monospot test)
Name three bacterial causes of pharyngitis.	<i>Streptococcus pyogenes</i> , <i>Neisseria gonorrhoeae</i> , <i>Corynebacterium diphtheriae</i>
Why should group A β-hemolytic streptococcus (GABHS) be treated?	Prevention of suppurative complications and prevention of rheumatic fever
What are the suppurative complications of GABHS pharyngitis?	Peritonsillar or retropharyngeal abscess, otitis media, mastoiditis, sinusitis, and suppurative cervical lymphadenitis
What clinical findings increase the likelihood that pharyngitis is due to GABHS?	Tonsillar exudates; swollen, tender, anterior cervical lymph nodes; history of fever; absence of cough

What office-based laboratory testing is available for the diagnosis of GABHS?

Rapid antigen detection tests and throat culture

Does a negative rapid antigen detection test rule out GABHS?

No. Rapid antigen detection tests have a sensitivity of approximately 85%; therefore, the diagnosis cannot be ruled out with certainty on the basis of a negative test.

What is the gold standard diagnostic test in GABHS?

Throat culture

When should one order the throat culture?

Negative rapid antigen detection test with a high index of clinical suspicion for GABHS

If the rapid antigen test is positive for GABHS, is throat culture required?

No

What is the treatment of choice for pharyngitis as a result of GABHS?

Oral penicillin for 10 days

What treatment is recommended for GABHS in patients with penicillin allergy?

Erythromycin

INFECTIOUS DISEASES

CASE 8

A 4-year-old girl presents from day care with her mother to your clinic in December with a 3-day history of nonbloody diarrhea preceded by multiple episodes of vomiting.

What broad differential diagnosis are you considering?

Viral

Enterovirus, rotavirus, adenovirus, and Norwalk virus

Bacterial

Salmonella, Shigella, Yersinia, Campylobacter and enteroinvasive *Escherichia coli*, *Staphylococcus*, and *Clostridium difficile*

Is viral or bacterial cause more likely here?

Viral for 2 reasons: first, viral is the most common cause of diarrhea in children (70–80%). Second, vomiting preceded the diarrhea and no blood or mucous is described with the diarrhea, which is more consistent with a viral cause.

Which bacterial organism should you keep in your differential diagnosis?

Staphylococcus, because it also produces both vomiting and diarrhea

What clue in the presentation helps narrow down your differential diagnosis for the causative virus?

Season of the year

Name the most common virus in

Winter (in this case) and spring

Rotavirus

Summer

Enterovirus

Name other causative viruses not associated with a particular season.

Adenovirus and Norwalk virus

What then is the most likely cause of this patient's diarrhea?

Rotavirus

Pertinent positive physical exam findings include pulse of 130, respiratory rate of 24, dry mucus membranes, 2-lb weight loss from last clinic visit, and stool heme. What do these findings suggest?

Dehydration (yes) and viral etiology (no blood in stool)

What basic lab tests should be considered to strengthen your diagnosis?

CBC with differential (WBC high in invasive infectious process), Chem 8 (check of evidence of dehydration and acid–base imbalance from diarrhea with or without vomiting), blood cultures (if suspect bacteremia)

What presenting sign and symptom would make you suspect bacteremia?

Fever, chills

What are the stool diagnostic tests of choice?

Stool culture and Gram stain, fecal PMN count, and fecal occult blood test

What are the associated lab findings for bacterial organisms?

Positive fecal occult blood with numerous PMNs

What additional tests can be ordered to confirm a viral etiology?

Rotazyme assay (if rotavirus suspected, winter), ELISA test for suspected virus

What is the treatment strategy for both viral and bacterial gastroenteritis?

Supportive with oral rehydration as needed

When is antibiotic use indicated?

Shigella infections and other bacterial gastroenteritis that is failing conservative treatment

What antibiotic is recommended to treat *Shigella* and many other bacterial organisms causing gastroenteritis?

Bactrim

Are antidiarrheal medications (e.g., Lomotil, Imodium) recommended?

No

CASE 9

A concerned mother brings her 2-year-old child 2 weeks after a family reunion with 12 other cousins with a new rash preceded by a low-grade fever, lack of appetite, and decreased playful activity. She states the rash began on the face and trunk, then spread to the extremities. The rash began as small, round, flat or raised red areas then progressed to small pruritic vesicles with clear fluid.

What differential diagnosis should you consider?

Chicken pox (varicella-zoster virus), Coxsackie virus, disseminated herpes simplex virus, echovirus, and atypical measles

What question should you ask her about the family reunion?

Did any of the children have a similar rash?

She informs you that her cousin's son had small, clear vesicles on his face, hands, and arms. What diagnosis do you suspect?

Chicken pox caused by the varicella-zoster virus

Why?

Sick contact 10–20 days ago, prodrome and constitutional symptoms, rash began on face and trunk and spread to extremities, started maculopapular to vesicular

What test can you order to confirm your clinical suspicion?

Tzanck smear

What treatment can you offer?

Diphenhydramine (pruritis) and acetaminophen (fever)

CASE 10

A 4-year-old newly adopted child from a developing country presents with malaise, fever of 102°F, conjunctivitis, cough and runny nose, and a rash. The rash began on the head and progressed caudally to the trunk and extremities. On exam it appears confluent, erythematous, and maculopapular.

What is your differential diagnosis?

Kawasaki syndrome, infectious mononucleosis, scarlet fever, toxoplasmosis, drug eruption, and mycoplasma pneumonia

On exam you identify small blue-white punctate spots with whitish centers on the buccal mucosa. What are these called?	Koplik spots
What is your diagnosis now?	Measles (rubeola) with the 3 C's—cough, coryza, and conjunctivitis
Why?	Because these buccal spots are pathognomonic for measles
How could the diagnosis be confirmed?	ELISA test (rarely done)
What causes measles?	Paramyxovirus
How is it transmitted?	Respiratory secretions
What most likely put this child at risk of contracting the illness?	Inadequate immunizations in the developing country
What is the treatment?	Supportive (rest, oral rehydration, and acetaminophen for fever)

CASE 11

In a rural town within a developing country you see a 6-year old-boy with fever, malaise, headache, abdominal pain, and swollen neck. On exam you find bilaterally swollen parotid glands.

What's your differential diagnosis?	Mostly viral agents (paramyxovirus, influenza A, Coxsackie virus, parainfluenza, HIV), diabetes, uremia, and drugs
What's the most likely cause in this child?	Paramyxovirus (mumps)
How do you make the diagnosis?	By history and physical exam
Which elevated serum chemistry tests would support your diagnosis?	Elevated amylase and lipase

How can the diagnosis be confirmed?	ELISA test for paramyxovirus (rarely done)
Why is this disease uncommon in the United States?	Proper immunization of children protects against contracting the illness.
How do unimmunized children spread the virus?	Nasopharyngeal secretions
What are children with mumps at risk for?	Pancreatitis, meningitis, encephalitis, hearing loss, and orchitis (in pubescent males)
What is the treatment?	Supportive (oral rehydration and acetaminophen as needed)
How long will the illness last on average?	1 week

CASE 12

A recently illegally immigrated mother brings her 18-month-old child in with a rash. 1–5 days prior to the rash the child had low-grade fever, cough, conjunctivitis, coryza, malaise, headache, and lymphadenopathy for 1–5 days. The rash began on the head and progressed to the trunk and extremities. On exam it appears erythematous and maculopapular.

What is your differential diagnosis?	Measles (both rubella, rubeola), scarlet fever, infectious mononucleosis, toxoplasmosis, erythema infectiosum, drug rash
What is the significance of immigration?	Suspect incomplete immunization record
What 2 illnesses top your differential diagnosis?	Measles (both rubella, rubeola)
To help distinguish between the two, you go back to examine the patient's rash and one finding solidifies your diagnosis. What did you notice?	The rash does not coalesce, which is different from coalescing rash seen in rubella (measles).

What's your diagnosis now?	Rubella (German measles)
You've made a tentative diagnosis based on history and presentation. How can you confirm it?	Increase in serum antibodies to rubella virus
How is it treated?	Supportive (most spontaneously resolve); NSAIDs (acetaminophen) for fever
Is this child contagious?	Yes, for 1 week before and after onset of rash
So what additional measures should you take?	Do not expose patient to unimmunized individuals (especially pregnant women) 1 week before or after onset of rash.
Which viral agent causes it?	Togavirus
How was it transmitted?	Airborne nasopharyngeal droplets or transplacental passage to fetus
Who is at greatest risk of contracting the illness?	Fetuses of unimmunized pregnant women in the first and second trimesters
What increases the risk in adolescents and adults?	Inadequate MMR vaccination as a child
If this child had been a neonate of an unimmunized mother, how would he have presented?	Congenital anomalies (over 50%) with risk of hydrops fetalis
If an unimmunized pregnant woman is exposed to togavirus, should she be immunized?	No, rubella immunization is contraindicated during pregnancy.

CASE 13

A mother brings her 7-year-old boy in for once-weekly bedwetting and infrequent wet daytime pants for the last 4 months.

What's your differential diagnosis?	Primary enuresis; secondary enuresis to ADH deficiency (rare), diabetes mellitus (DM), UTI, obstruction, and developmental delay
If this child were 4 years old, would you be concerned?	No, because some boys take up to 6 years old to control their bladders (5 years old for girls).
If this child were having incontinence only once every 5 weeks, would it be considered abnormal?	No, it is a problem when it occurs more than once a month.
What lab tests should you order?	UA (detects UTI and DM) and culture
Labs and culture come back normal (no UTI or DM). What is your diagnosis?	Primary enuresis
What's the treatment?	Use of a nighttime audio alarm that sounds when child urinates (assists bladder control conditioning)
The mother comes back for 2 successive follow-ups and the problem persists. What's your next step?	Consider medical therapy with imipramine (tricyclic antidepressant) or intranasal desmopressin acetate (an endogenous vasopressin analog).
What risks are associated with imipramine therapy?	Arrhythmias, conduction blocks, accidental overdose, and death
What study should be ordered prior to starting a child on imipramine?	EKG

CASE 14

A previously healthy 1-year-old child comes to the emergency room in November with a 3-day history of mild cold symptoms including runny nose, slight cough, and feeling hot. Over the last 24 hours, the child's cough has worsened and breathing is slightly more labored, but he is still breast-feeding well. On exam you find low-grade fever, mild tachypnea, and soft expiratory wheezing.

What differential diagnosis should you be considering?

Viral bronchiolitis, asthma, vascular ring, foreign body, congenital heart disease, pneumonia, reflux, aspiration, croup, and cystic fibrosis

What tests should you consider ordering?

CBC, serum electrolytes, urinalysis, pulse oximetry measurement, and CXR

All tests are normal except for mild leukocytosis and peribronchial thickening on CXR. What is your most likely diagnosis?

RSV bronchiolitis

What can you order to confirm your diagnosis?

Immunofluorescent or enzyme immunoassay detection of RSV antigen of suctioned nasal secretions

What severity of RSV bronchiolitis does this child have?

Mild

What is the management of mild RSV bronchiolitis?

Home with supportive treatment, oral hydration, and nasal suctioning

48 hours later the mother brings the child back with significant wheezing, tachypnea, fever, nasal flaring, retractions, cyanosis, decreased air entry, and prolonged expiratory phase with wheezing. Your prior diagnosis of RSV bronchiolitis is confirmed by lab review and the prior lab panel and CXR is ordered. What should you do first?

O₂ supplementation, pulse ox monitoring (observation for apnea and respiratory failure), ABG (because of cyanosis), inhaled bronchodilators such as albuterol or racemic epinephrine can be tried cautiously, IV hydration, Tylenol

Would corticosteroids or antibiotics be helpful?

No

What should you do once you've stabilized the patient?

Order CBC, chem 8, UA, blood culture, and CXR

Labs confirm infection (leukocytosis), dehydration (elevated BUN/Cr), and mild hypoxia, and radiographic imaging confirms worsened parenchymal disease. Should this patient be discharged with supportive care?

No, hospital admission is warranted.

What are some hospital admission criteria for patients with RSV bronchiolitis?

Children with dehydration, poor oral intake, significant respiratory distress, hypoxia, and apnea

What complication did this patient have?

Respiratory failure and atrial tachycardia

What additional complications are there?

Pneumonia and apnea

What additional investigations should be considered during hospitalization?

Risk factors for severe RSV bronchiolitis

What are they?

Premature birth, chronic lung disease (CLD), bronchopulmonary dysplasia, cystic fibrosis, congenital heart disease, and immunodeficiency

What is the mechanism of disease for viral bronchiolitis?

Viral inflammation of the small airways resulting in necrosis of the respiratory epithelium, obstruction of the airway lumen, and leukocyte peribronchial infiltration causing edema of the bronchiolar wall

What are the causes of viral bronchiolitis?

RSV is the most common cause. Other less common viruses include influenza, parainfluenza, and adenovirus.

How do RSV infections occur in the Northern Hemisphere?

In epidemics between October and April of each year.

What age groups are most susceptible to RSV bronchiolitis?

Children younger than 2 years of age

What control measures should be taken to minimize spread of RSV infection to susceptible children in the hospital?

Segregation of infected infants and staff is required. Infected children should be placed in contact isolation and the use of gowns, gloves, and strict hand washing should be observed.

How could RSV bronchiolitis be prevented?

RSV immune globulin intravenous (RSV-IGIV) and Palivizumab are 2 drugs that were produced by the same manufacturer and have been approved for the prevention of RSV infection. Either monthly intravenous RSV-IGIV or monthly intramuscular Palivizumab is given during the RSV season for a total of 5 treatments.

Who should be given RSV-IGIV or Palivizumab?

Children younger than 2 years of age with CLD who required treatment for CLD within 6 months before the start of their first RSV season. Infants born before 32 weeks of gestation with or without CLD may benefit from prophylaxis based on the gestational age at birth, chronological age at the start of the first RSV season, and their community RSV bronchiolitis rehospitalization data.

CASE 15

When a child comes to your office with a chief complaint of sore throat, what is your broad differential diagnosis?

Pharyngitis

Viral?

Adenovirus (most common), Coxsackie, EBV, influenza, rhinovirus, parainfluenza, RSV, measles, rubella, HIV, and herpes simplex

Bacterial?

GABHS (*Streptococcus pyogenes*) (most common agent), *Mycoplasma pneumoniae*, group G and C streptococci, *Arcanobacterium hemolyticum*, *Corynebacterium diphtheriae*, *C. hemolyticum*, *Neisseria gonorrhea*, *N. meningitidis*, *Francisella tularensis*, *Treponema pallidum*, oropharyngeal anaerobes, and *Chlamydia pneumoniae*

For each risk factor below (presentation clue to pay attention to), name the associated agent known to cause pharyngitis.

Overcrowding*Streptococcus* species**Sexual activity***N. gonorrhea*, *T. pallidum*, EBV**Swimming in an inadequately chlorinated pool**

Adenovirus

Eating undercooked meat

Tularemia

Incomplete immunization

Diphtheria

Immunodeficiency

Fungus

Use of antibiotics*Candida* (thrush)

What are some nonspecific symptoms of pharyngitis?

Fever, sore throat, hoarseness of voice, rhinorrhea, cough, conjunctivitis, and cervical lymphadenopathy

CASE 16

A 12-year-old girl presents to your clinic with complaints of sore throat for 3 days with associated cough and pea-sized bumps in her neck.

On physical exam, if you found these findings, what agent would rise to the top of the list on your differential diagnosis?

Pharyngeal erythema, tonsillar exudates, enlarged tonsils, lymphadenopathy, and hepatosplenomegaly

Infectious mononucleosis viral pharyngitis

Significant pharyngeal erythema and petechiae, white tonsillar exudates, tender anterior cervical lymphadenopathy, and scarlatiniform (sand paper-like) rash

Streptococcal pharyngitis

Pharyngeal or oral nodules or ulcers, conjunctivitis, and skin rash

Enteroviral pharyngitis

You've completed your exam and are confident of the diagnosis below. What test will you order to confirm or strengthen your diagnosis?

S. pyogenes pharyngitis

Throat culture (diagnostic) and rapid streptococcal antigen detection tests

Infectious mononucleosis

Peripheral smear looking for more than 10% atypical lymphocytes, Monospot (heterophil antibodies), and EBV IgM antibody serology (best test)

You've made your diagnosis below. What's your treatment?

Viral pharyngitis

Symptomatic: analgesics and antipyretics

GABHS pharyngitis

Oral or IM penicillin V (oral erythromycin if PCN allergic)

CASE 17

A 4-year-old Japanese child presents with temperature of 103°F for the last 5 days. On exam you find an erythematous rash, conjunctivitis, cervical adenopathy, and swollen hands and feet.

What's your differential diagnosis?

Kawasaki disease, scarlet fever, toxic shock, leptospirosis, EBV, juvenile rheumatoid arthritis, measles, Rocky Mountain spotted fever, drugs, and Stevens-Johnson syndrome

Which disease is most likely?

Kawasaki disease

Why?

Child is younger than 5 years of age, Japanese (most often affected), and meets 2 of the criteria for the diagnosis

Elaborate on the following criteria to make the diagnosis

Fever

Unexplained for at least 5 days

Physical exam

4 of the following 5 symptoms are present: conjunctivitis, mucus membrane changes (strawberry tongue, dry cracked lips), cervical lymphadenopathy, rash, and changes in hands or feet with swelling or desquamation (usually occurs later if at all)

What labs should you order and what do you expect to find on

CBC?

Leukocytosis with left shift, anemia, thrombocytosis

CRP and ESR?

Elevated

LFTs?

Elevated

What additional tests do you need to order?

CXR, EKG, echocardiogram

Why?

Kawasaki disease is a febrile illness associated with vasculitis of the coronary arteries (1/4 of cases) causing them to acutely thrombose or chronically stenose, putting the child at risk of a myocardial infarction.

What is the treatment?

Intravenous γ -globulin and salicylates

CASE 18

A 4-year-old child comes to the ER with sudden onset of fever, sore throat, drooling, leaning forward with hand on knees with inspiratory stridor, and respiratory distress.

What's your differential diagnosis?	Epiglottitis, croup, pertussis, retropharyngeal abscess, foreign body, angioneurotic edema
What diagnosis is most likely?	Epiglottitis
How is this presentation distinguished from that of croup?	Children with croup usually have an associated upper respiratory infection; children with epiglottitis do not.
What do you need to do first with this child?	Get equipment ready for intubation or tracheostomy if needed.
Should you examine the airway by using a tongue blade?	No
Why?	Any examination or irritation of the airway may induce laryngospasm and complete airway obstruction.
Is there a safe way to examine the airway?	Yes
How?	Transport the patient sitting up to the OR for direct visualization of the epiglottis with a fiberoptic laryngoscope with intubation gear ready.
What do you expect to see?	Swollen cherry red epiglottis
What radiographic image would support your diagnosis?	Lateral neck x-ray showing the "thumbprint sign" of a swollen epiglottis
Should the x-ray be ordered when the patient has respiratory distress?	No, it delays setting up for and securing a stable airway.

What infectious agents cause epiglottitis?

H. influenzae type B (vaccine use has greatly decreased the incidence), *Streptococcus*, and *Staphylococcus* species

How does it begin?

As cellulites between the tongue base and epiglottis that displaces the epiglottis posteriorly

The diagnosis has been made. What's the treatment?

Intubation and IV cefuroxime

NEPHROLOGY

CASE 19

A 6-year-old boy had a viral syndrome 1 week ago, was given aspirin, and now presents with fever, intractable vomiting, lethargy, and confusion.

What's your differential diagnosis?

Encephalitis, meningitis, inherited metabolic disorders, drug intoxication, uncontrolled diabetes, Reye syndrome

Pertinent positive physical exam findings include fever of 103°F, mild liver enlargement, no jaundice, fever, or focal neurological findings. Which diagnosis is most likely?

Reye syndrome based on preceding viral illness, aspirin ingestion, then fever, vomiting, and altered mental status with above exam findings

What illnesses is this associated with?

Influenza A and B, and varicella (chicken pox). Other viruses have been implicated as well.

What causes it?

An acute syndrome of unknown etiology causing encephalopathy and fatty degeneration of the liver

What causes the neurologic changes?

Cerebral edema leading to increased intracranial pressure

What labs should you order when suspecting Reye syndrome?

CBC, Chem 8, LFTs, ammonia, coags (PT, PTT, INR)

What change do you expect to see in the following laboratory tests?

ALT and AST	Markedly increased
Total bilirubin and alkaline phosphatase	Normal or slightly increased
Ammonia	Elevated
PT	Prolonged
Creatinine kinase and lactic dehydrogenase	Increased
Serum glucose	May be low

What prognostic significance does elevated ammonia and PT have?

Increased risk of coma and coagulopathy, respectively

What diagnostic procedures might you consider?

CSF studies, liver biopsy

What CSF and liver biopsy findings are consistent with Reye syndrome?

CSF Increased CSF pressure without leukocytosis (not an infectious process)

Liver biopsy Foamy cytoplasm with microvesicular fat and severe mitochondrial injury

How is Reye syndrome diagnosed?

By history, physical exam, and lab findings. There is no specific test to make the diagnosis.

How is Reye syndrome treated?

Therapy is symptomatic and supportive.

MISCELLANEOUS DISORDERS

CASE 20

A 43-year-old woman delivers a baby with Down syndrome and your attending asks you to examine the infant and report what physical exam findings are consistent with the diagnosis.

What will you be looking for on the

Eyes?	Speckled iris
Nose?	Broad bridged
Face?	Flattened, upward slanted palpebral fissures, epicanthal folds
Mouth?	High arched palate, protruding tongue
Neck?	Webbed

4 hours after birth, the baby begins bile-stained emesis. What disorder do you suspect?

Duodenal atresia because infants with Down syndrome are at a greater risk of this disorder

What test will you order to confirm your diagnosis

Abdominal x-ray

What do you expect the report to read?

Double bubble sign

What is the treatment?

Surgery

The mother is distressed because no one ever told her she was going to have a child with Down syndrome and she does not want to have any more children with this kind of surprise. You inform her there are tests to screen and diagnose the syndrome prior to birth. Name the tests and values.

Screening: Mother

Abnormal triple screening test
Decreased α -fetoprotein
Decreased unconjugated estriol
Increased human chorionic gonadotropin

Diagnostic: Fetus

Chromosomal analysis showing trisomy 21

Name the 3 ways in which trisomy occurs.

An individual receiving 3 copies of a chromosome, a translocation, or a mosaicism

The father pulls you aside and asks what other diseases may the child develop as a result of being diagnosed with Down syndrome. Name them by organ system:

GI

Duodenal atresia
Hirschsprung disease

Cardiac

Atrioventricular canal
Ventricular septal defect
Patent ductus arteriosus
Atrial septal defect
Tetralogy of Fallot

Neurologic/cognitive

Hypotonia and varying degrees of mental retardation

Endocrine

Hypothyroid (requires yearly TSH screening)

The father asked what put their child at risk of this condition. What is your reply?

Advanced maternal age is the major risk factor for having a child with Down syndrome (1/2000 age 20 and 1/20 age 45).

What therapy will you recommend to ensure the child reaches his full potential?

Therapy should be problem directed. Children with Down syndrome should receive the therapy and intervention to ensure that they reach their full potential.

CASE 21

A 14-year-old girl presents complaining that all her girlfriends' periods began last year and she is worried that there is something wrong.

What's your differential diagnosis?

Imperforate hymen, mullerian agenesis, constitutional delay, Turner syndrome (TS)

On a limited physical exam you find short stature, sparse pubic-axillary hair, and failure of development of secondary sex characteristics. What is your lead diagnosis in the differential now?

TS

What would you expect to find on a complete physical exam?

Webbing of neck, cubitus valgus, low hair line, low-set ears, micrognathia, shield chest with widespread nipples, short 4th metacarpals, lymphedema of feet or hands

What lab tests should be ordered to support your diagnosis?

Follicle-stimulating hormone (FSH) and luteinizing hormone (LH)

What impact does the disease have on these levels?

Increased

What does this signify?

Ovarian failure

What test do you order to confirm the diagnosis?

A karyotype analysis

What result do you expect?

Absence or abnormality of an X chromosome, 45, XO

What is the treatment for patients with TS?

Sex steroid supplementation

What additional imaging tests should you order now that the diagnosis has been made?

Renal and cardiac ultrasound to detect anomalies

Name the renal and cardiac disorders associated with TS.

Renal

Horseshoe kidney, double collecting system

Cardiac

Bicuspid aortic valve, aortic coarctation, aortic stenosis

MISCELLANEOUS CASES

A 6-month-old baby is crying excessively, has a bruise on her forehead, and has retinal hemorrhages evident on ophthalmologic exam. The mother is distraught and states she feels guilty because she dropped the child by accident when picking her up. What is the most likely diagnosis?

Shaken baby syndrome (a form of physical child abuse)

An 8-month-old child is brought in for her third visit in 2 weeks with poor weight gain, poor skin turgor, and no mittens or winter coat with a temperature of 40°F outside. What is the most likely diagnosis?

Neglect

A 6-year-old child has had repeated visits to the school administrators for truancy and poor scholastic performance. What is the most likely diagnosis?

Neglect

A 12-year-old girl returns to the clinic with recurrent abdominal pain, UTI, and trace amounts of vaginal bleeding. What is the most likely diagnosis?

Sexual abuse

When child abuse is suspected, what do you need to do first?

Contact child protective services with a full report (your legal obligation); do not allow child to return home.

What additional workup is required for each type of abuse?

Sexual

Tests for gonorrhea, chlamydia, syphilis, and HIV even if genital exam is normal

Physical

X-rays (complete skeletal survey)

What is your basic treatment plan for all forms of child abuse?

Contact social services, do not allow child to go home, treat any associated injuries or infections, and arrange counseling for child and family.

Chapter 12

Psychiatry

PSYCHOSIS

CASE 1

You're called to see a 17-year-old previously healthy female who returned from college after her dorm supervisor found her wandering in the hall talking to herself. When asked what was wrong, she said the dorm room numbers were codes for others to inflict harm on her. Her roommates and dorm room neighbors deny any such intent.

What should you be concerned about?

Schizophrenia

What's a brief differential diagnosis for schizophrenia?

Bipolar disorder, schizoaffective disorder, and brief psychotic disorder

What is the common age of onset for schizophrenia?

Late teens to early 30s (she's 17)

What causes it?

Etiology unknown, but dopamine hyperactivity has been implicated (dopamine hypothesis)

Describe the 5 subtypes of schizophrenia.

Paranoid

Paranoid delusions, auditory hallucinations, and nonflat affect (best prognosis)

Catatonic

Psychomotor disturbance ranging from excessive increase or decrease in activity, echolalia, or mutism

Disorganized

Disorganized speech and behavior, flat or inappropriate affect (worst prognosis)

Undifferentiated

Criteria not met for paranoid, catatonic, or disorganized

Residual	Period of persistent negative symptoms and/or mild positive symptoms after 1 acute episode of schizophrenia
Which subtype is most likely in her?	Paranoid schizophrenia
How is the diagnosis made?	Presence of symptoms, associated with social and occupational deterioration for at least 6 months
What determines the type of treatment?	Presence of positive or negative symptoms
What are the positive symptoms?	Delusions, hallucinations, disorganized speech or behavior, and catatonic behavior
What are the negative symptoms?	Flat affect apathy, anhedonia inattentiveness
What is the first-line treatment for positive symptoms?	Antipsychotic medications—haloperidol (higher potency for severely agitated or disruptive behavior) or chlorpromazine (lower potency)
What is the mechanism of action for haloperidol and chlorpromazine?	Dopamine receptor antagonists
What is an alternative medication for patients with negative symptoms?	Risperidone
What medication is prescribed if patients fail first-line agents?	Clozapine
What is the dreaded complication of schizophrenia?	Suicide

DISORDERS ORIGINATING IN CHILDHOOD

CASE 2

A 5-year-old boy arrives at your family practice clinic after being reprimanded many times in the last 12 weeks for excessive talkativeness and inability to complete school classroom projects.

What could the child have?	Attention-deficit hyperactivity disorder (ADHD)
What is ADHD?	A disorder characterized by inattention, impulsiveness, and hyperactive behavior in young children often labeled as “troublemakers”
What causes it?	Etiology unknown, but depletion of the neurotransmitter dopamine has been implicated as well as prenatal substance abuse
Which sex is it more common in?	Male (4:1)
Describe the following typical behaviors:	
Inattentive	Inability to complete tasks (often in school); easily distracted or forgetful
Impulsive	Impatient and frequently interrupts
Hyperactive	Excessive talkativeness, restlessness, or fidgety behavior
How is it diagnosed?	Age <7 and symptoms present in 2 separate locations (e.g., school and home)
So what’s the next step with this child?	Ask the mother about behavior in other settings
What is the first-line treatment for ADHD?	Employ behavior-management techniques
What’s the next step?	Consider psychostimulants such as methylphenidate (Ritalin), if necessary

What are the side effects of Ritalin?

Insomnia, depressed mood, irritability, tics, and decreased growth rate (higher doses)

ANXIETY

CASE 3

A patient's wife calls you concerned that her husband is worrying excessively about financial matters and local and world events and, as a result, has had little sleep for 9 months. She is not sure why he is so anxious.

What could this patient have?

Generalized anxiety disorder

What are the main clinical features?

Excessive, persistent, uncontrollable anxiety or apprehension about most daily events

What additional symptoms may be present secondary to the anxiety?

Difficulty concentrating, restlessness, easily fatigued, sleep disturbance, and muscle tension

What lab tests are included in the workup to rule out anxiety secondary to a medical condition?

Thyroid function tests, glucose, CBC, electrolytes, and calcium

What basic cardiac study should be considered in the workup?

EKG

How is it diagnosed?

Persistent anxiety that occurs most days for at least 6 months with at least 3 secondary symptoms

What is the first-line therapy?

Psychotherapy and relaxation techniques

What is the second-line therapy?

Anxiolytics (e.g., benzodiazepines and buspirone)

CASE 4

A mother brings her 13-year-old child into the office complaining that he is obsessive about personal hygiene. She says it is not uncommon for her son to spend 20 minutes in the bathroom just washing his hands after using the bathroom. He is concerned about his repetitive hand washing, but has difficulty stopping.

What is this presentation classic for?	Obsessive–compulsive disorder
Define an obsession.	Persistent intrusive thoughts, impulses, ideas, or images that cause significant anxiety and cannot be controlled
Define a compulsion.	A repeated mental or motor behavior performed to lessen anxiety, often follows obsession
What are some examples of compulsions?	Repetitive checking, washing, and counting
How is it diagnosed?	Recurrent obsessions and compulsions that cause significant distress. Patient must be aware that these do not make sense.
What is the first-line medical therapy?	Selective serotonin reuptake inhibitors (SSRIs) (e.g., fluvoxamine)
What is the next medical therapy available?	Tricyclic antidepressants (TCAs) (e.g., clomipramine)
What additional therapy should be considered?	Behavior modification techniques (e.g., systemic desensitization and flooding)

CASE 5

A 25-year-old female presents after having repetitive episodes of intense fear with palpitations and sweating while driving on the expressway. It often happens while driving the speed limit during time periods other than rush hour. The intense fear of an accident causes her to pull over to the side of the road and rest for about 20 minutes. After 6 episodes, she is worried about additional attacks and the impact on her ability to function.

What disorder is most likely?

Panic disorder

How does it present?

Often females 20 to 30 years old with recurrent, unexpected, discrete periods of intense fear or discomfort, with 4 or more panic symptoms and constant worry about having another attack

Name some common panic attack symptoms.

Palpitations, accelerated heart rate, sweating, shaking, shortness of breath, feeling of choking, chest discomfort, nausea, dizziness, fear of losing control, or dying

What associated cardiac disease might be found on physical exam?

Mitral valve prolapse

What laboratory test should you order and why?

TSH to exclude thyroid disease

How is it diagnosed?

Recurrent attacks (at least 4 symptoms) with at least 1 month of associated anxiety

What other disorder may occur with panic disorder?

Agoraphobia

Define agoraphobia.

Intense fear of places or situations in which escape might be difficult or help may not be available, if panic symptoms occur

What medical treatments are used to treat panic attacks?

TCAs (desipramine), monoamine oxidase inhibitors (MAOIs) (phenelzine), SSRIs (fluoxetine), and benzodiazepines (alprazolam)

What additional therapy should be considered?

Cognitive-behavioral therapy (e.g., relaxation exercises and desensitization)

What is the treatment for agoraphobia?

Exposure therapy

CASE 6

A 55-year-old Vietnam veteran comes to your office complaining of difficulty sleeping owing to recurrent flashbacks to his bloody combat days after attending a veteran reunion. He awakes in a sweat with his heart pounding and has difficulty falling back to sleep.

What is this presentation consistent with?	Posttraumatic stress disorder
What is the main risk factor?	Traumatic events (e.g., rape, assault, combat, and natural catastrophes)
How does it present?	Re-experience (recurrent hallucinations, illusions, or flashbacks of the event), increased arousal (anxiety, sleep disturbance, and hypervigilance), and avoidance of stimuli associated with the trauma
How is it diagnosed?	Presenting symptoms (above) lasting more than 1 month during which time patient must have experienced severe fear, hopelessness, or horror
So, what is the key question for this patient?	Duration of symptoms
What is the treatment?	Psychotherapy and TCAs (e.g., imipramine) and SSRIs (e.g., fluoxetine)
What is an alternative drug for imipramine?	Phenelzine (MAOI)

CASE 7

A 29-year-old female comes to your office after experiencing excessive amounts of fear during public speaking events and now has considerable apprehension about future talks. Upon further questioning, you find out that she has also been fearful of large social functions such as weddings since she was a teenager.

What is this most likely?	Social phobia
How does it present?	Excessive, persistent fear of social or performance situations

How is it diagnosed?	History
What is the first-line treatment?	Behavioral therapy (desensitization, rehearsal)
What is the second-line therapy?	SSRIs (e.g., fluoxetine) or MAOI (e.g., phenelzine)
What medication may be useful if taken 30 minutes before performance situations?	Propranolol

MOOD DISORDERS

CASE 8

You've met your girlfriend's mother multiple times and have noticed a significant variation in her behavior. Some days she sleeps in late, has decreased interest in her usual activities, and complains of fatigue. Other times she has high self-esteem, loves to travel, and works feverishly on her hobbies and goals. Everyone in your girlfriend's family says that's just the way she is.

What is most likely wrong with her?	Bipolar disorder
What disorders comprise it?	Mania (or hypomania) and major depression
Describe features of a manic episode.	Elevated self-esteem, decreased sleep, pressured speech, racing speech, flight of ideas, easily distracted, increased goal-directed activity, excess involvement in pleasurable activities like sex, spending, and travel
How is a manic episode diagnosed?	Three to 4 of the above features lasting 1 week or severe enough to require hospitalization
Define bipolar I disorder.	At least 1 episode of mania with or without a major depressive episode (for description see respective section)

Define bipolar II disorder.	One or more hypomanic episodes plus one or more major depressive episodes (no history of manic episode)
What medications may be used for rapid treatment of manic episodes?	Benzodiazepines or antipsychotics
What is the long-term treatment strategy?	Psychotherapy, cognitive therapy, lithium (monitor levels closely due to toxic potential)
What is a frequently tested side effect of lithium?	Hypothyroidism
What second-line drugs are available to treat mania?	Carbamazepine and valproic acid

CASE 9

A 44-year-old patient comes to your clinic for routine follow-up and you find out that he recently lost his job 6 months ago and is having a hard time finding work. He later remarks that he has been having difficulty sleeping, has decreased energy, and is not playing nearly as much golf as usual for the last 4–5 months.

What diagnosis is most likely here?	Adjustment disorder with depressed mood (ADDM)
Why is it not major depression?	ADDM presents with depressed or anxious mood within 3 months of identifiable stressor, lasting less than 6 months; mood change is excessive and/or impairs social/occupational functioning.
What stressor did he have?	Lost his job
Name other common stressors preceding ADDM.	Marital problems, divorce, moving, financial hardship, and criminal victim
How is it diagnosed?	History and presentation (as above)
What is first-line therapy?	Psychotherapy
What is the treatment for severe anxiety?	Short-term use of benzodiazepines

What is the treatment for depressed mood? Antidepressants (use is controversial)

CASE 10

A 44-year-old female presents with impaired sleep, decreased interest in typical activities, fatigue, and anorexia 3 months after her husband died in an auto accident. Her symptoms have not changed significantly over the last 3 months.

What's in your differential diagnosis? Normal or complicated bereavement

How do they both present? Sudden or delayed onset (up to a year) of depressive symptoms following loss of loved one after a traumatic event

What are typical traumatic events? Sudden or traumatic death, death of a child, concurrent stress, insecure personality

When does normal bereavement become complicated? When symptoms persist for >2 months

What is the therapy? Bereavement therapy

When should hospitalization be considered? If patient is at risk of suicide

What are patients at risk for? Major depression and suicide

CASE 11

A 39-year-old male patient arrives at your office for his first visit after moving from another state. He has no specific complaints other than feeling depressed. This is no different than he has felt for years and he just goes on with his life. His last doctor referred him to a psychiatrist and diagnosed him with a milder form of depression, not major depression.

What diagnosis most likely was it? Dysthymic disorder

What is it? A chronic form of mild depression

How does it present?	Almost continuous depressed mood and symptoms most of the time for at least 2 years
Name some common depressive symptoms.	Change in appetite, sleep disturbances, fatigue, low self-esteem, decreased concentration, and feelings of hopelessness
How is it diagnosed?	History and presentation
What is the treatment?	Psychotherapy and antidepressants

CASE 12

A 30-year-old previously healthy female comes to your office with her husband complaining that she has no energy, no interest in playing her beloved piano, feelings of worthlessness, sleeping all the time, difficulty concentrating, and had a 10-lb weight loss. The remainder of her review of systems and physical exam is normal.

What's the differential diagnosis?	Major depressive episode, bipolar disorder, dysthymic disorder, depression secondary to undiagnosed medical condition
Which is most likely?	Major depressive disorder
In what age range does major depression typically appear?	20–50 years (she's 30)
What mnemonic can be used to remember the criteria to diagnose major depression?	SIGMECAPS
Describe what each letter represents.	
Sleep	Insomnia or hypersomnia
Interest	Marked decrease in interest and pleasure in most activities
Guilt	Feeling worthless or inappropriate guilt
Mood	Depressed mood most of the day, nearly every day

Energy	Fatigue or low energy nearly every day
Concentration	Decreased concentration or increased indecisiveness
Appetite	Increased or decreased, or weight gain or weight loss
Psychomotor	Psychomotor agitation or retardation
Suicidality	Recurrent thoughts of death, suicidal ideation, suicide plan, suicide attempt
How is it diagnosed?	5 or more of the above criteria for at least 2 weeks; 1 symptom must be depressed mood or loss of interest or pleasure and no history of manic episodes.
What lab tests should be ordered to rule out major depression secondary to another medical condition?	CBC, electrolytes, liver function test, urinalysis, thyroid function tests, and drug screen
What radiographic studies may be ordered to exclude intracranial causes?	CT or MRI
What is the treatment for milder cases?	Psychotherapy (e.g., supportive, cognitive-behavioral, and brief interpersonal therapies)
What additional treatment is available?	Pharmacotherapy [e.g., SSRIs, TCAs, and MAOIs]
What 2 neurotransmitters have been implicated in major depression?	Norepinephrine and serotonin
What determines which medication is prescribed?	Medication history and side-effect profile of the medication
What is considered an adequate trial of a medicine?	Four weeks at maximum recommended dose

In which patients are SSRIs (e.g., fluoxetine, sertraline, and paroxetine) especially useful?	Cardiac disease patients (minimal risk of cardiac complications) and patients at risk of suicide (overdose less likely to be fatal)
What are the common side effects of SSRIs?	GI side effects, sexual dysfunction, and appetite suppression
Name some commonly prescribed TCAs.	Amitriptyline, nortriptyline, imipramine, desipramine, and doxepin
What are the side effects of TCAs?	Anticholinergic side effects (e.g., dry mouth, constipation, cardiac arrhythmias), sexual dysfunction, and potential for fatal overdose
Name 3 MAOIs.	Phenelzine, tranylcypromine, and isocarboxazid
When are MAOIs useful?	In patients with excessive anxiety (including panic symptoms) or with mild atypical depression (e.g., increased sleep, increased appetite)
What is the main side effect of MAOIs?	Hypotension
What are patients taking MAOIs at risk of if they eat foods containing tyramine?	Tyramine hypertensive crisis, which can lead to death
What foods contain tyramine?	Aged cheese, red wine, and aged/processed meats
When should electroconvulsive therapy be considered?	Patients who fail pharmacotherapy or who are acutely suicidal
When should a patient be hospitalized?	When it has been determined that the patient has a significant risk of harming himself or others (e.g., those with command auditory hallucinations) because of their mental disorder

CASE 13

A 32-year-old 1-week postpartum female who recently resigned from work to stay home with her newly born son develops depressive symptoms.

What's the differential diagnosis for postpartum mood disorders?

Postpartum blues, postpartum depression, puerperal psychosis

What risk factor for postpartum depression does she have?

Unemployment

Name other major risk factors for postpartum depression.

Previous mood disorder, particularly postpartum; social stresses (e.g., marital conflict, limited social support); infant health problems or irritability

What causes them?

A combination of genetic predisposition and physiologic changes (e.g., decreased estrogen, progesterone, and cortisol) and psychosocial factors

How do they present?

Postpartum blues

Mild depressive symptoms that develop in the first week postpartum and resolve in the second week; very common—up to 85% of postpartum women

Postpartum depression

A major depressive episode occurring within 4 weeks of childbirth; common—up to 15% of postpartum women

Puerperal psychosis

A psychotic disorder developing in the weeks postpartum; usually presents as a mood episode with psychotic symptoms; rare—1/1000–1/1500 postpartum women; medical emergency

Which two are more likely in her?

Postpartum depression or blues (mild depressive symptoms)

What's your next step?

Apply SIGMECAPS mnemonic for major depression and if 5 or more present, diagnosis is made; otherwise postpartum blues is diagnosed

What is the treatment for postpartum depression?	Psychotherapy (interpersonal or cognitive behavioral) and medication; ECT for severe symptoms
What medications are used to treat postpartum depression?	SSRIs are first-line, TCAs are a frequent second choice
What specific concerns are there with postpartum drug therapy?	All psychoactive medications are secreted into breast milk; effect on infant is generally unclear. Breast-feeding is contraindicated with lithium.
How is the mother at risk?	Poor parenting skills, plus the usual risks of depression (e.g., relationship and work problems, suicide)
How is the infant at risk?	Increased risk of retarded cognitive, behavioral, and emotional development, child abuse and neglect, and infanticide

SOMATOFORM DISORDERS

CASE 14

A 27-year-old healthy female comes to your office for her yearly exam. During the examination you find out that she plans to have a second rhinoplasty on her nose. No physical or cosmetic defects are apparent on the exam. She is adamant that the slope and angle of her left nostril is abnormal and is of significant concern thus warranting repeat surgery.

What do you think?	She may have body dysmorphic disorder (BDD).
Describe it.	Gradual onset of excessive preoccupation with an imagined defect in appearance that causes significant distress and psychosocial impairment
How will you diagnose it?	History and presentation
What is the treatment strategy?	Noninvasive treatment of any medical disorder along with psychotherapy and medication trial

What medications may be useful?	Fluoxetine (first-line drug) and clomipramine (second-line drug); if refractory, try pimozide (an antipsychotic)
What are patients at risk of?	Major depression; up to 60% of BDD patients have major depressive disorder
When is hospitalization required?	Severe depression with suicide risk (up to 1/3 of BDD patients attempt suicide)

CASE 15

At the beginning of your general neurology service month, you are signed out a patient by one of your peers after an extensive workup. The patient, a 33-year-old female, has been worked up for complaints of bilateral lower extremity weakness, paresthesias, and right-ear deafness that developed after hearing her brother was killed in a motor vehicle accident. Extensive neurologic workup has been negative. Neurologist states that the symptoms do not correlate with any known organic disease patterns. The patient is indifferent to the news and says "I guess I'll just have to go home and live with it."

Before being discharged, what else should be done?	Psychiatry consult
Why?	High suspicion for conversion disorder
How does it present?	Loss or alteration in physical functioning, usually neurologic (e.g., paralysis, aphonia, seizure, blindness, deafness); an acute stressor precedes the symptoms
Why does it occur?	Redirection of an unconscious psychological conflict or stressor into physical symptoms
How is it diagnosed?	By the presence of symptoms causing significant impairment without medical explanation and with inciting psychological stress
What is the treatment?	Psychotherapy and reassurance
What's the recurrence rate of symptoms?	25% will have another episode

CASE 16

A 33-year-old female with history of multiple atypical subcutaneous infections returns to the hospital again for complaints of multiple circular points of erythema around a pinpoint puncture site. She is afebrile and vital signs are normal. The cultures are back from her prior hospitalization for the same problem and they reveal a polymicrobial flora consistent with stool. Later, her husband arrives with a dirty syringe that he found under their bed.

What's your differential diagnosis?

Factitious disorder (a.k.a. Munchausen syndrome) and malingering

How do they present?

Intentionally produced or feigned signs and symptoms of a medical or psychiatric illness often resulting in multiple hospitalizations

What distinguishes malingering from factitious disorder?

In malingering, patient assumes sickness for external reward (most often money)

How are they diagnosed?

History, presentation, and evidence of feigned or self-induced illness

What is the treatment?

No effective therapy known; avoid unnecessary procedures and hospitalizations

CASE 17

A 25-year-old graduate student presents to your office to follow up the results of the CT head taken last week for atypical headache. For the last 7 months, she was sure she had brain cancer and took several days off work even though her headaches were mild and had no neurologic examination findings to suspect underlying malignancy. When told of the results, she questions the validity of the study because she states she is sure she has a brain tumor. When asked about her headache, she says it comes and goes.

What disorder might she have?

Hypochondriasis

How does it present?

Preoccupation with fear of getting or having a serious disease; the preoccupation causes significant distress or impairs functioning

How is it diagnosed?	Persistence of the preoccupation >6 months despite medical evaluation and reassurance
What is the treatment?	Regularly scheduled office visits followed by psychotherapy

CASE 18

A 33-year-old female presents to your office after being evaluated by 3 other primary care physicians and multiple specialists. She has consistently complained about recurring multiple points of pain on her body, nausea, abdominal pain, menstrual irregularities, and anxiety for over 6 years. Prior medical records indicate an extensive and complete workup with no identifiable medical illness.

What's your differential diagnosis?	Somatization disorder, somatoform disorder, conversion disorder, pain disorder, factitious disorder
Which is most likely?	Somatization disorder
Why?	Multiple medical complaints requiring treatment or impairing functioning, starting before 30 years old, and persisting over several years is consistent with the diagnosis.
Name some common medical complaints.	Pain, GI disturbance, menstrual irregularities, sexual symptoms, and pseudoneurologic symptoms
What's the workup?	Symptom-specific diagnostic workup if not already done in past
How is it diagnosed?	A history of pain in 4 sites plus other symptoms in 3 areas: GI (2 symptoms), sexual, and neurological without medical explanation for the symptoms; some symptoms develop before age 30
What is the treatment?	Regular office visits; no laboratory evaluation or procedures without clear indications; psychiatry if patient amenable (usually not)

EATING DISORDERS

CASE 19

A 15-year-old female presents for her yearly physical exam required to play high school sports. Since last year, she has lost 18 lb, appears ill, and complains of fatigue. Physical exam reveals a cachectic appearance with parotid gland swelling, dental erosions, and calluses on the dorsal aspect of her right hand. Her heart, lung, and abdomen exam is normal except for a scaphoid abdomen.

What's your differential diagnosis?	Anorexia nervosa (AN) or bulimia nervosa (BN)
By history, which is more likely?	Anorexia nervosa
Why?	Profound weight loss and cachectic appearance suggest AN.
Name another way AN may present.	Amenorrhea
Name the two types of AN.	Restricting type and binge-eating/purging type
What clues on physical exam suggest the binge-eating/purging type?	Parotid gland swelling, hand calluses, and dental erosions
What physical symptoms may be present in patients with AN?	Constipation, abdominal pain, cold intolerance, lethargy, or excess energy
What physical signs are often present in patients with AN?	Severe cachexia, hypotension, hypothermia, xerosis, lanugo, bradycardia, parotid gland swelling, edema, dental enamel erosion, calluses on dorsum of hand
What labs should be included in the workup?	Comprehensive metabolic panel, serum albumin, and CBC
What laboratory abnormalities may be seen in patients with AN?	Anemia, leukopenia, hypokalemia, hypochloremic metabolic alkalosis, and hypoalbuminemia

What additional test should be considered?	EKG
What are the psychological criteria necessary to diagnose AN?	An extreme fear of gaining weight or of getting fat, and a distortion of perception of one's weight
What medical complications are patients with AN at risk for?	Cardiac arrhythmias, prolonged QT intervals, decreased left ventricular mass, gastric/intestinal dilatation, osteoporosis, sick euthyroid syndrome, cognitive dysfunction
How is AN managed?	Management of medical complications if present, including hospitalization for severe cases; family and behavioral psychotherapy; medicine may be helpful, e.g., chlorpromazine, cyproheptadine, and fluoxetine

CASE 21

A 15-year-old previously healthy female presents to your office after encouragement from her dentist after finding atypical erosions of her teeth enamel that cannot be explained by any dental disease. She's adamant that her dental hygiene is not a problem. The patient is very concerned about this because she prides herself on her appearance, figure, and weight. She wants to know what is causing it and how to reverse it.

What's your differential diagnosis?	AN, BN
What prior physical exam value is most useful in distinguishing these before taking additional history?	Body weight
What body weight trend is characteristic of BN?	Weight maintained, or slight gain (AN typically has weight loss)
Her weight has increased 2 lb over the past 6 months; which diagnosis do you suspect?	BN

What is the classic presentation for BN?	Recurrent binge eating followed by self-induced vomiting to prevent weight gain
What's the name given to this type of BN?	Purging type
What are some other inappropriate nonpurging-type behaviors used to prevent weight gain in BN?	Laxative abuse, fasting, excessive exercise
What physical signs are associated with BN?	Normal weight; with vomiting: erosion of dental enamel, scars/calluses on hand used to induce vomiting, parotid gland enlargement
What lab values may be used to support the diagnosis?	Chem 8 and amylase
What lab abnormalities may be found with BN?	Electrolyte disturbances, metabolic alkalosis and elevated serum amylase with vomiting, metabolic acidosis with laxative abuse
What psychological symptom is necessary to diagnose BN?	One's self-esteem is excessively influenced by one's body shape or weight (she admitted to this on presentation)
What is the first-line therapy used in BN?	Psychotherapy, particularly cognitive-behavioral
What type of medication may be useful?	Antidepressants

COGNITIVE DISORDERS

CASE 22

A 72-year-old male with history of HTN, CAD, and BPH with recurrent UTIs is brought to the ER on Sunday by his daughter for sudden onset of confusion within the last 24 hours. Prior to being unaware of his surroundings and thinking it was 1965, he was performing his usual activities. He only complained to his daughter that he thought his prostate was acting up again and he wanted to go the doctor on Monday morning. He asked his daughter a day earlier for some Tylenol to help ease his pain with urination.

Is this delirium or dementia?

Delirium

Describe the typical presentation of

Delirium

Abrupt onset with fluctuating course with impaired consciousness and decreased attention

Dementia

Insidious onset of impaired short-term memory; alert

What are common causes of delirium?

DELERIUMS: **D**rugs, **E**ndocrine, **L**ow O₂ (cardiac/stroke), **E**lectrolytes, **R**etention of stool or urine, **I**nfection, **U**nder-nutrition/malnourished, **M**etabolic, **S**ubdural hematoma (SDH) (head injury)

What is most likely causing his delirium?

UTI secondary to urinary stasis secondary to BPH

What other factor should be addressed based on his history?

MI (history of CAD)

What tests would be most useful in this patient?

UA, cardiac enzymes (CK-MB, troponin), EKG

What tests are useful when the diagnosis is unclear?

Drugs

Toxicology screen

Endocrine

TSH

Low O₂

Pulse ox, cardiac workup (EKG, cardiac enzymes), CBC (anemia)

Electrolytes

Chem 8, magnesium, phosphorus

Retention

KUB (assess stool), bladder scan or straight catheterization (urinary retention)

Infection

WBC

Undernutrition

Albumin, prealbumin

SDH

CT head

What are the nursing approaches to a delirious patient?

A quiet environment with decreased stimulation, frequent orientation, and reassurance by family and staff, close observation for agitation or impaired judgment, and minimal use of physical restraints

What are the medical approaches to management?

Identification and correction of contributing factors, nutritional support, sedation with high-potency antipsychotics

CASE 23

A 68-year-old alert male with history of hyperlipidemia and type 2 diabetes mellitus presents with his wife with no complaints. His wife, however, says her husband frequently forgets what she has told him, often misplaces things, is easily agitated, gets lost away from home, and has difficulty balancing the checkbook. This has slowly been getting worse over the last year.

What's the most likely diagnosis?

Dementia

How does it present?

Progressive loss of previously acquired cognitive skills and judgment

What's in the differential diagnosis for dementia?

1. Alzheimer disease (AD)
2. Brain cancer
3. Infection [AIDS, neurosyphilis, progressive multifocal leukoencephalopathy (PML)]
4. Metabolic (EtOH, hypothyroidism, B₁₂ and thiamine deficiency)
5. Organ failure (dialysis dementia, Wilson disease)
6. Vascular disorder [chronic SDH]
7. Normal pressure hydrocephalus
8. Adverse drug effects
9. Depression (pseudodementia)

What noncognitive symptom does this patient have that suggests AD?

Agitation

What other noncognitive symptoms may AD patients present with?

Depression, anxiety, hallucinations, delusions, and sleep disturbances

What additional history and physical exam information should be obtained at a minimum?

Review medications he's taking that may cause mental status changes, depression screen, and on physical examination look for signs of metabolic disturbance or focal neurologic deficits

What basic labs should be ordered in the workup to exclude secondary causes of dementia?

CBC, Chem 8, glucose, liver and thyroid function tests, serum vitamin B₁₂

What if syphilis is suspected?

Venereal disease research laboratory (VDRL) and rapid plasma reagin (RPR) tests

When would a lumbar puncture be warranted?

Signs of cancer (weight loss, focal neurologic deficits), infection (fever, chills, nuchal rigidity), or rapid progression of symptoms

What's the best test to rule out hydrocephalus, mass lesions, and SDH?

CT scan or MRI of brain

The above results are normal. What's your presumptive diagnosis?

Alzheimer disease

Is this surprising?

No, it accounts for over 50% of new dementia cases.

What are the risk factors for AD?

Increasing age, family history, female gender, head injury, and lower education level

Which chromosomes have been implicated in cases of familial AD?	Chromosomes 1, 14, 19, and 21
What cognitive test should you order to confirm the diagnosis of dementia?	Mini mental status examination (MMSE)
What does the MMSE test?	Orientation, attention, memory, and language
How is the diagnosis of Alzheimer dementia made?	By brain autopsy showing intracellular neurofibrillary tangles and neurotic (β -amyloid) plaques
What nonpharmacological treatment modalities are useful in AD?	Establishing a daily routine with familiar surroundings and support services for the caregiver, e.g., social services, education, counseling
What drug treatment may improve cognitive symptoms in AD?	Cholinesterase inhibitors, e.g., donepezil

PERSONALITY DISORDERS

CASE 24

A 45-year-old male comes to your office after an extensive medical and psychiatric workup for a long-standing abnormal pattern of behavior that has significantly impaired his ability to function normally in society. His workup to date is negative for any known medical disorder and the psychiatrist has just ruled out any specific psychiatric disease.

What type of disorder does your patient have?	Personality disorder (PD)
Define a PD.	A chronic pattern of behavior that is not due to another medical or psychiatric condition, e.g., a mood disorder that causes mental distress to the patient or impairs his social interactions and/or occupational functioning

Describe the typical presentation for

Paranoid PD	Extensive and excessive suspiciousness and distrust of others
Schizoid PD	Socially isolated and emotionally cold
Schizotypal PD	Odd thinking, eccentric behavior, and social discomfort
Antisocial PD	Frequent disregard for social norms and for interests of others; often lacks remorse
Borderline PD	Unstable with mood swings, rocky relationships, and anger-control and impulse-control problems
Histrionic PD	Excessive attention-seeking and dramatic behavior
Narcissistic PD	Self-centered and insensitive to others
Avoidant PD	Inhibited with low self-esteem and excessive fear of rejection
Dependent PD	Passive and submissive with difficulty making decisions and fear of being left on one's own
Obsessive-compulsive PD	Perfectionist with a preoccupation with order and control

What psychological tests may be helpful in assessing personality?

The Minnesota multiphasic personality inventory (an objective personality test) and the Rorschach test and thematic apperception test (2 personality tests)

Are PDs treated?

Most are not treated because the patient is comfortable with the behaviors and they do not cause the patient significant distress.

When should PDs be treated?

When they cause significant distress to a patient

What treatments are available for PD?

Psychotherapy and medication

What medications may be used in the following situations?

Psychosis and near-delusional thinking

Antipsychotics

Depression/anxiety

Antidepressants

Chapter 13

Ethics, Statistics, and Epidemiology

MEDICAL ETHICS

What is a living will?	A written document that defines provision of comfort care and life-sustaining care, if the patient has an irreversible disease and unable to make decisions for himself
Define durable power-of-attorney for healthcare?	Appoints another person to make medical decisions when patient is unable to make decisions
Define beneficence	Physician's behavior does more harm than good, as understood by the physician
Define respect for autonomy	Physician's behavior does more good than harm, as understood by the patient
Define futility	A situation where treatment is ineffective or futile and fails to improve quality of life

STATISTICS AND EPIDEMIOLOGY

What is a prospective cohort study?	Two groups of patients with exposure to some factor (e.g., aspirin) and patient's without exposure to this factor (controls) are followed to determine if they prospectively develop some specific disorder (e.g., myocardial infarction).
What is a case control study?	Patient's diagnosed with a particular disorder (cases, e.g., lung cancer) and patient's of similar age, gender, etc. but do not have the disorder (controls) are then retrospectively analyzed determine if they were exposed to certain factors (tobacco) or receive some treatment (antibiotics) which may affect the occurrence of the disease being studied (lung cancer)

Define the following terms

Incidence	The number of new cases of disease in a specific time (typically one year)
Prevalence	The total number of cases of disease that exist at a specific time
Sensitivity	Percentage of patients with the disorder to have a positive diagnostic test result
Specificity	Percentage of patients without the disorder who had a negative test result
Positive predictive value (PPV)	Percentage of patients with a positive test result to have the target disorder
Negative predictive value (NPV)	Percentage of patients with a negative test result who do not have the target disorder
Relative risk	Compares disease risk in the exposed population to the disease risk in the unexposed population in prospective studies
Attributable risk	Number of incident cases attributable to one risk factor
Odds Ratio	Compares odds of disease in subjects exposed versus unexposed in retrospective studies (compare to relative risk)
T test	A statistical analysis test used to evaluate continuous data (age)
Chi square analysis	A statistical test used to assess difference in noncontinuous data (male or female)
P value of 0.05	5% likelihood that the demonstrated difference between the treatment and placebo occurred due to chance
95% confidence interval	Describes a range within which the true treatment effect will lie within 95% certainty

Type I (alpha) error Claiming an effect or difference when none exists

Type II (beta) error Test results show no difference when one does exist

		Disease		
		(+)	(-)	
Test	(+)	A	B	Sensitivity = $A/(A+C)$ Specificity = $D/(B+D)$ PPV = $A/(A+B)$ NPV = $D/(C+D)$
Or				Odds Ratio = $(A \times D)/(B \times C)$
Exposure	(-)	C	D	Relative Risk $[A/(A+B)]/[C/(C+D)]$ Attributable Risk $[A/(A+B)] - [C/(C+D)]$

Appendix

Table A-1. Immunizations

	Birth	1 mo	2 mo	1-4 mo	4 mo	6 mo	6-18 mo	12-15 mo	12-18 mo	15-18 mo	4-6 yr	11-12 yr	11-16 yr	6 mo to 18 yr
HBV	X	X				X								
DTP			X	X		X				X	X			
Hib			X	X		X								
Polio (IPV)			X	X					X					
MMR							X				X or	X		
Td													X	
Varicella									X					

Table A-2. Growth and Development Chart

	Sleep Position	Developmental Progress	Motor Skills	Social Skills	Communication Skills	Start Solids	Lead Testing	Temper Tantrums	Cognitive Skills	Language Skills	Toilet Training	Night Terrors
New-born	Supine											
2-4 wk		Raises head slightly, blinks in response to light, focuses and follows with eyes, and responds to sound by quickly turning toward noise										
2 mo		Temporarily holds head erect, briefly holds rattle, tracks and follows objects, looks at faces and responds to sound, coos, and has a social smile										

(continued)

Table A-2. Growth and Development Chart (continued)

Sleep Position	Developmental Progress	Motor Skills	Social Skills	Communication Skills	Start Solids	Lead Testing	Temper Tantrums	Cognitive Skills	Language Skills	Toilet Training	Night Terrors
4 mo		<ul style="list-style-type: none">• Holds head erect• No head lag when pulling to a sitting position• Raises body using arms in prone position• May roll one or both ways• May support weight on legs• Reaches for and grabs objects• Puts hands together	Same as given under Communication Skills	<ul style="list-style-type: none">• Tracks and follows objects visually to 180°• Coos reciprocally• Blows bubbles• Makes “raspberry” sounds• Smiles readily• May laugh or squeal• Differentiates individuals	<ul style="list-style-type: none">• 4–6 mo solids are introduced; start with rice cereal. Foods to avoid till over 1 yr:<ol style="list-style-type: none">1. Honey2. Corn syrup3. Nuts4. Strawberries5. Chocolate6. Egg whites7. Cow’s milk						

6 mo

- Holds head high when prone
- Holds head steady when pulled to a sit
- Rolls over both ways
- Sits with support
- Uses raking grasp to grab objects
- Transfers objects from one hand to the other
- Takes initiative in vocalizing or bubbling at others
- Imitates sounds
- Smiles
- Laughs
- Coos to initiate social contact
- Recognizes parents
- Shows pleasure and excitement with interaction with parents

9 mo

- Sits well
- Crawls or creeps on hands
- May begin cruising furniture
- Begins to use pincer grasp
- Feeds self
- Bangs objects together
- Enjoys games peek-a-boo and pat-a-cake
- May react to unfamiliar adults with fear or anxiety
- Responds to name
- Understands a few words "no" and "bye-bye"
- Imitates vocalizations
- Babbles using several syllables

(continued)

Table A-2. Growth and Development Chart (*continued*)

Sleep Position	Developmental Progress	Motor Skills	Social Skills	Communication Skills	Start Solids	Lead Testing	Temper Tantrums	Cognitive Skills	Language Skills	Toilet Training	Night Terrors
12 mo		<ul style="list-style-type: none">• Sits well• Crawls• Pulls self up and walks• Feeds self with support• Mature pincer grasp	<ul style="list-style-type: none">• Plays game peek-a-boo and pat-a-cake• Waves bye-bye• Looks at books• Points at and names body parts or animals• Follows simple commands• Likes to play with adult-type objects such as phone or brush	<ul style="list-style-type: none">• Uses mama and dada correctly• Has 3-5 additional words		Screening should begin at 1 yr and be repeated again after the 2nd yr					
15 mo		<ul style="list-style-type: none">• Feeds self with fingers or spoon• Scribbles with crayons• Stacks 2 blocks	<ul style="list-style-type: none">• Shows functional understanding of objects (talks on toy phone)• Gives and takes toys• Plays games with parents• Tests parental rules or limits	<ul style="list-style-type: none">• Says 5-15 words• Uses jargon• Communication with gestures• Points to 1-2 body parts on request• Understands simple commands• Listen to stories• Points to designated pictures in a book			<ul style="list-style-type: none">• Occur between 15 and 20 mo• Normal ways for children to express frustration• Occur as they strive to gain independence				

18 mo	<ul style="list-style-type: none"> • Communication pleasure and displeasure • Understands commands • Points to body parts • May put 2 words together • Walks quickly • May run • Walks up stairs with 1 hand held • Walks backward • Eats with spoon and fork • Stacks blocks • Scribbles with crayons 	<ul style="list-style-type: none"> • Knows location of objects that have been hidden • Plays pretend games such as drinking from empty cup • Hugs a doll • Talks on the phone
2 yr	<ul style="list-style-type: none"> • Running • Jumping to place • Walks up and down stairs • Throws a ball overhead • Opens doors • Stacks blocks • Imitates a vertical line • Uses spoon and fork • Imitates adults • Parallel play with other kids • Dresses and brushes teeth with help • Feeds self 	<ul style="list-style-type: none"> • Begins to create a means to accomplish a desired goal, i.e., pulls a chair to a cabinet and retrieves hidden object • Greater than 50-word vocabulary • Speaks several 2-word phrases • Follows single and 2-step commands • Listen to short stories • Uses pronouns

(continued)

Table A-2. Growth and Development Chart (continued)

	Sleep Position	Developmental Progress	Motor Skills	Social Skills	Communication Skills	Start Solids	Lead Testing	Temper Tantrums	Cognitive Skills	Language Skills	Toilet Training	Night Terrors
3 yr		<ul style="list-style-type: none">• Jumps in place• Kicks a ball• Pedals tricycle• Walks up stairs with alternating gait• Scribbles• Copies a circle• Puts on some clothing• Stacks 8 blocks	<ul style="list-style-type: none">• Knows name, age, and sex• Enjoys interactive play• Participates in pretend play• May be oppositional or destructive	<ul style="list-style-type: none">• Speech is at least 75% intelligible• Uses short sentences• Asks questions such as “why” and “what’s that”• Understands preposition and some adjectives						<ul style="list-style-type: none">• Occurs between 18 and 30 mo• By age 3 about 90% are bowel-trained and 85% are dry during day-time with 60–70% dry at night		
4 yr		<ul style="list-style-type: none">• Hops and balances on 1 foot• Draws a circle and a cross• Cuts with scissors• Draws a person with 3–6 body parts	<ul style="list-style-type: none">• Engages in interactive pretend play• May have an imaginary friend• May not differentiate reality from fantasy• Brushes teeth• Able to button and zip• Toilet trained	<ul style="list-style-type: none">• Extensive vocabulary• Speech fully intelligible to strangers• Uses full sentences with at least 6 words• Asks questions such as “why” and “when”• Recognizes some letters in the alphabet	<ul style="list-style-type: none">• When consulting a parent: Child-size potty seat• Modeling by parents and siblings• Cooperation and success should be rewarded with praise• Avoid punishment or shame in dealing with accidents	<ul style="list-style-type: none">• Present in preschool and early school age• Children cry inconsolably and appear terrified, confused, and glassy eyed						

Index

A

AAA. *See* Abdominal aortic aneurysm

ABC. *See* Airway, breathing, circulation

Abdominal aortic aneurysm (AAA), 27, 40, 78

screening for, 27

therapy for, 28

Abdominal CT scanning, 79

Abdominal ultrasound, 41

ABG, 16, 54, 70, 191

ABI, 43, 44

Abortions, 276

ABRS. *See* Acute bacterial rhinosinusitis

Abruptio placenta, 273–274

Acarbose, 151

ACD. *See* Anemia of chronic disease

ACE inhibitor, 4, 8, 11, 26, 140

Acetaminophen, 100, 294

Acetylcholine receptor antibodies, 210

Acid–base status, 131

Acid-fast bacilli (AFB), 48

Acne, 248–249

causes of, 249

treatments for, 249

Acquired aplastic anemia, 185

Acromegaly, 165

ACTH. *See* Adrenocorticotrophic hormone

Actinic keratosis (AK), 250

Actinobacillus, 19

Activated charcoal, 286

Acute aortic dissection, 21, 23

Acute bacterial rhinosinusitis (ABRS), 288

Acute chest syndrome, 189–191

Acute cholangitis, 109–110

Acute cholecystitis, 109

Acute glomerular nephritis, 123

Acute glomerulonephritis, 120

Acute hemorrhage, 39

Acute interstitial nephritis (AIN), 120, 123

Acute leukemia, 187

Acute mitral valve insufficiency, 38

Acute MR, 14

medical treatment of, 15

Acute myelogenous leukemia (AML), 170

Acute myocardial infarction (AMI), 24, 25, 33, 37

Acute noninflammatory diarrhea, 95

Acute otitis media (AOM), 286–287
diagnosis of, 287

Acute pancreatitis, 21, 114–115

Acute pericarditis, 20, 21

Acute renal failure (ARF), 120
causes of, 123

test for, 121–122

treatment of, 123

Acute respiratory distress syndrome (ARDS), 60–61
treatment of, 61

Acute sinusitis, 288–289

Acute ST segment elevation, 26

Acute tubular necrosis (ATN), 120

Acute viral pericarditis, 21

Acyclovir, 255

ADDM. *See* Adjustment disorder with depressed mood

Adenocarcinoma, 76, 81, 117, 269
prostate, 179

Adenoma, 6

Adenomatous polyps, 89

Adenosine, 31

Adenovirus, 287, 292, 300, 301–302

ADH. *See* Antidiuretic hormone

ADHD. *See* Attention-deficit hyperactivity disorder

Adjustment disorder with depressed mood (ADDM), 321

Adrenal tumors, 3

Adrenocortical insufficiency, 161, 162

primary, 161, 162

Adrenocorticotrophic hormone (ACTH), 3, 161, 162

AF. *See* Atrial fibrillation

- AFB. *See* Acid-fast bacilli
 Agoraphobia, 318
 AICD, 13
 AIH. *See* Autoimmune hepatitis
 AIN. *See* acute interstitial nephritis
 Air embolism, 34
 Airway, breathing, circulation (ABC),
 37, 40, 42
 AK. *See* Actinic keratosis
 Albuterol, 37
 Alcoholic cirrhosis, 110
 Alcoholism, 115, 183–184
 Aldolase, 230, 231
 Aldosterone, 5, 6
 Allergens, 50
 Allergy, 253
 Allopurinol, 242
 ALS (Lou Gehrig disease), 202
 ALT, 100
 Alzheimer disease, 203–204
Amanita muscaria, 285
 Amenorrhea, 165, 331
 AMI. *See* Acute myocardial infarction
 Aminoglycosides, 125
 Aminophiline, 37
 AML. *See* Acute myelogenous
 leukemia
 Amoxicillin, 228, 287, 289
 Amphetamines, 285
 Ampicillin, 200
 Amylase, 333
 AN. *See* Anorexia nervosa
 Anaerobic antibiotics, 253
 Anal fissure, 90, 91
 Anaphylactic shock (AS), 36, 39,
 41, 79
 Anaphylaxis, 36
 Anemia, 170, 172. *See also specific*
 types
 Anemia of chronic disease (ACD),
 186, 192, 193
 Angina, 11, 12, 13
 Angiodysplasia, 79
 Angioedema, 36
 Angiography, 44, 79
 Angiotensin receptor antagonists, 5
 Angular stomatitis, 182
 Ankylosing spondylitis, 237–238
 Anorexia nervosa (AN), 331–332
 symptoms of, 331
 Anterior cerebral artery, 219
 Anterior chest pain, 21
 Antiandrogen therapy, 179
 Antibiotics, 19, 42. *See also specific*
 types
 prophylaxis, 11, 12, 20
 Antibiotic therapy, 42
 Anticholinergic syndrome, 285
 Anticoagulants, 217
 Antidepressants, 322, 333
 Antidiuretic hormone (ADH), 127,
 129, 130
 Antihistamines, 285
 Antihypertensives, 4, 5, 6, 23, 220
 α -1-Antitrypsin (AAT) deficiency, 52,
 98, 110
 Anxiety, 16, 316–320
 generalized, 316
 Anxiolytics, 316
 AOM. *See* Acute otitis media
 Aorta, coarctation of, 22
 Aortic coarct, 3, 18
 Aortic dissection, 9, 21, 23, 38
 Aortic regurgitation (AR), 9
 Aortic sclerosis, 11
 Aortic stenosis (AS), 11, 64, 182
 Aortic valve replacement, 11, 12
 Aortoenteric fistula, 78, 79
 Aplastic anemia, 185, 186
 Apnea, 299, 300
 Appendectomy, 14
 AR. *See* Aortic regurgitation
 Arachidonic acid, 37
 ARDS. *See* Acute respiratory distress
 syndrome
 ARF. *See* Acute renal failure
 Arrhythmias, 15, 298
 and conduction disorders, 28–34
 Arterial blood gas, 38
 Arterial BP, 40
 Arteriogram, 2
 Arteriovenous malformations (AVMs),
 78, 79
 Arteritis, 22
 Arthralgias, migratory, 65
 Arthritis, 92
 migratory, 65
 Arthropathies, 241–247
 AS. *See* Anaphylactic shock; Aortic
 stenosis
 Asbestos, 56–57
 Asbestosis, 56–58
 Aseptic meningitis, 200
 Aspirin, 21, 26, 27, 38, 215, 218

- Asthma, 50–51
 treatment, 51
 triggers, 50
 Atherosclerosis, 8, 27, 40, 43
 Atherosclerotic disease, 8, 43
 Atherosclerotic plaque, 24
 ATN. *See* Acute tubular necrosis
 Atrial fibrillation (AF), 14, 28,
 216–218
 Atrial flutter, 30
 Atropine, 285
 Attention-deficit hyperactivity disorder
 (ADHD), 315–316
 treatment for, 315
 Attributable risk, 341
 Auscultation, 13
 Austin Flint murmur, 10
 Autoimmune hepatitis (AIH), 99
 Autonomy, respect for, 340
 AVMs. *See* Arteriovenous
 malformations
 Azathioprine, 99, 210
- B
 B₁₂/folate deficiency, 183–184
 B-Hcg, 93
 Back, disorders, 234–237
 pain, 234–235
 Bacteremia, 18
 Bacterial meningitis, 199–200
 Bactrim, 185, 293
 “Bamboo-spine,” 238
 Barium enema, 284
 Barium esophagram, 81
 Barrett’s esophagus, 81
 Basal cell carcinoma (BCC), 250,
 260–261
 BDD. *See* Body dysmorphic
 disorder
 Becker muscular dystrophy, 212
 Beck’s triad, 35
 Bee stings, 36
 Behavioral therapy, 320
 Beneficence, 340
 Benign prostatic hypertrophy (BPH),
 11, 120, 143, 178
 Benzathine penicillin, 259
 Benzene, 170
 Benzodiazepines, 316, 318, 321
 Bereavement therapy, 322
 Berger disease, 135, 137
- Bibasilar end-inspiratory crackles, 54,
 56
 Bicuspid aortic valve, 9, 18, 22
 Biliary colic, 108, 109
 Bipolar disorder, 320–321
 Bland sediment, 122, 123
 α -Blockers, 5
 β -Blockers, 4, 23, 26, 29
 Blood cultures, 19
 Blood pressure (BP), 1, 41
 control, 5
 medication, 23
 Bloody diarrhea, 93
 Blunt chest trauma, 22
 BN. *See* Bulimia nervosa
 Body dysmorphic disorder (BDD),
 327, 328
 Bone disorders, 234–237
 Bone marrow aspirate, 185, 187
 Bone marrow biopsy, 173
 Bone marrow transplant, 174
 Bone scan, 179
 Bony crepitus, 73
Borrelia burgdorferi, 228
 Botulinum toxin, 211
 Botulism, 210, 211
 Bouchard nodes, 243
 Bowel diseases, 92
 BP. *See* Blood pressure
 BPH. *See* Benign prostatic
 hypertrophy
 Brain abscess, 196–198
 Brain biopsy, 199
 Brain cancer, metastatic, 205–206
 Breast cancer, 272–273
 treatment for, 273
 Broad-spectrum antibiotics, 171
 Bromocriptine, 166
 Bronchial carcinoma, 27
 Bronchitis, chronic, 52
 Bronchoscopy, 48, 55, 62
 Brudzinski sign, 200
 Bulimia nervosa (BN), 331, 332,
 333
- C
 CABGs, 27
 Cachexia, 52
 CAD. *See* Coronary artery disease
 Caffeine, 29, 30, 285
 Calcific valvular disease, 18

- Calcinosis, Raynaud phenomenon,
 - Esophageal dysmotility,
 - Sclerodactyly, Telangiectasias.
 - See CREST syndrome
- Calcium antagonists, 5, 6
- Calcium channel blocker, 23, 29
- Calcium oxalate, 140
- Campylobacter*, 96, 208
- Candida*, 302
- Candida albicans*, 251
- CAP. See Community-acquired pneumonia (CAP)
- Capillary refill, 41
- Captopril, 6
- Captopril renogram, 8
- Carbamazepine, 127, 224, 321
- Carbon dioxide angiography, 9
- Cardiac arrhythmia, 33
- Cardiac death, 13
- Cardiac ECHO, 197
- Cardiac embolism, 217
- Cardiac tamponade, 34, 35
- Cardiobacterium*, 19
- Cardioembolic stroke, 216–218
- Cardiogenic edema, 16, 17
- Cardiogenic shock (CS), 37, 39, 41
- Cardiology, 1
 - arrhythmias and conduction disorders, 28–34
 - chest pain, 17–28
 - congestive heart failure, 9–17
 - hypertension, 1–9
 - miscellaneous disorders, 43–44
 - shock, 34–42
- Cardiomyopathy, 14, 34, 38
- Cardiothoracic ratio, 10
- Cardioversion therapy, 29, 30
- Carotid endarterectomy, 215, 219
- Carotid sinus massage, 31
- Carotid stenosis, 215
- Carotid upstroke, 12
- Caseating granuloma, 49
- Case control study, 340
- Catecholamines, 7, 31
- Cathartics, 212
- Cauda equina, 235
- CBC, 16, 40, 78, 93, 162, 171, 174, 184, 185, 195, 197, 198
- Cefazolin, 253
- Cefotaxime, 200
- Cefpodoxime, 289
- Ceftriaxone, 147, 247
- Cefuroxime axetil, 289
- Cell markers, 174, 175
- Cellulites, 306
- Central DI
 - causes, 129
 - treatment, 130
- Central nervous system
 - degenerative and hereditary diseases of, 202–205
 - infectious diseases of, 196–201
 - vascular diseases of, 214–222
- Centrilobular emphysema, 53
- Cephalosporin, 200
- Cerebellar astrocytoma, 205
- Cerebral arteries, 219–220
- Cerebrovascular accident (CVA), 22, 43, 152
- Cervical cancer, 270–271
- Cesarean section, 274
- Chem, 8, 16, 93, 148, 160, 162, 168, 197, 198, 333, 334, 336
- Chemotherapy, 32, 77
- Chest pain, 15, 17–28
- Chest radiograph, 22
- Chest trauma, 24
- CHF. See Congestive heart failure
- Chi square analysis, 341
- Chicken pox, 294, 306
- Child abuse, 311–312
- Childhood disorders, 315–316
- Chlamydia* species, 45
- Chlorambucil, 140, 181
- Chlorpromazine, 314
- Chlorpropamide, 127
- Cholangiocarcinoma, 114
- Cholecystitis, 21, 109, 114
- Cholestyramine, 113
- Cholinergic syndrome, 285
- Cholinesterase inhibitors, 204, 337
- Chronic bronchitis, 52
- Chronic cholestatic disease, 113
- Chronic hepatitis B, 110
- Chronic lymphocytic leukemia (CLL), 174
 - diagnosis of, 174, 175
- Chronic MR, 14
 - medical treatment of, 15
- Chronic myelogenous leukemia (CML), 172–174
 - treatment of, 173
- Chvostek sign, 160
- Cimetidine, 37

- Ciprofloxacin, 97
 - Circle of Willis, 215
 - Cirrhosis, 98, 127
 - CK, 38
 - CK-MB, 16, 25, 38
 - Claudication, 43
 - CLL. *See* Chronic lymphocytic leukemia
 - Clofibrate, 127
 - Clomipramine, 328
 - Clopidogrel, 215, 218, 219
 - Clostridium difficile*, 96, 97
 - Clozapine, 314
 - CML. *See* Chronic myelogenous leukemia
 - CMP, 40
 - Coags, 197, 198
 - Cocaine, 29, 30, 285
 - Cognitive-behavioral therapy, 318
 - Cognitive disorders, 333–337
 - Colic, 280–281
 - Colitic arthritis, 239–240
 - Colon, 80
 - Colonoscopy, 91, 94, 182
 - Colorectal cancer (CRC), 88–90
 - Community-acquired pneumonia (CAP), 45–47
 - Compulsion, 317
 - Confidence interval, 341
 - Congenital, 14
 - Congenital cardiac disease, 18
 - Congenital ventricular septal defect, 9
 - Congestive heart failure (CHF), 9–17, 60, 120, 127
 - Conn syndrome, 131
 - Contrast aortography, 23
 - Conus medullaris, 235
 - Conversion disorder, 328, 330
 - Copaxone, 207
 - Coronary artery disease (CAD), 4
 - Corrigan's pulse, 10
 - Corticosteroids, 55
 - Cortrosyn, 162
 - Corynebacterium diphtheriae*, 290
 - Costochondral pain, 23
 - Coxsackie, 301
 - Coxsackie B5, 21
 - Coxsackie B6, 21
 - CPK. *See* Creatine phosphokinase
 - CRC. *See* Colorectal cancer
 - Creatine phosphokinase (CPK), 212, 231
 - Creatinine, 7, 8
 - Creatinine urine catecholamines, 7
 - CREST syndrome, 231–232
 - Creutzfeldt–Jakob disease, 203
 - CRF, 124, 125
 - Crohn disease, 92, 93
 - Cryoprecipitates, 195
 - Cryosurgery, 250
 - Cryotherapy, 264
 - CS. *See* Cardiogenic shock
 - CSF, 199, 207
 - CT scan, 6, 23, 27, 76, 179, 203, 219
 - abdominal, 79, 85, 89
 - chest, 85, 210
 - CTH, 196
 - Cushing syndrome, 2, 3, 131, 163–164
 - ACTH-dependent, 164
 - ACTH-independent, 164
 - screening test, 163
 - Cutaneous lesions, 18
 - CVA. *See* Cerebrovascular accident
 - CVP, 40, 41
 - CXR, 1, 10, 12, 15, 16, 22, 23, 27, 35, 36, 38, 42, 46, 48, 53, 55, 56, 73, 74, 78, 171, 191, 196, 269
 - Cyclic antidepressants, 285
 - Cyclophosphamide, 140, 181
 - Cystine, 140
 - Cytokine release, 61
 - Cytologic and chromosomal analysis, 173
 - Cytomegalovirus, 96
 - Cytotoxic therapy, 55
 - Cytotoxin, 127
- D
- Danazol, 268
 - D&C. *See* Dilation and curettage
 - Debridement, 237
 - Deep venous thrombosis, 68
 - Deferoxamine, 102
 - Degenerative joint disease (DJD), 242
 - Dehydration, 292
 - Delirium, 334
 - diagnosis of, 334
 - Dementia, 334, 335–337
 - Demyelinating disease, 206–209
 - Depression, 14, 320, 321, 322
 - postpartum, 326, 327
 - Dermatitis, 253–254
 - causes of, 254

- Dermatomyositis, 213–214, 229, 230
 Desamino-8-D-arginine vasopressin (DDAVP, Desmopressin), 167
 Desmopressin (DDAVP), 195
 Dexamethasone, 3, 164
 Dexfenfluramine, 9
 DI. *See* Diabetes insipidus
 Diabetes, 4, 23, 43, 47
 Diabetes insipidus (DI), 166–167
 nephrogenic, 167
 neurogenic, 167
 Diabetes mellitus (DM), 8, 24, 148–154
 diagnosis of, 150
 insulin-dependent, 148
 type I, 151
 type II, 150
 Diabetic ketoacidosis (DKA), 151
 triggers to, 152
 Diarrhea, 95–97, 292
 Dibenzylamine, 7
 Diffuse fibrosis, 232
 Digoxin, 29
 Dilated pupils, 211
 Dilation and curettage (D&C), 279
 Diltiazem, 23, 31
 Dilutional hyponatremia, 127
 Diphenhydramine, 37, 294
 Diphtheria, 302
 Diverticulosis, 2, 90
 DJD. *See* Degenerative joint disease
 DKA. *See* Diabetic ketoacidosis
 DM. *See* Diabetes mellitus
 Dobutamine, 17, 39
 DOE, triad of, 13
 Donepezil, 337
 Dopamine, 7, 37, 39, 313
 receptor antagonists, 314
 Doppler echo, 2
 Double bubble sign, 308
 Down syndrome, 170, 308–309
 Doxorubicin, 181
 Doxycycline, 147, 289
 Dual-energy x-ray absorptiometry (DXA), 169
 Duchenne muscular dystrophy, 212
 Duodenal atresia, 308
 Durable power-of-attorney for healthcare, 340
 Dysfunctional uterine bleeding, 271–272
 Dysmenorrheal, 226
 Dysphagia, 8, 42
 Dyspnea, 9, 10, 12, 14, 15, 16, 26
 Dysrhythmias, 38
 Dysrhythmic disorder, 322–323

 E
 Eating disorders, 331–333
 EBV, 301, 302
 Echo, 12
 ECHO test, 19
 Echocardiogram, 10, 11, 12, 13, 15, 19
 Echovirus, 21
 Ectopic ACTH stimulation, 3
 Ectopic pregnancy, 274–275
 diagnosis of, 275
 Edema, 306
 Edrophonium test, 210
 EEG, 203
 Ehlers-Danlos syndrome, 22
Eikenella, 19
 EKG, 1, 10, 12, 14, 16, 25, 29, 31, 33, 35, 38, 42
 rib notching on, 2
 EKG, 78, 130, 298
 Electric cardioversion, 30, 34
 Electrocardiogram, 20, 40
 Electrolytes, 125–134
 Electrophysiologic tests, 207
 Embolism, 43
 EMG, 210
 Emphysema, 52–53
 centrilobular, 53
 panacinar, 53
 Endocarditis, 11, 12, 14
 Endocrine disorders, 148–169
 Endometrial biopsy, 272
 Endometrial cancer, 268–269
 risk factors of, 268
 Endometriosis, 267
 End-tidal carbon dioxide, 40
Entamoeba histolytica, 96
 Enterococci, 19, 110
 Enteroviral pharyngitis, 303
 Enterovirus, 292
 Enuresis, primary, 298
 ELISA. *See* Enzyme-linked immunosorbent assay
 Enzyme-linked immunosorbent assay (ELISA), 227–228, 295, 296
 EPI, 37

- Epiglottitis, 305–306
 causes of, 306
 Epinephrine, 7, 33
 Episodic disorders, 223–225
 Epstein-Barr virus (EBV), 290
 ERCP, 107, 113, 114
 Erythema nodosum, 92
 Erythrocyte sedimentation rate, 21
 Erythromycin, 291
Escherichia coli, 110, 143
 Esophageal cancer, 80
 Esophageal ulcers, 82, 86
 Esophageal varices
 causes, 83
 Esophagitis, 86, 114
 Estrogen, 268
 ETEC, 95
 Ethanol, 29, 30
 Ethosuximide, 224
 EtOH, 97, 223
 Euvoemia, 125
 Exertional dyspnea, 11
 Exudative effusions, 64
 Exudative pharyngitis, 290–291
- F
- Factitious disorder, 329, 330
 Factor VIII, 194, 195
 Factor IX, 194
 Factor-specific assay, 194
 Fanconi's anemia, 185
 Fat, 186
 Fecal leukocytes, 96
 Felty syndrome, 245
 FENa. *See* Fractional excretion of sodium
 Fenfluramine, 9
 Ferritin, 186
 Fetal chromosomal abnormalities, 278
 Fever, 18
 Fibrinolytic agent, 26
 Fibroids, 266–267
 diagnosis of, 266
 treatment, 267
 Fibromyalgia, 226
 Flail chest, 73–74
 Flank pain, 140–143
 Fluid, 125–134
 Flu-like illness, 259
 Fluoxetine, 319, 328
- Folate deficiency, 183–184
 Follicle-stimulating hormone (FSH), 310
 Folliculitis, 248
 Fosphenytoin, 225
 Fractional excretion of sodium (FENa), 122
 Frontal sinus, 288
 FSH. *See* Follicle-stimulating hormone
 Fungus, 19, 302
 Futility, 340
- G
- GABHS. *See* Group A β -hemolytic streptococcus
 Galactorrhea, 165
 Gallstone disease, 107, 108, 115
 Ganciclovir, 97
 Gastric cancer, 79, 84–85
 Gastric lavage, 286
 Gastritis, 114
 Gastroenterology, 78
 pediatric, 280–286
 Gastroesophageal reflux disease (GERD), 81, 82
 diagnosis of, 208–209
 medical management, 83
 Gastrointestinal tract, 40
 GBS. *See* Guillain-Barré syndrome (GBS)
 Generalized anxiety disorder, 316
 GERD. *See* Gastroesophageal reflux disease
 GFR. *See* Glomerular filtration rate
Giardia sp., 95
 Glioblastoma multiforme, 205
 Glomerular diseases, 134–140
 Glomerular filtration rate (GFR), 125
 Glomerular nephritis (GN), 136
 Glossitis, 182
 Glucagons, 37
 Glucocorticoids, 94, 240
 Glucose challenge test, 165
 Glycosylated hemoglobin A1C, 149
 GN. *See* Glomerular nephritis
 Gonorrhea, 247
 Goodpasture syndrome, 135, 137
 Gottrohn sign, 213
 Gout, 2, 241–242, 243, 246
 Gram-negative bacteria, 42
 Gram-positive bacteria, 42

- Granular casts, 122
- Granulomas, 229
 - noncaseating, 66
- Granulomatous arteritis, 9
- Graves disease, 157
- Group A β -hemolytic streptococcus (GABHS), 136, 290, 302
- Growth hormone (GH), 165
- Guillain-Barré syndrome (GBS), 201, 208–209

- H
- HACEK group, 19
- Haemophilus influenza*, 199, 287
- Hairy cell leukemia, 174
- Haloperidol, 314
- Harsh systolic ejection murmur, 13
- HBIG. *See* Hepatitis B immunoglobulin
- HCC. *See* Hepatocellular carcinoma
- HCM. *See* Hypertrophic cardiomyopathy
- Head and neck infections, pediatrics, 286–291
- Heart attack, 15
- Heart block, 38
- Heart failure, 4, 11, 22
- Heart murmur, 18
- Heart palpitations, 9
- Heart rate, 41
- Heberdon nodes, 243
- Helical CT, 9
- Hemiparesis, 217
- Hemiplegia, 217
- Hemocult of stool, 78
- Hemochromatosis, 101, 110
- Hemoglobin, 185, 189, 191
- Hemolysis, 190
- Hemophilia, 193–194
- Hemophilus*, 19
- Haemophilus influenzae*, 45, 46, 289
- Hemoptysis, 61–62
- Hemorrhagic gastritis (HG), 86
- Hemorrhagic shock, 39, 41
- Hemorrhoids, 90, 91
- Hemothorax, 74
- Henoch-Schönlein purpura (HSP), 135
- Hepatic inflammation, 97–106
- Hepatitis, 49
 - A, 102
 - B, 103
 - C, 2, 104
- Hepatitis B immunoglobulin (HBIG), 103
- Hepatocellular carcinoma (HCC), 110–111
- Hepatometomegaly, 171
- Herpes simplex virus, 198–199, 301
- Herpes zoster, 254–255
- HG. *See* Hemorrhagic gastritis
- High-dose dexamethasone test, 164
- HIV, 301
- Hodgkin disease, 176
- Howell-Jolly bodies, 190
- HSP. *See* Henoch-Schönlein purpura
- HTN. *See* Hypertension
- Human papilloma virus (HPV), 264, 271
- Hydralazine, 11, 21
- Hydrochlorothiazide, 4
- Hydrocortisone, 156, 162
- Hydroxychloroquine, 234
- Hyperactive behavior, 315
- Hyperaldosteronism, 3, 5, 6
- Hypercalcemia, 159
- Hypercapnia, 17
- Hypercapnic respiratory failure, 60
- Hypercholesterolemia, 24
- Hyperglycemia, 3
- Hyperkalemia, 132, 133
 - causes, 133
 - mechanism, 133
- Hyperkalemia, 161
- Hyperlipidemia, 47, 11, 23
- Hypermnatremia
 - causes, 128
 - symptoms, 128
- Hyperparathyroidism, 140, 169
- Hyperpigmentation, 161
- Hyperplasia, 5
- Hypersensitivity pneumonitis, 59
- Hypertension (HTN), 1–9, 11, 277
 - asymptomatic, 1
 - uncontrolled, 21, 22
- Hypertensive crisis, 15
- Hypertensive retinopathy, 4
- Hyperthyroidism, 29, 30, 157, 169
- Hypertrophic cardiomyopathy (HCM), 11, 13
- Hypertrophied pylorus, 281
- Hypertrophy, 281
- Hyperuricemia, 241

- Hypervolemia, 125, 126
 - Hypocalcemia, 32, 160
 - Hypocapnia, 70
 - Hypochondriasis, 329
 - Hypoglycemia, 161
 - symptoms and signs of, 154
 - treatment, 155
 - Hypogonadism, 101
 - Hypokalemia, 3, 5, 130
 - treatment, 131
 - Hyponatremia, 168
 - classifications, 125
 - Hypoparathyroidism, 160
 - Hypotension, 28, 34, 35, 39, 325
 - Hypothalamic-pituitary-gonadal axis, 272
 - Hypothyroid, 309
 - Hypothyroidism, 155
 - presents of, 155
 - test for, 156
 - Hypotonia, 309
 - Hypovolemia, 125
 - Hypovolemic hyponatremia
 - treatment, 128
 - Hypovolemic shock, 39, 41
 - Hypoxemia, 70
 - Hypoxemic respiratory failure, 59–60
 - Hypoxia, 191
 - Hysterectomy, 271
- I
- Ibuprofen, 20
 - Idiopathic, 56
 - IDUs, 18
 - IE. *See* Infective endocarditis
 - IgA nephropathy, 135, 137
 - ILD, 54–55
 - Ileostomy, 94
 - Imiprimine, 319
 - Immunotherapy, 77
 - Impulsive behavior, 315
 - Inattentive behavior, 315
 - Incidence, 341
 - Incontinence, 234
 - Infectious diseases, 45–49
 - pediatrics, 291–306
 - Infective endocarditis (IE), 17, 19
 - pathogenesis of, 18
 - Infliximab, 94
 - Influenza viruses, 45, 287, 301, 306
 - Inguinal hernia, 118
 - Inner ear infection, 286–287
 - Inotropic agents, 17
 - INR. *See* International normalized ratio
 - Insulin receptors, 148
 - Insulin-dependent diabetes mellitus, 148
 - Insulinoma, 154, 155
 - β -Interferon, 207
 - International normalized ratio (INR), 78, 198
 - Interstitial edema, 15
 - Intra-aortic balloon pump, 39
 - Intracranial hemorrhage, 220–221
 - Intramuscular vitamin B₁₂, 184
 - Intrapericardial fluid, 35
 - Intrauterine device (IUD), 275
 - Intussusception, 282–284
 - diagnosis of, 283
 - Ipecac, 286
 - IPF, 54–55
 - Iron deficiency, 181, 186, 188
 - Iron-deficient anemia, 182, 189
 - Ischemia, 25, 29, 30, 34
 - Ischemia infarction, 14
 - Ischemic bowel disease, 94
 - Ischemic hepatitis, 105
 - Islet cell antibodies, 148
 - Isocarboxazid, 325
 - Isoniazid, 49, 100
 - Isoproterenol, 32
 - Isotonic IV fluids, 37
 - IV nitroprusside, 23
 - IVDA, 18
- J
- Janeway's lesions, 18
 - Jimsonweed, 285
 - Jugular venous distention (JVD), 34, 35
 - Juvenile onset diabetes, 148
 - JVD. *See* Jugular venous distention
- K
- Kawasaki disease, 304
 - Kayser-Fleischer rings, 105
 - Keloid, 264–265
 - Keratinocytes, 256, 257, 263
 - atypical, 250
 - Kerley B lines, 15, 16

- Kernig sign, 200
 Ketoconazole, 100, 252
Kingella, 19
Klebsiella, 110, 141
 Koilonychias, 182
 Koplik spots, 295
 K-sparing diuretics, 132, 133
- L**
- Lactate dehydrogenase (LDH), 63, 171
 Lacunar stroke, 218–219
 Lambert–Eaton syndrome, 210
 Laparoscopic excision, 268
 Laparoscopic salpingectomy, 275
 Large cell carcinoma, 76
 LDH. *See* Lactate dehydrogenase
 Left atrial enlargement, 14
 Left ventricular failure, 15
Legionella pneumophila, 45, 46
 Leukemia, 172
 chronic lymphocytic, 174–175
 Leukocyte alkaline phosphatase, 173
 Leukocytosis, 46, 197, 198, 304
 Leukopenia, 170
 Leukotrienes, 37
 Levodopa, 205
 Lewy bodies, 205
 Lewy body dementia, 203
 Lidocaine, 33, 34
 Lindane, 258
 Lithium, 321
 Living will, 340
 Longstanding reflux disease, 81
 Lorazepam, 225
 Lou Gehrig disease. *See* ALS
 Lower GI bleeding, 88–95
 Lumbar disk disease, 234–235
 Lumbar puncture, 200, 336
 Lung biopsy, 76
 Lung cancer, 61–62, 66–67
 benign, 67
 malignant, 67
 non–small cell, 77
 small cell, 76–77
 Luteinizing hormone (LH), 310
 LV infarction, 38
 systolic function, 15
 LVH, 12, 14
 Lyme disease, 227–228
 Lymphadenopathy, 171
- Lymphoma, 176–178, 180–181
 stages of, 177
 treatment for, 177
- M**
- Macrolide, 289
 Magnetic resonance angiography, 9
 Major depressive disorder, 323–325
 treatment of, 324
 Malaria, 189
 Malignancy, 27
 Malignant melanoma, 261–262
 Mallory–Weiss tears, 83, 88
 Mammograms, 273
 Manic episode, 320
 MAOIs. *See* Monoamine oxidase inhibitors
 MAP. *See* Mean arterial pressure
 Marfan's syndrome, 22, 23, 27
 Massive PE, 38
 MCV, 192
 Mean arterial pressure (MAP), 38
 Measles, 295, 296–297, 301
 Mechanical ventilation, 17, 74
 Meckel diverticulum, 283
 Melanocytes, 262
 Melanocyte-stimulating hormone (MSH), 161
 Melanoma, malignant, 261–262
 MEN. *See* Multiple endocrine neoplasia
 Meningitis, 196
 aseptic, 200
 bacterial, 199–200
 Menstrual disorders, 271–272
 Meperidine, 125
 6-Mercaptopurine, 100
 Mesalamine, 93
 Metabolic acidosis, 151
¹²³I-metaiodobenzylguanidine (MIBG) scintigraphy, 7
 Metformin, 151
 Methotrexate, 275
 3-Methoxy-4-hydroxymandelic acid, 7
 Methylphenidate, 285, 315
 Metronidazole, 97
 MI. *See* Myocardial infarction
 MIBG scintigraphy. *See* ¹²³I-metaiodobenzylguanidine scintigraphy
 Microcytic anemia, 181–182
 Middle cerebral artery, 219

- Mild PVD, 43
 Mini mental status examination (MMSE), 337
 Mitral annular calcification, 14
 Mitral regurgitation (MR), 11, 14, 18
 Mitral valve calcifications, 15
 Mitral valve prolapse, 14, 18, 318
 MMR vaccination, 297
 MMSE. *See* Mini mental status examination
 Monoamine oxidase inhibitors (MAOIs), 324, 325
 Mood disorders, 320–327
Moraxella catarrhalis, 287, 289
 Morphine sulfate, 17
 MR. *See* Mitral regurgitation
 MRI, 6, 7, 23, 179, 203, 205, 207, 219–220
 Multiple endocrine neoplasia (MEN)
 type 2A, 7
 type 2B, 7
 Multiple myeloma, 169
 Multiple sclerosis (MS), 206–207
 course of, 207
 diagnosis of, 207
 presentation of, 207
 Mumps, 295
 Muscarinic receptors, 285
 Muscular dystrophy, 212–213
 Musculoskeletal pain, 21
 Musculoskeletal problems, 226–234
 Myasthenia gravis, 209–211
 Mycobacterium tuberculosis, 48
Mycoplasma pneumonia, 45
 Myocardial contusion, 38
 Myocardial dysfunction, 34
 Myocardial infarction (MI), 4, 13, 14, 15, 22, 26, 27, 29, 30, 31, 34, 152
 Myocardial ischemia, 28
 Myxedema crisis, 156
 Myxomatous degeneration, 9
- N
- Nafcillin, 237
 Nail pitting, 256
 Narcotics, 127
 Nasogastric (NG) lavage, 78
 Negative predictive value (NPV), 341
Neisseria gonorrhoeae, 146, 290
Neisseria meningitidis, 199, 200
 Neoplasms, 205–206
- Nephritic syndrome, 135, 136
 causes, 138
 commons signs, 138
 lab test, 139
 mechanism, 139
 renal biopsy, 139
 results, 139
 symptoms, 138
 therapy, 139
 treatment, 137
 Nephrogenic diabetes insipidus (DI)
 causes, 129
 treatment, 130
 Nephrolithiasis, 140
 Nephrology, 120
 pediatric, 306–307
 Nephrotic syndrome, 127
 Neurofibromatosis, 7
 Neuromuscular junction and muscle,
 diseases of, 209–214
 NHL, 180
 Nicotine, 285
 Nicotinic receptors, 285
 Nifedipine, 11
 Nitrofurantoin, 100
 Nitroglycerin, 17
 Nitroprusside, 17
 Nonbloody diarrhea, 93
 Noncardiogenic edema, 17
 Noncaseating granulomas, 66
 Noninflammatory diarrhea, 95
 Nonketotic hyperosmolar coma, 153
 Nonsteroidal anti-inflammatory drug (NSAID), 21, 24, 27, 125, 134, 234, 238, 239, 240, 242, 245
 Noonan syndrome, 22
 Norepinephrine, 7, 324
 Normocytic anemia
 normochromic, 192
 Normovolemic hyponatremia, 127
 Norwalk virus, 95, 292
 NPV. *See* Negative predictive value
 NSAID. *See* Nonsteroidal anti-inflammatory drug
 NSAID-induced nephrotoxicity, 120
 Nut consumption, 36
 Nystatin cream, 252
- O
- OA. *See* Osteoarthritis (OA)
 Oat-cell carcinoma, 168

Oat-cell lung cancer, 3, 163
 Obsession, 317
 Obsessive-compulsive disorder, 317
 Obstructive pulmonary diseases, 49–59
 Octreotide, 83
 Odds Ratio, 341
 Onycholysis, 256
 Oral carbohydrates, 155
 Oral doxycycline, 228
 Oral polio vaccination (OPV), 201
 Oral sulfonylurea, 155
 Organophosphates, 285
 Orthopnea, 10
 Osler's nodes, 18
 Osteoarthritis (OA), 241–247
 causes of, 242–243
 Osteomalacia, 169
 Osteomyelitis, 235–237
 Osteoporosis, 168–169
 diagnosis of, 169
 Ovarian cancer, 269–270
 Oxacillin, 253

P

P value, 341
 P waves, 31
 Palivizumab, 301
 Palpation, 13
 Palpitations, 10
 Panacinar emphysema, 53
 Pancreatic cancer, 107, 117
 Pancreatitis, 27, 106–107
 Pancytopenia, 171, 185, 186
 Panic disorder, 318
 Pap smear, 271
 Papillary muscle dysfunction, 14
 Papillary muscle necrosis, 25
 Papilledema, 222
 Paraganglioma tumor, 7
 Parainfluenza, 300, 301
 Paramyxovirus, 295
 Paraneoplastic syndrome, 77
 Parathyroid adenoma, 159
 Parathyroid gland, disease of, 154–160
 Parathyroid hyperplasia, 159
 Parathyroidectomy, 159
 Parietal pleura, of lungs, 26
 Parkinson disease, 204–205
 Partial thromboplastin time (PTT), 195, 217

Patent ductus arteriosus, 9, 18
 Pauci-immune RPGN, 137
 PBC. *See* Primary biliary cirrhosis
 PCa. *See* Prostate cancer
 PCK, 222
 PCN, 36
 PCR, 199
 PE. *See* Pulmonary embolus
 risk factors for, 68
 symptoms and signs of, 68
 Pediatrics
 gastroenterology, 280–286
 head and neck infections, 286–291
 infectious diseases, 291–306
 nephrology, 306–307
 Pelvic inflammatory disease (PID), 267, 275
 Penicillamine, 209
 Peptic ulcer disease (PUD), 21, 78, 79, 83, 86, 114
 Perforating ulcer, 21
 Pericardial tamponade, 38
 Pericardiocentesis, 36
 Pericarditis, 21, 29, 30
 Peripheral neuropathy, 49
 Peripheral smear, 175, 188
 Periumbilical node, 117
 Permethrin, 258
 Personality disorder, 337–339
 presentation of, 338
 treatment of, 339
 Petechiae, 18
 PFT, 50
 Pharmacotherapy, 324, 325
 Pharyngitis, 36
 causes of, 301–302
 enteroviral, 303
 exudative, 290–291
 GABHS, 303
 viral, 303
 Phencyclidine, 285
 Phenelzine, 319, 325
 Phenothiazines, 127
 Phenoxybenzamine, 7
 Phenytoin, 100, 224
 Pheochromocytoma, 3, 6, 7
 Phlebotomy, 102
 Phosphodiesterase inhibitors, 17
 Physostigmine, 285
 Pick disease, 203
 Pimozide, 328

- “Pistol-shot”, 10
- Pituitary irradiation, 164
- Pituitary tumors, 3
- Placenta previa, 276
- Plasma aldosterone level, 5
- Plasma catecholamines, 7
- Plasma metanephrine, 7
- Platelet transfusion, 171
- Pleural effusion, 62–64
 - exudative, 64
 - transudate, 64
- Pleurisy, 26
- Pleuritis, 21
- PMR. *See* Polymyalgia rheumatica
- Pneumatic otoscopy, 287
- Pneumatosis intestinalis, 94
- Pneumococcal vaccine, 53
- Pneumocystis carinii*, 46
- Pneumonia, 26, 60, 196, 300
- Pneumothorax, 27, 70–73
 - primary spontaneous, 70
 - symptoms and signs of, 70
 - tension, 72–73
 - treatment, 71, 73
- Podagra, 241
- Poisoning, 284–286
- Poliomyelitis, 201
- Polymyalgia rheumatica (PMR), 229–230
- Polymyositis (PM), 213, 229
- Polyuria, 166
- Positive predictive value (PPV), 341
- Positive screening test, 5
- Posterior cerebral artery, 219
- Posterior chest pain, 21
- Postpartum blues, 326
- Postpartum depression, 326, 327
- Poststreptococcal GN (PSGN), 135
- Posttraumatic stress disorders, 319
- Potassium supplementation, 5, 6
- Potassium-sparing diuretics, 6
- PPD. *See* Purified protein derivative
- PPV. *See* Positive predictive value
- Prednisolone, 210
- Prednisone, 99, 181, 214, 230, 254
- Prednisone taper, 66
- Preeclampsia, 277–278
 - diagnosis of, 277
- Pregnancy
 - complicated, 273–278
 - ectopic, 274–275
- Presyncope, 13
- Prevalence, 341
- Primary adrenocortical insufficiency, 161, 162
- Primary biliary cirrhosis (PBC), 112
- Primary hyperparathyroidism, 159
- Primary sclerosing cholangitis (PSC), 113
- Probenecid, 228, 242
- Procainamide, 21, 29, 32, 34, 125
- Proctocolectomy, 94
- Proctosigmoidoscope, 91
- Prodrome, 254
- Progestational agent, 272
- Propionibacterium acnes*, 249
- Propranolol, 320
- Propylthiouracil (PTU), 158
- Prospective cohort study, 340
- Prostacyclins, 37
- Prostaglandins, 37
- Prostate adenocarcinoma, 179
- Prostate cancer (PCa), 178
- Prostate-specific antigen (PSA), 55
- Prosthetic valve endocarditis, 19
- Prosthetic valves, 18
- Proteinuria, 277
- Proteus*, 141
- Prothrombin time (PT), 74, 78, 195, 198, 217
- Pruritus, 113
- PSC. *See* Primary sclerosing cholangitis
- Pseudoephedrine, 285
- Pseudogout, 244
- Pseudohyperkalemia, 132
- Pseudohyponatremia, 125
 - therapy for, 126
- Pseudomonas*, 141
- PSGN. *See* Poststreptococcal GN
- Psoriasis, 39, 256–257
- Psoriatic arthritis, 240
- Psychiatry, 313
- Psychosis, 313–314
- Psychotherapy, 316, 319, 321, 323, 324
- PT. *See* Prothrombin time
- PTT. *See* Partial thromboplastin time
- PTU. *See* Propylthiouracil
- PUD. *See* Peptic ulcer disease
- Puerperal psychosis, 326
- Pulmonary angiography, 69
- Pulmonary congestion, 14

Pulmonary disorders, 168
 infectious diseases, 45–49
 obstructive and restrictive diseases, 49–59
 Pulmonary edema, 15, 64–65
 symptoms, 16
 Pulmonary embolectomy, 69
 Pulmonary embolus (PE), 21, 24, 67–69
 Pulmonary infarction, 27
 Pulmonary regurgitation, 9
 Pulse, 40
 Pulse oximeter, 40
 Pulse pressure, 10, 40
 Pulsus paradoxus, 35
 Purified protein derivative (PPD), 48
 Pyelonephritis, 9, 142, 143, 145
 Pyloric stenosis, 281
 Pylorotomy, 282
 Pyrazinamide, 49
 Pyridostigmine, 210
 Pyridoxine, 49

Q

Q wave, 25
 Quincke's pulse, 10
 Quinidine, 29, 32

R

Radioactive iodine (RAI), 158
 Radiocontrast, 125
 Radiotherapy, 77
 RAI. *See* Radioactive iodine
 Rales, 16
 Ranson's criteria, 116
 Rapidly progressive glomerular nephritis (RPGN), 123
 Raynaud phenomenon, 231–232
 RBC casts, 122, 136
 RDW. *See* Red cell distribution width
 Red cell distribution width (RDW), 186
 Reed–Sternberg cells, 176, 177
 Refractory HTN, 8
 Reiter syndrome, 238–239
 Relative risk, 341
 Renal angiography, 8
 Renal angioplasty, 9
 Renal artery duplex scan, 8

Renal artery imaging tests, 9
 Renal disease, end-stage, 47
 Renal failure, 120–125
 Renal parenchymal HTN, 3, 8
 Renal ultrasound, 143
 Renovascular disease, 3
 Renovascular HTN, 8
 treatment, 9
 Reproductive tract, 40
 Respiratory rate, 40
 Respiratory syncytial virus (RSV), 287, 301
 Restlessness, 16
 Restrictive pulmonary diseases, 49–59
 Retinal lesions, 18
 Retinopathy, 138
 Reye syndrome, 306–307
 Rheumatic heart disease, 12, 14
 Rheumatic valvular disease, 18
 Rheumatoid arthritis (RA), 244–246
 causes of, 245
 Rhinovirus, 287, 301
 Rhonchi, 16
 Rib bones, 24
 Rib cartilage, 24
 Rifampin, 49
 Right lower lobe (RLL), 46
 Riluzole, 202
 Ringed sideroblasts, 187
 Ring-enhancing lesion, 197
 Ringer's lactate, 40
 Risperidone, 314
 Ritalin, 315–316
 RLL. *See* Right lower lobe
 RLQ, 93
 Rotavirus, 95, 292
 Rotazyme assay, 293
 Roth's spots, 18
 RPGN. *See* Rapidly progressive glomerular nephritis
 RSV. *See* Respiratory syncytial virus
 RSV bronchiolitis, 299–301
 Rubella, 296–297, 301
 Rubeola, 295, 296
 Ruptured Berry aneurysm, 222

S

SAH. *See* Subarachnoid hemorrhage
 Salicylate poisoning, 151
 Salicylic acid, 264

- Salmonella*, 96, 191, 239
 Sarcoidosis, 65–66
 diagnosis of, 66
 symptoms of, 66
 treatment of, 66
 SBP. *See* Systolic blood pressure
 Scabies, 257–258
 Schilling test, 184
 Schizophrenia, 313–314
 symptoms of, 314
 types of, 313–314
 Scleroderma, 41
 Scopolamine, 285
 Seizures, 223–225
 absence, 224
 tonic-clonic, 224
 Selective serotonin reuptake inhibitors (SSRIs), 127, 317, 318, 320, 324, 325, 327
 Sensitivity, 341
 Sentinel headache, 222
 Septic arthritis, 246–247
 Septic shock, 39, 41
 Serotonin, 324
 Serum bicarbonate/lactate, 38
 Serum iron, 186
 Severe PVD, 43
 Sexual abuse, 311–312
 Shaken baby syndrome, 311
 Shellfish, 36
Shigella, 96, 239, 293
 Shingles. *See* Herpes zoster
 Shock, 28, 34–42
 Short of breath (SOB), 14
 SIADH. *See* Syndrome of inappropriate antidiuretic hormone secretion
 Sick cell disease, 189–191
 Sideroblastic anemia, 186, 187, 188
 SIGMECAPS, 323, 326
 Sigmoidoscopy, 94
 Silica, 56
 Silicosis, 57–58
 Sinusitis, acute, 288–289
 Sjögren Syndrome, 245
 Skin eruptions, 248–265
 SLE, 233–234
 SLUDGE (Salivation, Lacrimation, Urination, Defecation, GI cramps, and Emesis), 285
 Smoking. *See* Lung cancer
 SOB. *See* Short of breath
 Social phobia, 319
 Solu-Medrol, 37
 Somatization disorder, 330
 Somatoform disorders, 327–330
 Specificity, 341
 Spine, disorders of, 234–237
 Spironolactone, 6
 Splenectomy, 199
 Splenomegaly, 18, 171
 Splinter hemorrhages, 18
 Spondyloarthropathies, seronegative, 237–240
 Spontaneous abortion (SAB), 278–279
 Spoon nails. *See* Koilonychia
 Squamous cell carcinoma (SCC), 76, 80, 250, 262–263, 271
 diagnosis of, 263
 risk factors for, 263
 Squat-to-stand maneuver, 13
 SSRIs. *See* Selective serotonin reuptake inhibitors
 S-T segment elevation, 25
Staphylococcus, 292
Staphylococcus aureus, 19, 95, 237, 248, 253, 289
Staphylococcus epidermidis, 19
 STAT Accu-Chek, 152
 Stat labs, 40, 42
 Steroids, 240
 Stool culture, 293
 Stool guaiac test, 182
 Streptococcal pharyngitis, 303
 Streptococci, 19
Streptococcus pneumoniae, 45, 46, 199, 187, 289
Streptococcus pyogenes, 290
 Stress, 31
 Strokes, 219–220
 Struvite, 140, 141
 Subarachnoid hemorrhage (SAH), 221–222
 Subtotal thyroidectomy, 158
 Sulfasalazine, 93, 240
 Supine, 40
 Surgical revascularization, 44
 Surgical valve replacement, 12
 Sympatholytic drugs, 5
 Sympatholytic syndrome, 285
 Sympathomimetic syndrome, 285
 Syncope, 11, 12, 22

- Syndrome of inappropriate antidiuretic hormone secretion (SIADH), 127, 167–168
treatment, 128
- Syphilis
diagnosis of, 259
primary, 258–260
secondary, 259
tertiary, 260
- Systemic steroids, 254
- Systolic blood pressure (SBP), 43
- T**
- T test, 341
- T waves, 31
inversion, 12
- TA. *See* Temporal arteritis, 228–230
- Tachycardia, 6, 31, 39
- Tachypnea, 16, 39
- TAHBSO. *See* Total abdominal hysterectomy and bilateral salpingo-oophorectomy
- Takayasu's arteritis, 9
- TB. *See* Tuberculosis
- TCAs. *See* Tricyclic antidepressants
- TdP. *See* Torsades de pointes
- Temporal arteritis (TA), 228–230
- Tensilon test, 210
- Tension pneumothorax, 34, 72–73
- Tertiary syphilis, 9
- Tetracycline, 147
- Thalassemia, 186, 188
- β -Thalassemia, 188–189
- Theophylline, 29, 30, 285
- Thiazide, 6
- Third-generation cephalosporin, 200
- Thoracic aortic aneurysm, 24
- Thoracotomy, 36
- Throat culture, 303
- Thrombocytopenia, 170, 195
- Thrombolysis, 69
- Thrombolytic agent, 26
- Thrombosis, 43
- Thromboxane, 37
- Thymectomy, 211
- Thymoma, 209, 210
- Thyroid, disease of, 154–160
- Thyroid-stimulating hormone (TSH), 156, 181
- Thyroid storm, 158
- Thyrototoxicosis, 7
- Thyroxine, 156
- TIBC, 186
- Ticlopidine, 218
- TIPS. *See* Transjugular intrahepatic portosystemic shunt
- TMP-SMZ. *See* Trimethoprim-sulfamethoxazole
- Tobacco, 52. *See also* Lung cancer
- Togavirus, 297
- Torsades de pointes (TdP), 32
- Total abdominal hysterectomy and bilateral salpingo-oophorectomy (TAHBSO), 268, 269
- Transbronchial biopsy, 76
- Transesophageal echocardiogram, 19, 23
- Transient bacteremia, 18
- Transient ischemic attack (TIA) stroke, 215
- Transjugular intrahepatic portosystemic shunt (TIPS), 83
- Transluminal coronary angioplasty, 26
- Transsphenoid microadenectomy, 3
- Transrectal ultrasound, 144
- Transsphenoidal microadenectomy, 164
- Transthoracic echo, 38
- Transthoracic echocardiogram (TTE), 19, 35, 36
- Transtubular K gradient (TTKG), 134
- Transudative effusions, 64
- Tranlycypromine, 325
- Traube's sign, 10
- Trauma, 27, 40, 43
- Treponema pallidum*, 259
- Tricyclic antidepressants (TCAs), 317, 318, 319, 324, 325, 327
- Tricyclics, 127
- Trimethoprim-sulfamethoxazole (TMP-SMZ), 287, 289
- Troponin, 16, 25, 38
- Trousseau sign, 160
- TSH. *See* Thyroid-stimulating hormone
- TTE. *See* Transthoracic echocardiogram
- TTKG. *See* Transtubular K gradient
- Tuberculosis, 47–49, 58
- Tubular cells, 122
- Tubular hyperkalemia, 134
- Tularemia, 302

Turner syndrome (TS), 1, 22, 310–311
 diagnosis of, 310
 disorders associated with, 311
 Tylenol, 287
 Type I (alpha) error, 342
 Type II (beta) error, 342
 Type IV RTA, 134
 Tzanck smear, 255, 294

U

Ulcerative colitis, 89, 92, 93, 94, 113
 Ulcers, 252–253
 Ultrasound, 27, 44
 UNa. *See* Urine Na
 Unilateral oophorectomy, 270
 Upper endoscopy, 79, 87
 Upper GI bleeding, 78–88
 Uremia, 125
 Urethritis, 146, 147
 Uric acid, 140
 Urinalysis, 121
 Urinary metanephrines, 7
 Urinary tract infections (UTIs), 9
 Urine Na (UNa), 121, 122
 Urine osmolality, 129
 Urine output, 41
 Urosepsis, 142
 Ursodeoxycholic acid, 112
 Uterus, 266–269
 UTIs. *See* Urinary tract infections
 Uveitis, 92

V

Vagal maneuvers, 31
 Vaginitis, 144
 Valproic acid, 100, 224, 321
 Valsalva maneuver, 13, 31
 Valve replacement, 20
 Valvular heart disease, 15
 Vancomycin-resistant streptococci (VRS), 289
 Varicella, 306
 Varicella-zoster virus, 294

Vascular dementia, 203
 Vascular diseases, CNS, 214–222
 Vascular injury, 61
 Vascular surgery, 41
 Vasculitis, 27
 Vasodilating drugs, 5, 232
 Vasodilator therapy, 11
 Ventricular fibrillation, 33
 Ventricular septal defect, 11, 18
 Ventricular septal wall rupture, 38
 Ventricular tachycardia, 33
 Verapamil, 23, 31
 Verruca vulgaris. *See* Viral warts
 Vertebral fracture, 27
 Vertebral fractures, 234–235
 Vertebrobasilar artery, 219
Vibrio cholerae, 95
 Vincristine, 127, 181
 Viral encephalitis, 198–199
 Viral pharyngitis, 303
 Viral warts, 263–264
 Von Hippel–Lindau, 7
 von Willebrand disease (vWD), 195
 VRS. *See* Vancomycin-resistant streptococci
 vWD. *See* von Willebrand disease

W

Waldenström macroglobulinemia, 174
 Water-deprivation test, 167
 “Water-hammer pulse,” 10
 WBC casts, 122
 Wegener granulomatosis, 135, 137
 Western blot, 227–228
 Wheezing, 16
 Wilson disease, 105–106

Y

Yersinia, 239

Z

Zithromax, 147

